



Morphometry of Proximal Femur in North Indian Population and Its Clinical Correlation

Authors

**Dr Pooja Dawani (MD, Anatomy)¹, Dr Jasbir Kaur (MD, DNB, MNAMS Anatomy)²,
Dr Davinder Singh (MS, DNB, MNAMS Orthopaedics)³,
Dr Vandana Mehta (MS Anatomy)⁴**

¹Senior Resident, Department of Anatomy, VMMC and Safdarjung Hospital

²Associate Professor, Department of Anatomy, VMMC and Safdarjung Hospital

³Professor, Department of Orthopaedics, VMMC and Safdarjung Hospital

⁴Director Professor and Head, Department of Anatomy, VMMC and Safdarjung Hospital

*Corresponding Author

Dr Jasbir Kaur (MD, DNB, MNAMS Anatomy)

Abstract

Introduction: The proximal end of femur consists of head, neck, greater and lesser trochanters. Various pathologies of hip require surgical intervention either in the form of replacement or open reduction and internal fixation. The morphometric analysis of proximal end of femur is of immense importance in designing prosthesis and implants of appropriate size.

Materials and Methods: The present study was conducted in the department of Anatomy, VMMC, New Delhi on 76 dry adult fully ossified human femur bones. The parameters measured included femur length (FL), femur neck length (FNL), femur head diameter (FHD), femur neck diameter (FND), femur neck thickness (FNT) and cervicodiaphyseal angle (CDA). The mean and standard deviation of parameters were calculated. Unpaired t-test was used to assess statistically significant side dimorphism.

Results: The mean values of FL, FNL, FHD, FND, FNT and CDA were 41.626 ± 2.170 cm, 40.835 ± 3.023 mm, 39.531 ± 2.966 mm, 40.973 ± 6.647 mm, 23.972 ± 2.488 and 135.592 ± 5.734 degrees respectively. Cervicodiaphyseal angle displayed statistically significant side dimorphism (0.0013), the measure being higher on right side as compared to left side.

Discussion: The present study provides values specific to Indian population that will help in designing of appropriate size prosthesis and implants needed for various orthopaedic procedures. Mismatched prosthesis results in complications including pain, osteolysis and aseptic loosening. Femur neck length and diameter also helps in choosing the appropriate length and number of cancellous screws used for fixation of neck fractures.

Introduction

The femoral head forms two thirds of a sphere and articulates with the acetabulum of hip bone to form the multiaxial, ball and socket hip joint. The neck bridging the head and shaft is directed downwards, backwards and laterally. The neck

shaft angle is 127 degrees. The neck is also laterally rotated with respect to shaft making an angle of ante version of about 10-15 degrees. The trochanters, situated at the junction of neck and shaft are connected anteriorly by intertrochantric line and posteriorly by intertrochanteric crest.^[1,2]

Various common pathologies of hip including hip osteoarthritis, a vascular necrosis of head of femur and fracture neck of femur disturbs the normal anatomy of proximal femur and needs surgical intervention in the form of either replacement of head or open reduction and internal fixation using various types of implants. The morphometric analysis of proximal end of femur is of immense importance in designing prosthesis and implants of appropriate size. Mismatched prosthesis size and inappropriate placement of prosthesis might result in loosening of prosthesis and unbalanced weight transmission thus deteriorating the postoperative outcome.^[3]

Present study was conducted to study the morphometric characteristics of proximal femur in dry adult femur bones and further assess if there is statistically significant side dimorphism for the parameters studied. The aim of the present study is to improvise upon the existing lacunae related to proximal femur morphometry in Indian population.

Materials and Methods

The present study was conducted on 76 dry adult fully ossified human femur bones. The bones with deformities, fractures and missing parts were excluded from the study. The measurements were taken using digital vernier calipers, measuring tape and goniometer. The parameters included **femur length, femur neck length, femur head diameter, femur neck diameter, femur neck thickness and cervicodiaphyseal angle**. The measurements were made as;

Femur length (FL)- The bone was placed on a flat surface. Femur length was measured from the highest point of femur head to the lowest point of medial condyle with the help of a measuring tape^[4] (Figure 1)

Femur neck length (FNL)- Femur neck length was measured as the distance between the inferior region of base of femur head and the lower end of intertrochanteric line with the help of a measuring tape.^[4] (Figure 2)

Femur head diameter (FHD)- It was measured as the distance between the upper and lower ends of femoral head in the craniocaudal axis.^[4] (Figure 3)

Femur neck diameter (FND) - It was measured as the distance from the upper end to the lower end of the anatomical neck of femur in craniocaudal direction.^[4] (Figure 4)

Femur neck thickness (FNT)- It was the thickness of the femur neck in the anteroposterior axis. It was measured at the level of a line joining midpoint between upper region of femoral head and base of greater trochanter and midpoint of femur neck length.^[4] (Figure 5)

Femur head diameter, Femur neck diameter and Femur neck thickness were measured with the help of digital calipers.

Cervicodiaphyseal angle (CDA)- The angle between the line joining the centre of head of femur and the midpoint of intertrochanteric line (femur neck axis) and vertical line from the tip of greater trochanter (femur shaft axis)^[4] (Figure 6)

The right sided parameters were compared with the left side. Unpaired t- test was applied to find whether the side dimorphism was statistically significant or not. The p value <0.05 was taken as statistically significant.

Results

In the present study, the mean femur length was recorded as 41.626 ± 2.170 cm (41.252 ± 2.115 cm on right side and 42.088 ± 2.178 cm on left side). Mean femur head diameter was observed to be 40.835 ± 3.023 mm (40.390 ± 3.213 mm on right side and 41.383 ± 2.717 mm on left side). Mean femur neck diameter was recorded as 39.531 ± 2.966 mm (39.032 ± 3.091 mm on right side and 40.147 ± 2.723 mm on left side). Mean femur neck length was 40.973 ± 6.647 mm (40.476 ± 5.756 mm on right side and 41.588 ± 7.651 mm on left side). Mean femur neck thickness was observed as 23.972 ± 2.488 mm (23.747 ± 2.904 mm on right side and 24.265 ± 1.852 mm on left side). The mean cervicodiaphyseal angle was recorded as 135.592

± 5.734 degrees (137.524± 4.753 degree on right side and 133.236± 5.758 degree on left side).The cervicodiaphyseal angle displayed statistically significant side dimorphism(p=0.0013),the

measure being higher on right side (137.524 ± 4.753 degree) as compared to left side (133.236± 5.758 degree). The other parameters did not show any significant side dimorphism (Table1).

Table 1 Morphometric parameters of right and left sided femurs

Parameters	Side	Min.	Max.	Mean	Standard deviation	p value
Mean femur length	Right	36.5 cm	44.8 cm	41.252cm	2.115	0.09
	Left	39.5 cm	44.2 cm	42.088 cm	2.178	
Mean femur head diameter	Right	35.06 mm	44.02 mm	40.390mm	3.213	0.14
	Left	37.33 mm	44.75 mm	41.383mm	2.717	
Mean femur neck diameter	Right	33.93 mm	45.16 mm	39.032mm	3.091	0.13
	Left	35.23mm	44.56mm	40.147mm	2.723	
Mean femur neck length	Right	28mm	46mm	40.476mm	5.756	0.54
	Left	23mm	50mm	41.588mm	7.651	
Mean femur neck thickness	Right	21.34mm	29.09mm	23.747mm	2.904	0.41
	Left	21.02mm	27.24mm	24.265mm	1.852	
Cervicodiaphyseal angle	Right	130 degree	140 degree	137.524 degree	4.753	0.0013
	Left	137 degree	144 degree	133.236 degree	5.758	



Figure 1: Femur length measured from highest point of femur head to the lowest point of medial condyle.

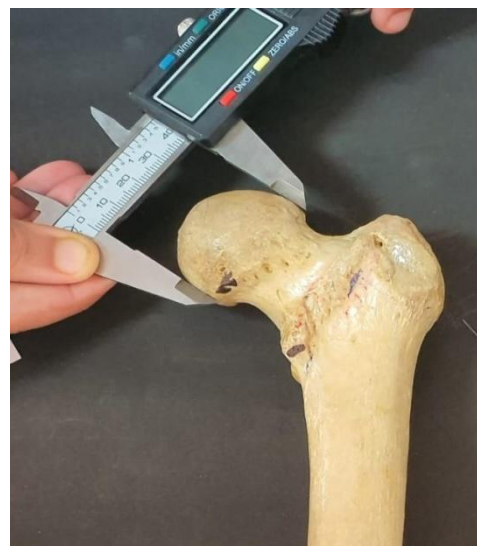

Figure 3: Femur head diameter measured as the distance between the upper and lower ends of femur head in craniocaudal axis.

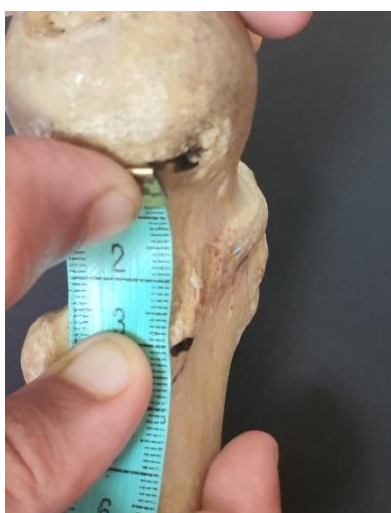

Figure 2: Femur neck length measured as the distance between the inferior margin of base of femur head and the lower end of intertrochanteric line.

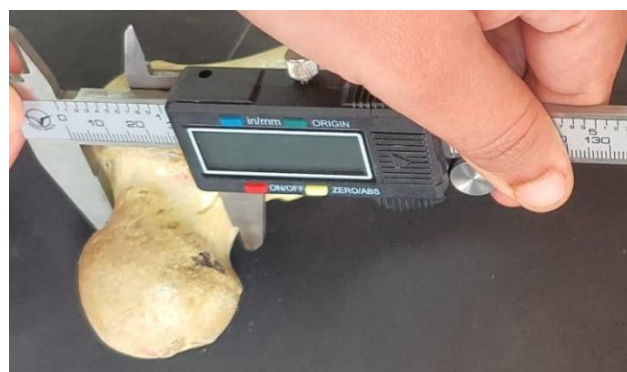

Figure 4: Femur neck diameter measured as the distance from the upper end to the lower end of the anatomical neck of femur in craniocaudal direction



Figure 5: Femur neck thickness measured in anteroposterior axis at the level of a line joining midpoint between upper region of femoral head and base of greater trochanter and midpoint of femur neck length.

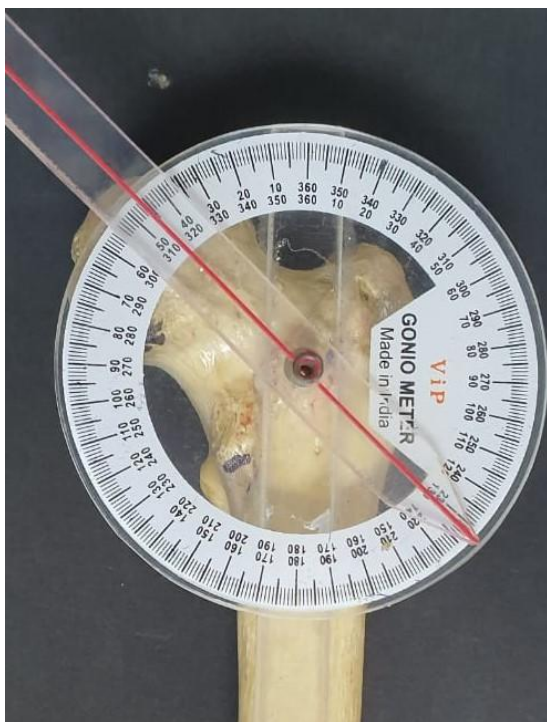


Figure 6: Cervicodiaphyseal angle measured between the line joining the center of head of femur and the midpoint of intertrochanteric line (femur neck axis) and vertical line from the tip of greater trochanter (femur shaft axis).

Discussion

Every year more than eighty thousand hip replacements are being done worldwide.^[5]As

there are considerable racial and ethnic differences in the morphometric parameters of proximal femur, the size of prosthesis used for hip surgeries should be designed in accordance with specific population. Oversized prosthesis can result in fracture of femur, and if small in size might not be compatible with the bone.^[6]The hip prosthesis, used commercially are designed according to European population^[7] The implants designed for western population are large in size and they mismatch the morphometric parameters of Indian population.^[8] Mismatch between prosthesis and femoral bone results in pain, osteolysis and aseptic loosening.^[9]

In the present study, **mean femur length** was recorded as 41.626 ± 2.170 cm. **Mean femur head diameter** was, 40.835 ± 3.023 mm. In previous studies also similar results were recorded for MFHD, 42.32 ± 4.11 mm on Indian population^[4], 45.4 mm on Chinese population^[10], 40.81 ± 3.43 mm In Malay population^[11], 45.50 ± 3.39 mm in Korean population^[12], 43.18 ± 3.47 mm in Thai population^[13]. However the results (52.09 ± 4.43 mm) were different for American and Caucasian populations^[14].

Mean femur neck diameter was observed to be 39.531 ± 2.966 mm in the present study, 33.02 ± 4.22 in Indian population^[4], 31.91 mm in Chinese population^[10]. **Mean femur neck length** was 40.973 ± 6.647 mm (present study), 44.71 ± 8 mm in Indian population^[4] and 46.22 ± 5.14 mm in Thai population^[13].

Mean femur neck thickness was noted to be 23.972 ± 2.488 mm in the present study and 24.01 ± 3.0 in Indian population.^[4]

Cervicodiaphyseal angle was noted to be 135.592 ± 5.734 mm degree (present study), 128.90 ± 4.49 in Indian population^[4], 132.69 ± 5.91 in American and Caucasian population^[14], 129.88 mm in Chinese population^[10], 130.46 ± 4.02 in Malay population^[11], 130.27 ± 5.39 mm in Korean population^[12] and 128.04 ± 6.14 mm in Thai population.^[13]

Mean femur neck length was 40.93 mm (present study), 44.71 ± 8 mm in Indian population^[4] and 46.22 ± 5.14 mm in Thai population.^[13]

The previous studies indicate that the mentioned parameters have shown different values in different populations.

As the parameters are showing inter population variability, the prosthesis and implants should be specifically designed according to the population for which they are being used to avoid mismatch and postoperative complications.

These parameters are also of immense importance for various orthopaedic procedures. The **Cervicodiaphyseal Angle (CDA)** is an important parameter for designing orthopaedic implants^[15]. Fracture femur normally requires a dynamic screw with an angle of 135 degree.^[11] If the CDA is large, the screw may slip into the superior quadrant or the fracture may be pulled into valgus position.^[8] In the present study, the angle was found to be 137.764 ± 4.753 degree on right side and 133.235 ± 5.758 degree on left side. The values had shown statistically significant side dimorphism ($p=0.0013$) and a large standard deviation. However in some previous studies no statistically significant side dimorphism was recorded.^[15,16,17] The statistically significant side dimorphism for the angle suggests that the surgeon should be careful in choice and fixation of the screw.

Femur neck length helps in choosing the length of cancellous screws for fixation of neck fractures. The screw threads might not cross the site of fracture if the neck length is small and thus adequate compression might not be possible.^[8] Femur neck thickness increases with increase in age in males. This can be a predisposing factor for osteoarthritis as it increases the chances of impingement.^[18]

According to previous studies in Caucasian postmenopausal women, it has been suggested that women with history of hip fracture had a longer femoral neck length. There is 24 % increase in risk of hip fracture with one mm increase in femoral neck thickness.^[19] In another

study on Turkish population, femoral neck angle and width were reported to be significantly higher in patients with hip fracture.^[20] The chances of fracture are increased in cases of longer hip axis, length of femur, larger neck shaft angle and larger femoral neck width.^[21]

Conclusion

The present study documents the values of different morphometric parameters of proximal femur (FL, FNL, FHD, FND, FNT and CDA) specific to Indian population. The values in western population are higher than that of Indian population. Therefore, population specific data is essential for designing of appropriate sized prosthesis and implants, thereby reducing the osteolysis and pain, and improving the postoperative outcome.

References

1. Standring S. Gray's Anatomy: The Anatomical Basis of Clinical Practice. 41stedn. London: Elsevier.2016. Pelvic girdle, gluteal region and thigh. p. 1348-53.
2. Snell RS. Clinical Anatomy by Regions. 9thedn. South Asian edition. Wolter Kluwer. 2012. The Lower Limb.p.439-43.
3. Mc Grory J, Morrey BF, Chahalan TD, Kai- Nan AN, Cabanela ME, Effect of femoral offset on range of motion and abductor muscle strength after total hip arthroplasty J Bone Joint Surg 1995 77(B):865-69.
4. Verma M, Joshi S, Tuli A, Raheja S, Jain P, Srivastava P. Morphometry of Proximal Femur in Indian Population. J ClinDiagn Res. 2017; 11(2): 1-4.
5. Granger C, Schutte HD, Bigger SB, Kennedy JM, Latour RA, Failure analysis of composite femoral component for hip arthroplasty. J Rehab Res Develop 2003;40:131-46.
6. Vaidya SV, Ranawat CS, Aroojis A, Laud NS, Anthropometric measurements to

- design total knee prostheses for the Indian population *J Arthroplasty* 2000;15:79-85.
7. Rubin PJ, Leyvraz PF, Aubaniac JM, Argenson JM, Esteve P, Roguin BD. The morphology of the proximal femur: a three dimensional radiographic analysis *J Bone Joint Surg B* 1992;74(1):28-32.
 8. Siwach RC, Dahiya S. Anthropometric study of proximal femur geometry and its clinical application. *Indian Journal of Orthopaedics* 2003;37(4):247-51.
 9. Reddy VS, Moorthy GV, Reddy SG. Do we need a special design of femoral component of total hip prosthesis in our patients? *Ind J Orthop* 1999;33:282-84.
 10. Lin KJ, Wei HW, Lin KP, Tsai CL, Lee PY. Proximal femoral morphology and the relevance to design of anatomically precontoured plates: A study of the Chinese population. *The Scientific World Journal*. 2014;106941.
 11. Baharuddin MY, Zulkifly AH, His M, Aziz AA. Three dimensional morphometry of the femur to design the total hip Arthroplasty for Malay Population *Advanced Science Letters* 2013;19 (10): 2982-87.
 12. Cho HJ, Kwak DS, Kim IB. Morphometric evaluation of Korean Femur by geometric computation: comparisons of the sex and the population *Biomed Research Int* 2015;7: 305 -38.
 13. Mahaisavariya B, Sitthiseripratip K, Tongdee T, Bohez EL, Vander SJ, Oris P. Morphological study of the proximal femur: A new method of geometrical assessment using three dimensional reverse engineering *Med Engg Phys* 2002;24(9):617-22.
 14. Unnanuntana A, Toogood P, Hart D, Cooperman D, Grant RE. Evaluation of proximal femoral geometry using digital photographs *Journal of Orthopaedic Research* 2010;28:1399-404.
 15. De Sousa E, Fernandes R, Mathias MB, Rodrigues MR, Ambram AJ, Babinski MA. Morphometric study of the proximal femur extremity in Brazilians *Int J Morphol* 2010;28(3):835-840.
 16. Silva, V. J.; Oda, J. Y. & Sant'anna, D. M. G. Anatomical aspects of the proximal femur of adult brazilians *Int J Morphol* 2003;21(4):303-8.
 17. Canto, R. S. T.; Silveira, M. A.; Rosa, A. S.; Gomide, L. C. & Baraúna, M. A. Morfologiaradiográfica de quadril e pelve e sua relação com fraturas proximais do fêmur *Rev. Bras. Ortop* 2003;38(1/2):12-20.
 18. Johnson JK, Renner JB, Dahners LE. Anteroposterior thickening of the femoral neck with aging decreases the offset in men *Am J Sports Med* 2012;40(10):2213-17.
 19. El Kaissai S, Pasco JA, Henry MJ, Panahi S, Nicholson JG, Nicholson GC, et al. Femoral neck geometry and hip fracture risk: the Geelong osteoporosis study *Osteoporosis Int* 2005;16:1299-1303.
 20. Calis HT, Eryavuz M, Calis M. Comparison of femoral geometry among cases with and without hip fractures *Yonsei Med J* 2004;45:901-07.
 21. Bhattacharya S, Chakraborty P, Mukherjee A. Correlation between neck shaft angle of femur with age and anthropometry: A Radiographic study *Indian Journal of basic and applied Medical Research* 2014;3(3):100-07.