



Original Research

Direct Posterior Composite Restotation Using Microbrush Stamp Technique

Authors

Dr Smita¹, Dr Nutan Mala^{2*}, Dr C.K. Wang³, Dr Abhinav Kumar Singh⁴

^{1,2}PG student, Department of Cons and Endo, B.I.D.S.H

³HOD, Conservative Dentistry and Endodontics B.I.D.S.H. Patna, Bihar

⁴Professor, Conservative Dentistry and Endodontics B.I.D.S.H. Patna, Bihar

*Corresponding Author

Dr Nutan Mala

Introduction

The new millennium has shown an exponential progression in dentistry. From extractions to functional restorations, to finally, the era of 'bio-mimetic dentistry'. 'Bio-mimetic' literally translates to mimicking nature.

However, manually crafting an esthetic direct composite restoration is a technique that requires experience and skill or finesse. One of the newer evolved techniques for achieving an amalgamation of both esthetics and function is the 'Stamp technique'.¹

The restoration aims primarily at restoring the form, function and occlusal topography of a single tooth mutilated by the disease.² The numerous matrices are available in market which allow making proper contact and contour of proximal surfaces but do not result in precise occlusal topography.³

Occlusal carving is left to the free hand with expertise and the flexibility that can contribute to over/under reclaimed surfaces.⁴ The process of microbrush stamp technique is one of the new developments in restorative dentistry for posterior

teeth utilizing composite material for precise occlusal topography.⁵

Stamp is like an index, which is the mini impression made by putty, flowable composite or liquid dam before tooth preparation.^{4,5}

This matrix is then pressed against the final composite increment before curing takes place.⁶

The procedure of stamping includes reproducing the initial morphology of the tooth structure by emulating the original unprepared tooth structure.⁷

This is advised that the exact indication of this procedure be restricted to pits, cavities, fissures and cracks where the tooth has preserved anatomical features.⁷

The method is used where the occlusal surface is almost unaltered before the restorative operation.⁸

In instances with mild to moderate carious lesions, the decayed layer is covered by wax and the occlusal surface is engraved on the wax.

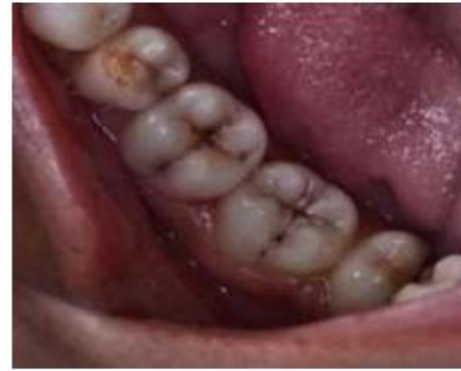This article discusses application of stamp technique using six different cases where conventional as well as modified methods have been used.

Case Report

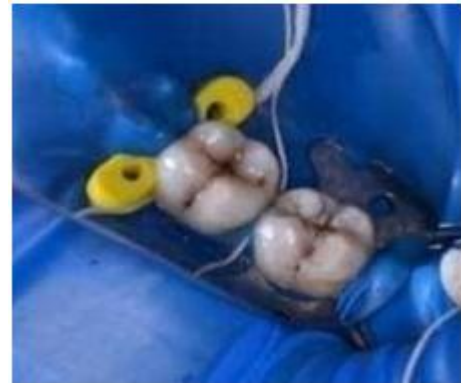The cavitated tooth to be restored was isolated under rubber dam. In the given cases, no separating medium has been used on tooth surface before fabrication of stamp.

However, if the tooth presents with very deep pits and fissures, separating media is recommended. In such cases, the separating media fills the pits and fissures and does not allow subsequent flowable composite to flux inside. This leads to a more continuous surface of the final restoration. The tip of a microbrush was trimmed with the scissors for ease of handling. Flowable composite material was applied to the occlusal surface, and the microbrush was placed over it with a gentle digital pressure. It was light cured and thus occlusal stamp was fabricated. Caries was excavated and cavity preparation done using Airotor handpiece using tungsten carbide bur. Selective enamel etching was done with 37% phosphoric acid [TetricN Etch Ivoclarvivadent] and rinsed with water using disposable needle and syringe. The cavity was dried with chip blower to obtain frosty white appearance in enamel, while the dentin was blot dried. Bonding agent [Tetric N Bond, Ivoclarvivadent] was applied with an applicator tip and cured for 20 seconds followed by the incremental addition of packable resin composite resin [B2 shade Tetric N ceram, Ivoclarvivadent]. The restoration was light cured using LED [Blue phase] for 20 seconds.

After final increment was added, a teflon tape was applied onto the surface. The fabricated microbrush stamp was pressed over the teflon sheet. The resin composite was then cured. Artificial stain is applied to give the tooth a natural appearance. Polishing was carried out using soflex spirals and buffs.



Pre – operative photograph, Class I superficial cavitated caries



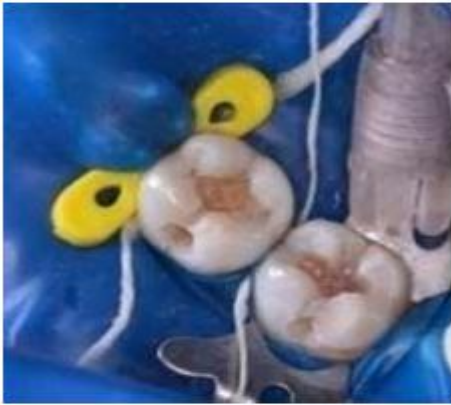Rubber dam isolation



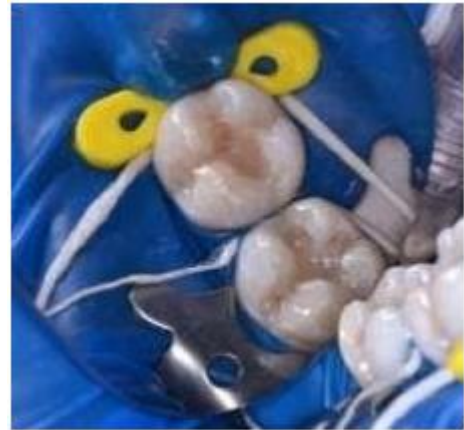The tip of the microbrush is cut for better handling characteristics



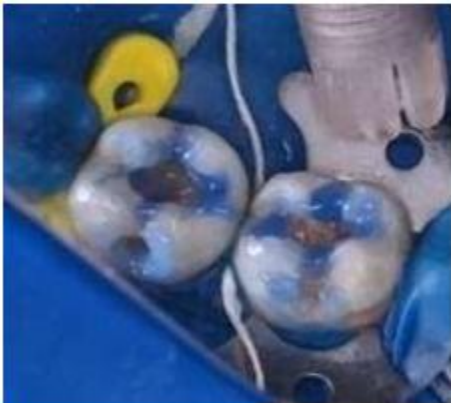Liquid dam placed on the tooth and Micro brush is pressed before curing



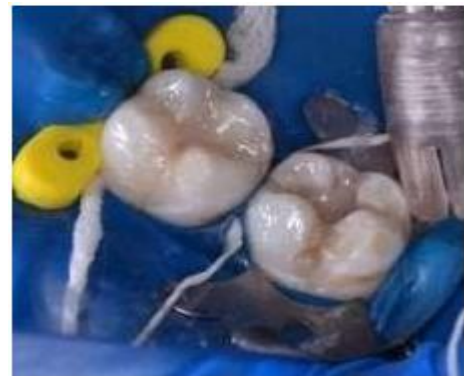Prepared cavity



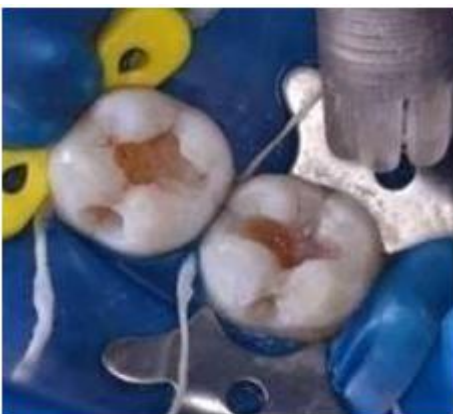Incremental layering of composite 1mm short of occlusal level



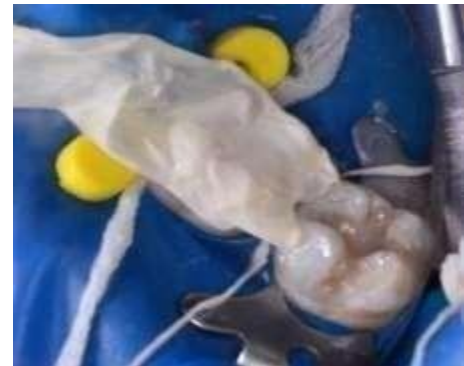Selective enamel etching with 37% ortho phosphoric acid



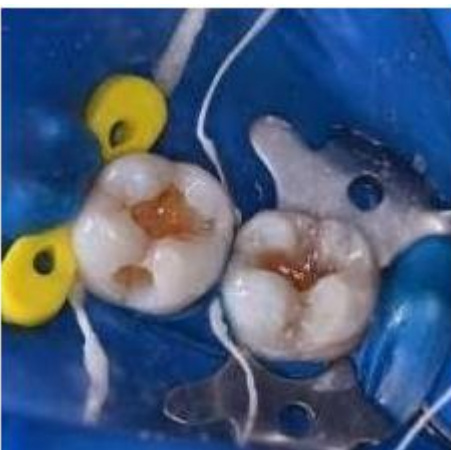Placing final layer of composite



Etched enamel and moist dentin



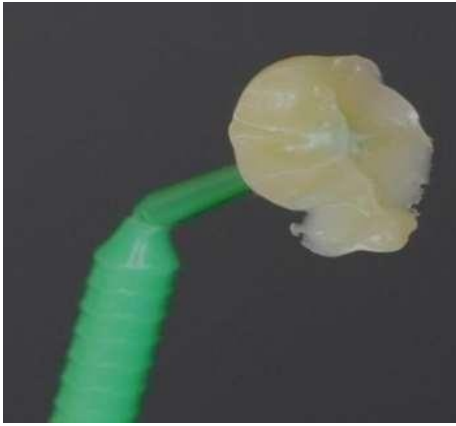
Teflon tape placed covering occlusal surface of tooth



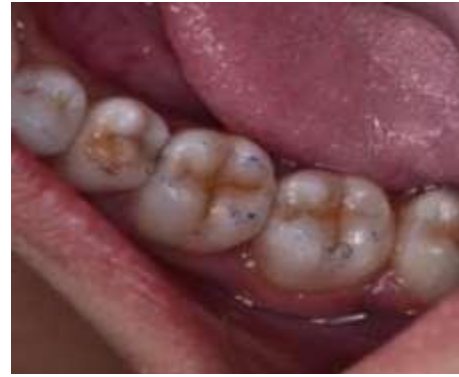Application of 7th generation bonding agent



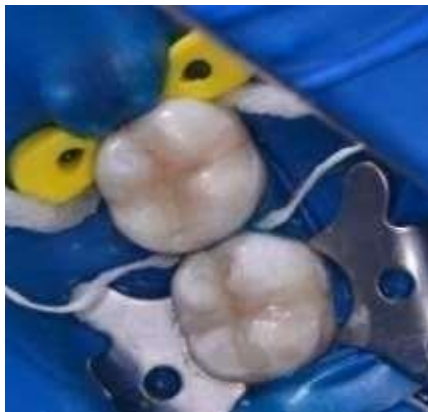Occlusal stamp of first molar



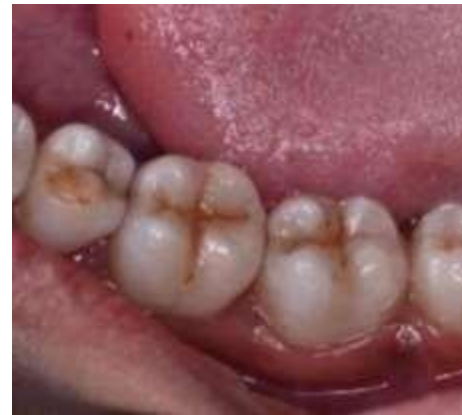Stamp of second molar



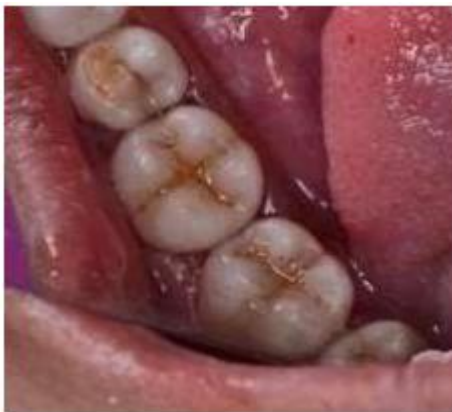Occlusion is checked



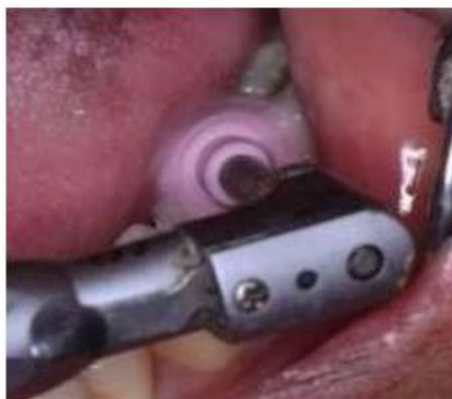After stamping



Final restoration



Application of stain to mimic natural tooth



Polishing of restoration

Discussion

Often the posterior teeth have cavities with preserved enamel surface, but dentin has been undermined. These lesions may be identified as bluish/black discoloration under the enamel surface.⁹ Such cases are ideal for 'stamp technique' restoration. Stamp technique has various advantages. Firstly, it helps in reducing overall time required for the restoration as instantly desired cusp –fossa relationship is attained.^{4,10} This is suitable in a busy practice scenario as it ensures predictability with accuracy. Secondly, degree of voids in final restoration is reduced. It helps in excluding oxygen from the top layer of composite and thus prevents its polymerization inhibiting effect. This ensures long term success of the restoration.¹¹

The potential limitation of this technique is limited number of cases to which it can be applied. However, with modifications in the technique and further research, its scope can be expanded.¹²

Conclusion

The technique of the occlusal stamp is successful for direct restoration of posterior teeth with secret cavities and considerable dentin involvement. Therefore, this approach minimizes operating time by avoiding occlusal modifications upon reconstruction.

References

1. Alexey Murashkin Direct posterior composite restorations using stamp technique-conventional and modified: A case series IJDR 2017; 2(1): 3-7
2. Hamilton JC, Krestik KE, Dennison JB. Evaluation of custom occlusal matrix technique for posterior light-cured composites. *Oper Dent.* 1998;23:303-7.
3. Abdelrahman Tawfik, Style Italiano; Direct Posteriors - Community Stamp Technique,
4. Varsha R K, Microbrush Stamp Technique – Case report, *General Practice Feature*, 98 September 2015 // dentaltown.com, 98-9.
5. Geena MG, Kevin RG. Building Proximal Contacts and Contours in Resin Composite Restorations: A Technical Report. *Journal of Scientific Dentistry* 2014;4(1):62-9.
6. Dawson EP. Evaluation, Diagnosis and treatment of Occlusal problems, 2nd Ed., C.V. Mosby Co.(Toronto): 1989.
7. Volschan B CG, Soares L MB. Cárieoculta: diagnóstico e tratamento. *J Bras Odontopediatria Odontol Bebe.* 2000; 3(15): 399-403.
8. Silva SREP, Imparato JC. Técnica matrizoclusal: uma alternativa para o restabelecimento das estruturas anatômicas. *Bras. Clin. Estet Odontol.* 2000; 4(24):49-52.
9. Pontes MCC, Tollara M, Salim D, Imparato JC. Técnica alternativa para restauração de dentes decíduos posteriores através de matriz oclusal. *J. Bras. Clín. Estética Odontol.* 1999; 3(17):28-32
10. José Guilherme Férrer Pompeu 1, Rhoana

Coelho Morais², Occlusal Stamp Technique For Direct Resin Composite Restoration: A Clinical Case Report. *International Journal of Recent Scientific Research* Vol.7, Issue, 7 pp. 12427 12430, July, 2016

11. Leibenberg WH. “Occlusal index-assisted restitution of aesthetic and functional anatomy in direct tooth-colored restorations”. *Quintessence International* 27 (1996): 81-88.