



Case Report

Angle Closure Glaucoma with Diabetes Mellitus: A Double Edged Sword

Authors

Dr Upali Tiwari, Dr N. Kori, Dr Madhvi Tiwari, Dr Akshay K. Umare

MGM MC & MYH, Indore, MP, India

Clinical History

- A 60 years old female came with complain of Ocular pain, redness & DOV in left eye since 15 days. She was apparently alright 6 years back, when she developed DOV in BE.
- In LE DOV was mildly painful Associated with redness & watering & she had multiple episodes of same complain.
- In RE DOV is sudden in onset painful in nature associated with redness, watering & floaters. She had multiple episodes of same associated with headache & vomiting.
- No history of coloured halos, spectacle use, any neurological deficit.
- Past history: history of RE trabeculectomy 2 years back.
- History of LE cataract surgery & intra vitreal injection 4 months back.
- Medical history: K/C/O DM II & systemic HTN & seizure disorder?
- Family history: not significant

Personal history

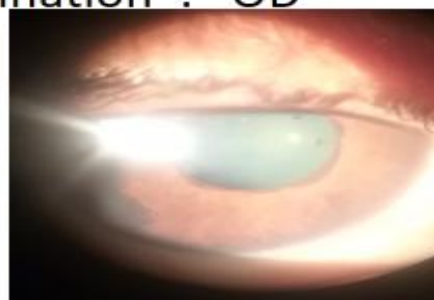- Appetite: decreased
- Bowel/bladder: normal
- Sleep : decreased

Drug History

- Tb. Glimiperide
- Tb. Ramipril
- Tb. Ecosprin
- Tb. Escetalopram
- Locally BE
- E/D Bidin-T
- E/D dorzox

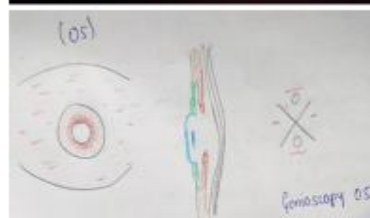Ocular examination : OD

VISION	No PL PR inaccurate
POSITION OF HEAD	Normal
POSITION OF EYE BALL	Central
OCULAR MOVEMENTS	present in all cardinal gazes
LIDS	Normal
LACRIMAL PASSAGE	ROPLAS -ve
CONJUNCTIVA	Congested. Blob present, well formed bleb.
CORNEA	Clear
SCLERA	Normal
ANTERIOR CHAMBER	Shallow VH grade I
IRIS	Colour normal pattern disturbed, posterior synechiae present. Inferotemporal quadrant one hyperpigmented patch present.
PUPIL	PCNRTL
LENS REFLEX	GWR NS II
DIGITAL TENSION	Raised NCT : 24.7mmHg




Ocular examination : OS

VISION	PL + PR ACCURATE
POSITION OF HEAD	Normal
POSITION OF EYE BALL	Central
OCULAR MOVEMENTS	present in all cardinal gazes
LIDS	Mild Swollen
LACRIMAL PASSAGE	ROPLAS -ve
CONJUNCTIVA	Congested
CORNEA	Clear
SCLERA	Normal
ANTERIOR CHAMBER	Shallow VH Grade I
IRIS	Vascularisation present over pupillary margin extending to periphery. Ectropion uvea present.
PUPIL	PCNRTL
LENS REFLEX	Shining reflex
DIGITAL TENSION	Raised, NCT : non recordable




Fundus OD

- Media : vitreoretinal traction bands associated with slight vitreous degeneration.
- Disc : distinct circular
- CDR : 0.9:1
- Blood vessels : Arteries:
Veins: dilated & tortuous
- Foveal reflex : not appreciable
- General fundus: vitreoretinal fibrovascular traction band present in superotemporal & superonasal quadrant.




Fundus OS

- Media : clear
- Disc : distinct circular, neovascularisation present in temporal margin
- CDR : 0.8 : 1.
- Blood vessels : Arteries:
Veins: dilated & tortuous
- Foveal reflex : not appreciable
- General fundus : flame shaped haemorrhages present in all 4 quadrants . Neovascularisation present inferotemporally.



Post op picture

- Iris neovascularisation decreased.
- ocular pain decreased.



Provisional diagnosis

- Right eye proliferative diabetic retinopathy angle closure glaucoma, glaucomatous optic neuropathy with NS grade II cataract
- Left eye proliferative diabetic retinopathy neovascular angle closure glaucoma, glaucomatous optic neuropathy with pseudophakia.

- Serum urea - 32 mg/dl
- Serum creatinine -0.76mg/dl
- Urine R/M- albumin: traces
- sugar : traces

Investigations

- Hb – 12.3 mg/dl
- TLC – 7300/ cumm
- DLC – N-60, L-20, M-04 E-02, B-00
- Platelet – 2.3 lacs/ mm
- FBS –120 mg/dl ,PPBS– 166mg/dl
- HbA1C- 7.23

Treatment given

- Inj. Mannitol 300 cc BD*3days
- Tb. Diamox 250 mg QID
- Syrup potchlor 1tsp TDS
- Locally BE:
- E/D gate-DM QID
- E/D homide TDS
- E/D brimotim BD
- Surgical intervention:
- LE Anterior retinal cryopexy under EGVP under LA