



Case Report

Two cases of Aesthetic Rehabilitation of Teeth with Moderate to Severe Dental Fluorosis

Authors

Dr Ruchi Shah^{1*}, Dr Sumit Patidar², Dr Palak Shah³

¹MDS, Senior Lecturer, K M Shah Dental College and Hospitals, Vadodara, Gujarat

²MDS, Senior Lecturer, Sri Aurobindo College of Dentistry, Indore, Madhya Pradesh

³DNB, MBBS, Consultant Paediatrician, Vadodara, Gujarat, India

*Corresponding Author

Dr Ruchi Shah

Abstract

Dental fluorosis in children causes moderate to severe discoloration on tooth surface. Treatment options for fluorosis vary with severity which renders an unmet need to choose effectively the treatment modality for aesthetic rehabilitation of teeth with dental fluorosis. This case series is based on rehabilitation of teeth with moderate to severe fluorosis. A 30 year old male patient presented with a chief complaint of compromised esthetics due to teeth discoloration whereas a 23 year old male patient presented with complaint of discolored upper anterior teeth. Considering the age of the patient, economic status and severity of fluorosis, full jacket crown was considered the treatment option for 30 year old patient and composite veneering for 23 year old patient.

Introduction

Dental fluorosis is an irreversible condition caused by excessive ingestion of fluoride in majority of children exposed for extensive periods between third month of gestation and 8 years of age. These children eventually develop moderate to severe discoloration on tooth surface.¹ Areas with high fluoride content in excess of two parts per million results in metabolic alteration in ameloblasts in young children causing defective matrix and improper calcification.² Histological examination of the affected teeth clinically present as a hypomineralised, porous subsurface enamel with a well-mineralized surface layer; this type of enamel hypoplasia is known as endemic enamel fluorosis.³ Affected teeth usually present with

glazed surfaces which may be paper white with areas of yellow, brown or even black shading in various parts of the tooth. Stains may range from a simple brown diffuse pigmentation, white flecks or opaque spots visible on enamel surface.⁴ Treatment options for fluorosis varies with severity. Different treatment modalities for enamel fluorosis include, micro/macro abrasion, bleaching, composite restorations, veneers and full crowns.⁵ This case series discusses successful esthetic management of a moderate to severe fluorosed teeth.

Case A

A 30 year old male patient presented with a chief complaint of compromised esthetics due to teeth

discoloration. Patient had discoloration since childhood with no relevant medical history. On clinical examination patient had generalized enamel fluorosis affecting all of his permanent teeth with generalized confluent pitting and brownish discoloration/ stains. He had Angle's Class I relationship. Patient underwent bleaching and veneering in the past with unsuccessful results. He had healthy gingival tissue and good oral hygiene. Radiographic examination revealed no dental caries or alveolar bone loss. Patient had history of chewing tobacco since 7-8 years. On the basis of history, clinical findings and dean's index diagnosis of moderate to severe dental fluorosis was made (Fig A). Considering the age of the patient, economic status and severity of fluorosis, full jacket crown was considered as shape of the tooth also started to get slightly altered and accepted by the patient as treatment option. The initial phase of treatment started with oral prophylaxis, smile analysis, preliminary shade selection, photographs, study models to evaluate the occlusion and diagnostic wax up. Based on the collective decision by physician and the patient; maxillary 14 to 24 and in mandible 35 to 45 were decided to be crowned for esthetics with individual crowns respectively. Pre operative impressions were taken to form the template used as a guide for crown height and occlusion setting. On the next clinical appointment tooth preparation was done from 12 to 22 and desensitization along with temporization was done taking the template as a guide (Fig B). 2 days later 13,14 and 23,34 were prepared and temporization were done. Occlusion was checked and adjusted. Canine guided occlusion was established. In mandibular arch also same procedures were done. Tooth preparation was done from 42 to 32 firstly then in next visit 45,44,43 and 35,34,33 were prepared. The teeth were than subsequently desensitized and temporization was done (Fig C). Physician suggested a darker value shade for the patient according to the gum and skin shade of the patient and gave the temporization with A2 shade and patient was asked to visit after 1 month for final

crown. In the next appointment patient was completely comfortable, he was able to chew his food properly, no TMJ findings were evident and patient was satisfied with the shape and form of the crowns, but patient was willing for even lighter and high value A1 shade from vita shade guide. After 1 month temporary crowns were removed and final impression were recorded following gingival retractions. The correct fits of full crown were verified both individually and collectively on the model and teeth (Fig D). The patient was satisfied with the form, shape, and shade of crowns and final cementation was done. Contact points and occlusion was checked and final finishing and polishing was subsequently done after 24 hours of cementation. Post-operative photographs and instructions were given after the treatment procedure and patient was satisfied with the treatment outcome (Fig E & F).

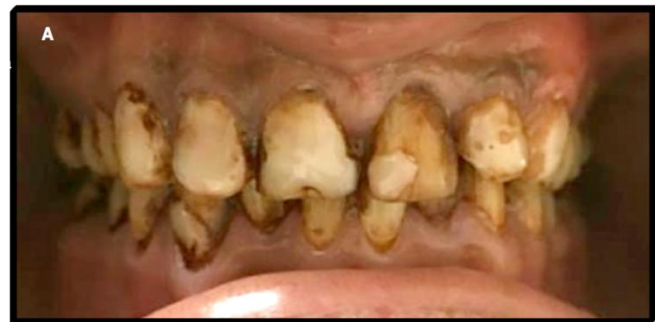

Fig A. Pre operative photograph showing severe discoloration of teeth of Case 1.

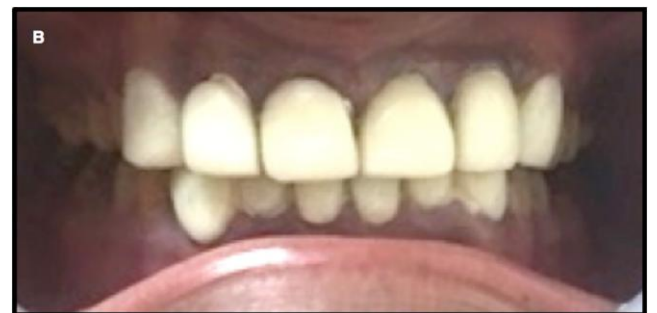

Fig B. Showing the temporization with maxillary laterals and incisors and mandibular anteriors.

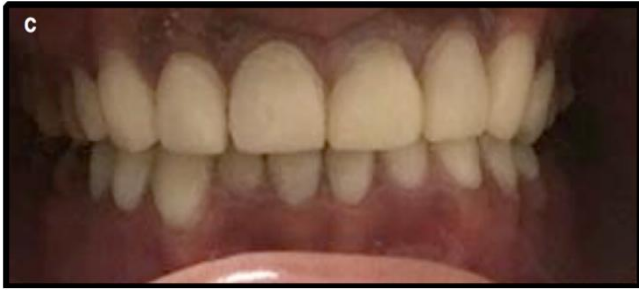

Fig C. Showing the temporization with maxillary right first Premolar to left premolar and mandibular right second premolar to left premolar.

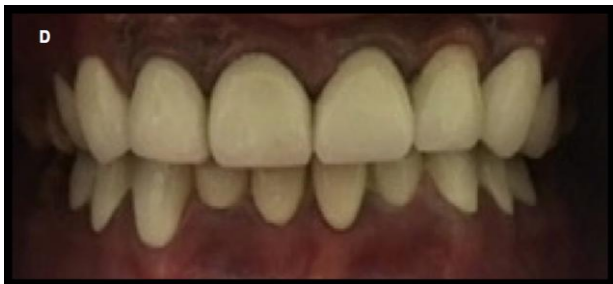

Fig D. Showing final prosthesis with maxillary right first Premolar to left premolar and mandibular right second premolar to left second premolar.

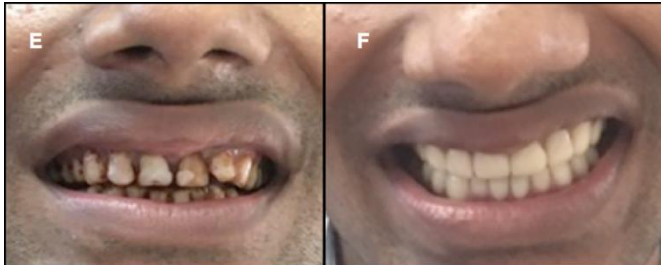

Fig E and F. Showing preoperative and post operative smiles of Case 1.

Case B

A 23 year old male patient presented with complaint of discolored upper front teeth. Patient had history of discoloration since childhood with no relevant history (Fig G). Patient had Class 1 molar relationship with good oral hygiene and healthy gingival tissue. Radiographic examination revealed no dental caries or alveolar bone loss. Based on history, clinical findings and dean’s index diagnosis of mild to moderate fluorosis with 13-23 and mild fluorosis in rest of his teeth was made. On the basis of age of patient, economic

status and severity of fluorosis direct composite veneering was considered and accepted by the patient as the treatment option.

The initial phase of treatment started with oral prophylaxis, smile analysis, preliminary shade selection, photographs, study models to evaluate the occlusion. In next appointment tooth preparation for veneers with 12-22 i.e from maxillary right laterals to left laterals following the rubber dam isolation was done (Fig H). The composite resin used in the present case was nano-composite Metric N Ceram. (Ivoclar) shade A1 with Prime and Bond NT (Dentsply, India) as the bonding agent. Polishing of composite restoration was accomplished with Super Snap (Shofu Inc, Japan). Occlusal corrections were done and incisal guidance was established. After occlusal equilibrium got established Canines were prepared and veneered with same clinical protocols (Fig I). Now canine guided occlusion was established and checked. The final finishing and polishing was done after 24 hours of cementation. Post-operative photographs and instructions were given after the treatment procedure and patient was satisfied with the treatment outcome (Fig J).

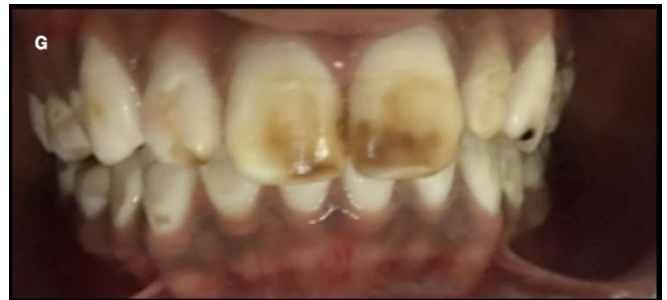

Fig G. Pre operative photograph showing severe discoloration of teeth of Case 2.

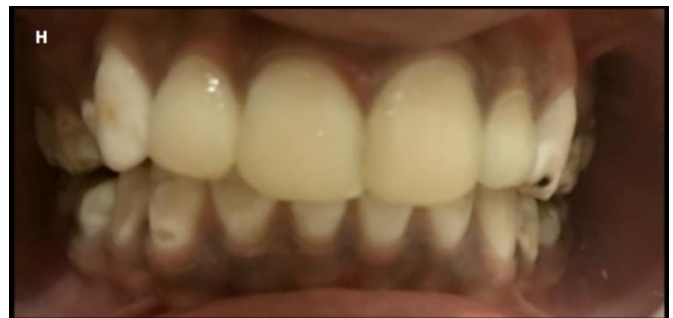

Fig H. Showing the composite veneers with maxillary laterals and incisors.

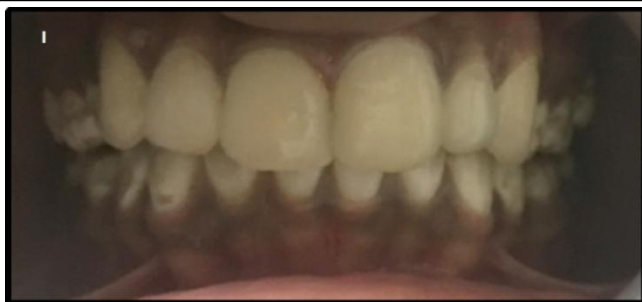

Fig I. Showing the composite veneers with maxillary right canine to left canine.

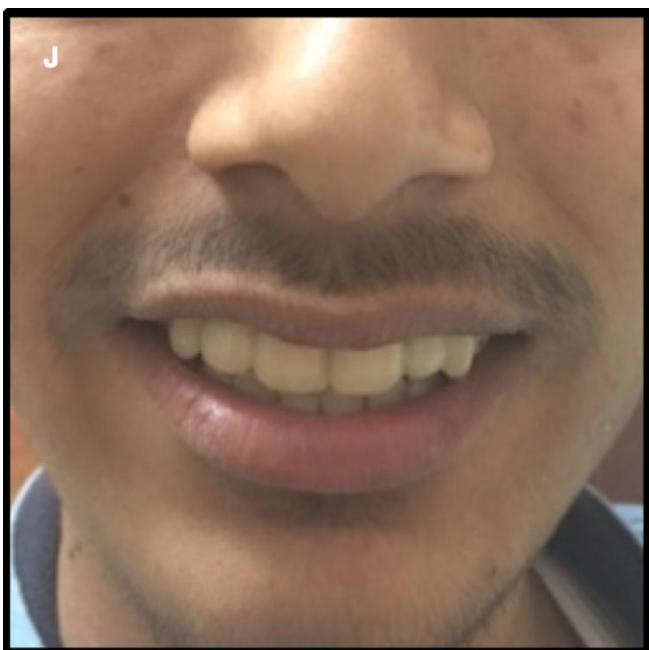


Fig J. Post operative smile of Case 2.

Discussion

Fluorosis is a major health problem in India with over 65 million people at risk and 6 million children seriously affected.⁹ Fluoride is considered as a double edged sword, its presence in ground water is of utmost importance from health perspective. In low concentration it prevents dental caries whereas in high concentration of fluoride it causes mottling of teeth and skeletal fluorosis. Fluoride analysis revealed no specific trend observed for distribution of Fluoride in Madhya Pradesh. The maximum fluoride concentration has been observed at Rehgaon (3.85mg/l) Mandla district and various small towns. Fluorosis significantly disturbs enamel and adversely affects esthetics causing psychological distress to the affected person; however, with regard to skeletal fluorosis accumulation of

fluorides also has crippling effects.² Enamel fluorosis treatment usually ranges from free hand bonding restorations to ceramic full jacket crowns.⁶ Vital bleaching does improve the esthetics to certain extent; however, has partial success with regard to moderate to severe fluorosis. In case of severe mottling, staining is accompanied by pitting and other surface defects; bleaching in such cases is best viewed as a useful adjunctive treatment preceding bonding or veneering. If fluorosis causes severe enamel loss, bleaching is contraindicated.⁴

The concept of veneering has been recently described in the dental literature, although it is only with the advent of efficient bonding of resins to enamel and dentine that esthetically pleasing, durable and successful restorations can be made as described in case 2.⁷ Veneers have been successfully employed for management of mild to moderate grade fluorosis. In case B, the patient had moderate fluorosis which necessitated the need for veneers; however, due to patient's time constraint direct composite veneer treatment option was selected. Direct composite veneer has advantage of minimal chair side when compared to indirect ceramic veneers; however, it's disadvantage is long term wear resistance and color stability.⁸ To increase the wear resistance nanohybrid composite were used with increased wear resistance.

In case A, patient had moderate to severe fluorosis with history of bleaching and veneers which was unsuccessful. This necessitated the need for treatment by full jacket crowns and economic restraints leading to the decision of porcelain fused to metal crown procedure. This procedure also requires restoring vertical dimensions of occlusion hence careful investigations and preparation is essential. This procedure has a distinct advantage that provides desired aesthetic results and functional efficiency. The main disadvantage being extensive lab procedure and operators efficiency.⁵

This treatment option is limited to cases with severe fluorosis.

Conclusion

The diagnosis of dental fluorosis in all the cases described was based on their familial history, place of residence and type of drinking water used. All the patients included in the case series were residents of Madhya Pradesh. A chief component of diagnosis of dental fluorosis is differentiating it from amelogenesis imperfecta and molar-incisal hypo mineralization (MIH) and the most important data for differentiating dental fluorosis from other pathologies will be familial history, place of residence, chronology of discoloration appearance.¹⁰ A vast number of new treatment options combining these various treatment modalities are emerging. The other treatment options available include laser assisted bleaching, abrasion employing abrasive pastes. This article does not advocate that one treatment option is superior to another; however, states that the severity of the lesion alone determines the treatment option.^{11, 12}

References

1. Herb et al. Esthetic management of Dental Fluorosis. *Int J Dent Clinic* 2011; 3(2):80-81.
2. Ground Water Year Book Madhya Pradesh 2018: 54.
3. Murrin JR, Barkmeier WW. Chemical treatment of endemic dental fluorosis. *Quintessence Int Dent Dig.* 1982 Mar; 13(3):363-369.
4. Goldstein RE. Bleaching teeth: new materials—new role. *J Am Dent Assoc.* 1987; 115: 44E–52E
5. Sherwood IA. Fluorosis varied treatment options. *J Cons Dent.* 2010; 13(1):47-53.
6. Nazirkar G, Meshram S. An evaluation of Two Modern All-Ceramic Crowns and their comparison with Metal Ceramic Crowns in terms of the Translucency and Fracture Strength. *Int JDent Clinics.* 2011; 3(1): 5-7.
7. Akapata E. Occurrence and management of dental fluorosis. *Int Dent J.* 2001; 51: 325-333.
8. Roberson, Heymann, Swift. *Sturdevant's Art and Science of Operative dentistry. Additional conservative esthetic procedures.* 4th ed. Missouri: Mosby 2002: 610-620.
9. Susheela A. Fluorosis management program in India. *Curr Sci* 1999; 77: 1250-1255.
10. Peter J, Crawford M. AgnesBloch-Z. *Amelogenesis Imperfecta Rev* 2007; 2: 17-28.
11. Watts A, Addy M. Tooth discoloration and staining: A review of literature. *Br Dent J* 2001; 190: 309-316.
12. Ardu S, Stayridakis M, Krejci I. A minimally invasive treatment of severe dental fluorosis. *Quintessence Int* 2007; 38: 455-458.