



Fertility preserving surgery for ovarian cancer in young patients

Authors

Dr Sai Sudha Alaparathi¹, Dr Kaushik Hari², Dr Madhavi Polu³

Surgical Oncology Department, NRI General Hospital, Mangalgi, Guntur District,
Andhra Pradesh, 522503, India

Abstract

Ovarian cancer is considered to be one of the most lethal gynaecological malignancies. It is estimated that 10% of ovarian cancer cases will be diagnosed in women of reproductive age^[1] and > 80% would be in advanced stage. Conservative treatment can be carried out for stage 1 to preserve fertility. However, accurate staging prior to surgery is difficult and some of these may require chemotherapy after fertility preserving surgery which affects ovarian reserve and there may be lot of after effects of chemotherapy on conception.

Introduction

Approximately 25% of patients with the diagnosis of ovarian cancer are classified as stage 1. The definitive surgery for stage 1 ovarian carcinoma is removal of uterus with both the ovaries and tubes in addition to rest of the staging procedure. The reason for this approach is the fear of leaving an undiagnosed carcinoma in contralateral normal looking ovary when only one ovary is macroscopically involved^[2]. Conservative treatment should be carried out for stage 1 when future fertility is desired.

Materials and Methods

This is a prospective study to study the outcome of fertility preserving surgery in early stage ovarian cancers in young patients. 10 patients were compiled in this study which was done in NRI General Hospital.

Preoperative assessment included complete blood picture, liver and kidney function tests, CA-125,

AFP, beta HCG, LDH, CEA, chest x-ray, ultrasound abdomen and pelvis, CECT abdomen and pelvis.

Inclusion Criteria

Patients with diagnosed ovarian carcinoma stage 1, age <40 years.

Exclusion Criteria

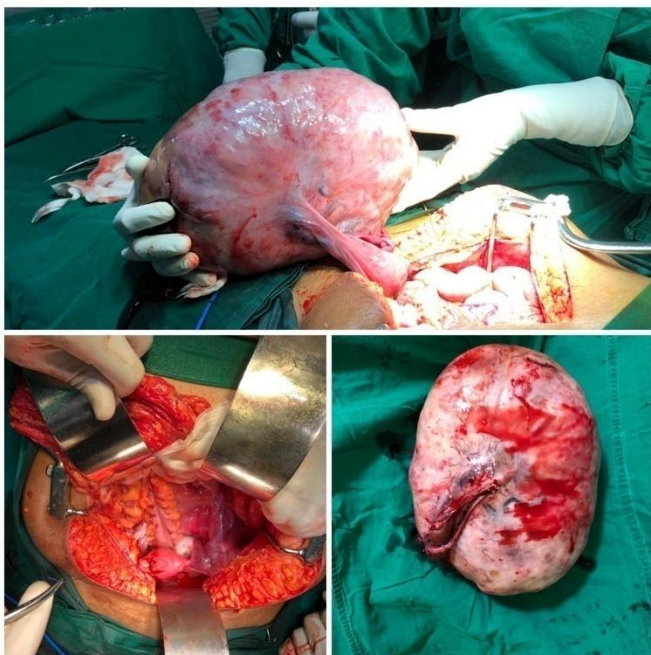
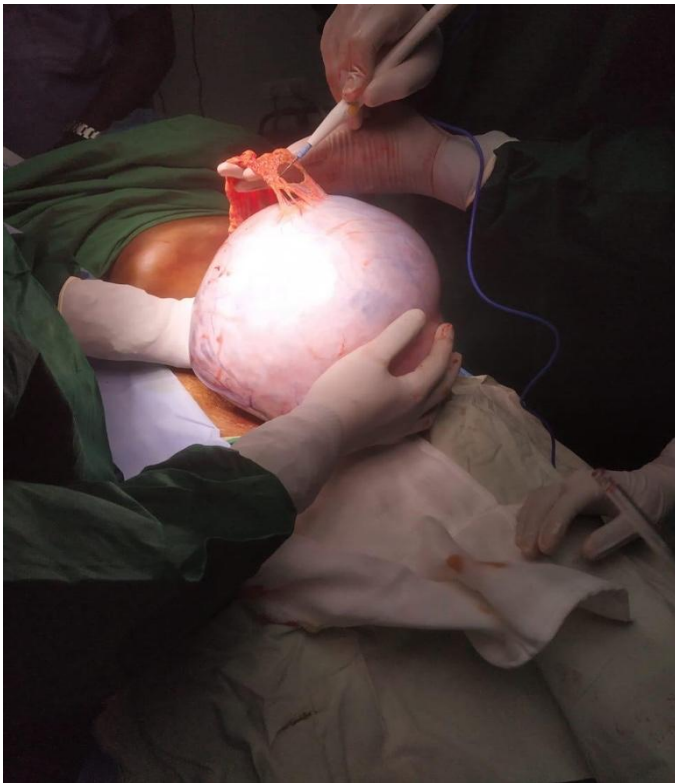
Patients with disease extending beyond stage 1.

Surgery

All 10 patients underwent primary open exploratory laparotomy.

On entering the abdomen, aspiration of ascites had been sent for cytology examination.

All the patients underwent unilateral salpingo-oophorectomy and omentectomy, if contralateral ovary and pelvic abdominal peritoneum appeared to be free of gross disease.



Results

2 patients conceived spontaneously after fertility preserving surgery and 1 patient developed metastasis. All the patients had tumours being either serous or mucinous type.

Chemotherapy

Chemotherapy was only administered following recurrence of invasive disease. Mid treatment assessment by CA-125 and ultrasound abdomen and pelvis. Then the patient was put of follow up schedule every 3 months until which confirmed no new recurrence of disease

Follow Up

Follow up consisted of serum CA-125 estimation every 3 months, during first 2 years, thereafter for every 6 months. Ultrasound abdomen and pelvis done every 3 months and CT was done in case of any suspicion finding.

Dicussion

Germ cell ovarian tumours more commonly occur at younger age, the reported median age being 24 years^[3].

Germ cell ovarian tumours are dysgerminoma, embryo also immature teratoma, choriocarcinoma, yolk sac tumour, poly embryonic mixed germ cell tumour.

Epithelial ovarian tumours are serous, mucinous, clear cell and endometriod.

ICON-1 study concluded that adjuvant chemotherapy improves survival and delays recurrence in early stage ovarian cancer^[4].

Successful pregnancies have been reported in patients after treatment for early stage invasive ovarian cancer, however there is risk of relapse. When relapse occurs in contralateral ovary alone then salvage treatment is cure. If disseminated recurrence occurs with peritoneal spread then cure is uncommon.

Long term survival of patients with stage1 ovarian cancer treated with unilateral saplingo-oophorectomy is good with reported 5 year survival rate 89-90%.

Immature teratoma represents 1% of all ovarian carcinomas. Median age for presentation was reported to be 19 years^[5].

Granulosa cell tumours of ovary accounts for 1-2%. Dysgerminoma is the most common malignant tumour of ovary.

Epithelial tumours of ovary- more common than germ cell tumours, occurs in women more than 30 yrs of age, it may be cystic mass with or without solid component, peritoneal carcinomatosis may or may not be present. Tumour markers are CA125, CEA.

Germ cell tumours of ovary- common in second and third decade of life, these are solid masses of usually more than 15cm, it can be unilateral or bilateral. Tumour markers are AFP for yolk sac tumour, immature teratoma, mixed germ cell tumour, HCG for choriocarcinoma, embryonic, polyembryonal, mixed germ cell tumour, LDH for dysgerminoma, yolk sac tumour, immature teratoma. Effects of chemotherapy on ovary include decline in number of primordial and larger maturing follicles and end results can be premature ovarian failure, leading to permanent infertility. premature ovarian failure is reported only in 20-30% who underwent chemotherapy.

After chemotherapy at least 6month interval is essential before pregnancy to eliminate effect of chemotherapy on Oocytes, as folliculogenesis takes about 6 months^[6].

Current fertility sparing methods include ovarian tissue cryopreservation, Oocytes cryopreservation.

Future fertility preserving methods are invitro ovarian follicle growth, in vitro follicle maturation which are currently in experimental stage.

Conclusion

Fertility preserving surgery in stage 1 ovarian carcinoma can be considered as a safe treatment option in patients within childbearing period.

References

1. Ditto A, Bogani G, Martinelli F, Raspagliesi F. Fertility-sparing surgery in high risk ovarian cancer. *J Gynecol Oncol* 2015;26:350-1.
2. Fakhr I, Abd-allah M, Ramzy S, Mohamed AM, Saber A. Outcome of fertility preserving surgery in early stage ovarian cancer. *J Egypt Natl Canc Inst* 2013;25:219-22.
3. Mangili G, Sigismondi C, Gadducci A, Cormio G, Scollo P, Tateo S, *et al.* Outcome and risk factors for recurrence in malignant ovarian germ cell tumours: A MITO-9 retrospective study. *Int J Gynecol cancer* 2011;21:1414-21.
4. Colombo N, Guthrie D, Chiari S, Parmar M, Qian W, Swart AM, *et al.* International collaborative ovarian neoplasm trial 1: A randomised trial of adjuvant chemotherapy in women with early stage ovarian cancer. *J Natl Cancer Inst* 2003;95:125-32.
5. Deodhar KK, Suryawanshi P, Shah M, Rekhi B, Chinoy RF. Immature teratoma of the ovary: A clinicopathological study of 28 cases. *Indian J Pathol Microbiol* 2011;54:730-35.
6. Genes M, Neis F, Kramer B, Walter C, Brucker S, Von Wolff M, *et al.* Possibilities of fertility preservation in young patients with ovarian cancer. *Anticancer Res* 2014;34:3851-4.