



Study on incidence of testicular tuberculosis in cases of epididymo-orchitis

Authors

Arvind Anchavle¹, Ritesh Dhanbhar², Rahul Maske³

Abstract

Objective: *This study was performed to determine incidence of testicular tuberculosis in cases of epididymo-orchitis.*

Methodology: *Retrospective observational study was carried out at our institute in 500 cases of epididymo-orchitis. All cases were initially managed with antibiotics and anti inflammatory drugs. Patient in which orchidectomy is done, testis were sent for histopathological evaluation.*

Results: *Of 500 cases, 0.8% of the cases were confirmed with the diagnosis of testicular tuberculosis. Out of 143 cases that underwent Orchidectomy, 2.7% of cases were having testicular tuberculosis.*

Conclusion: *It is important to keep in mind that testicular tuberculosis is a possible differential, while diagnosing cases of scrotal swellings and in cases of epididymo-orchitis. A negative history of Pulmonary TB does not necessarily exclude the diagnoses of testicular TB.*

Introduction

Tuberculosis is one of the most baffling diseases known to mankind. India is known region for its occurrence. Mycobacterium tuberculosis infects about one third of the world population and kills about three million patients each year.⁽¹⁾ About 70% of the cases are of pulmonary etiology, but one of the rare forms of Tuberculosis (TB) is testicular tuberculosis. It presents as a painful or painless testicular swelling with or without scrotal ulceration or discharging sinus. Dissemination of TB to the testis may result in secondary infection of epididymis. In many of these cases, association with Tuberculous prostatitis and seminal vesiculitis is seen. Most commonly the epididymis is involved, and it is believed that epididymitis usually represents a secondary spread from these other involvements of the genital tract.^(2,3) Infertility is known to occur in these cases.

Materials and Methods

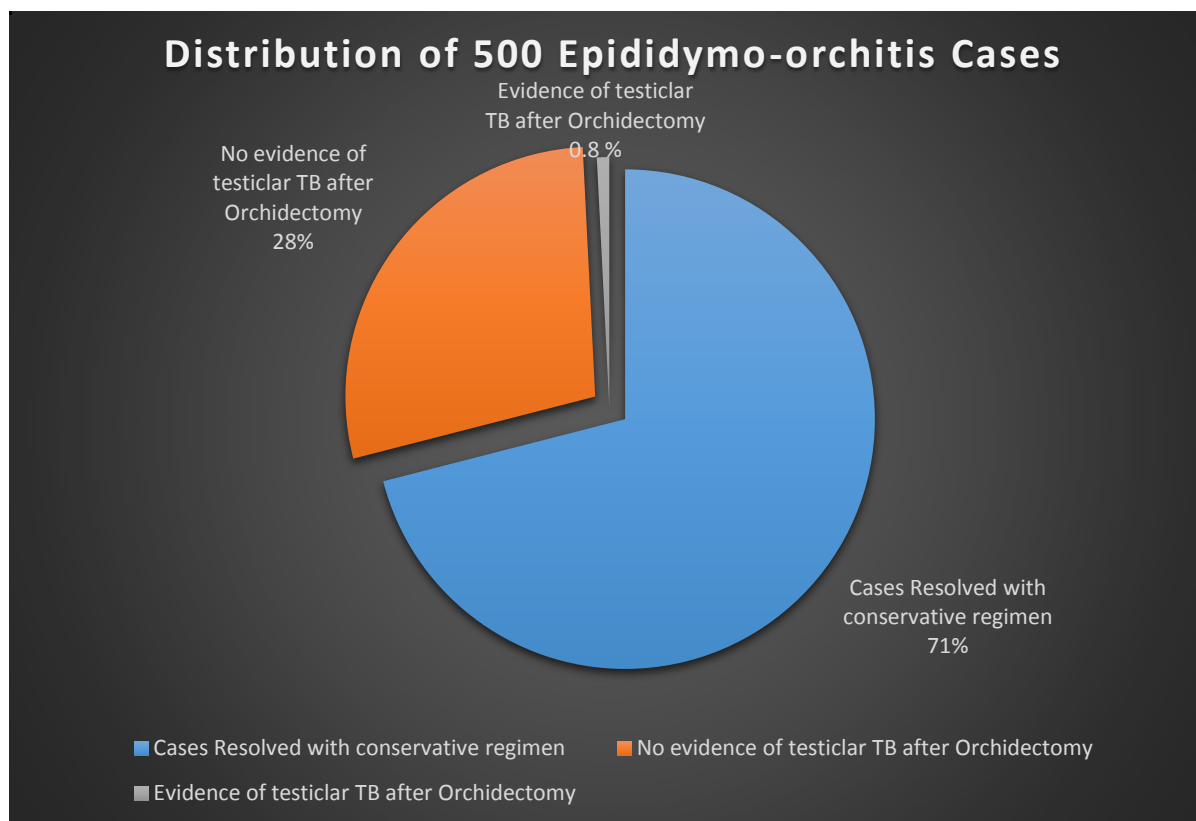
Retrospective observational study was carried out at our institute in 500 cases of epididymo-orchitis. Patients presented with complaint of scrotal swelling with minimal or no history of pain, with or without fever and dysuria are included in this study. None of the patients had any previous history of pulmonary tuberculosis. All cases were initially managed with antibiotics and anti inflammatory drugs. Patient in which orchidectomy is done, testis were sent for histopathological evaluation.

Results

Out of 500 cases of epididymo-orchitis, 357 cases resolved with conservative regimen. Remaining 143 cases were underwent orchidectomy. Out of the 143 cases, which were sent for histopathological evaluation, 4 cases showed multiple granulomas composed of epithelioid cells,

Langerhans' Giant cells and lymphoplasmacytic cells. The granulomas were seen destroying seminiferous tubules. The sections from spermatic cord showed focal dense collection of lymphoplasmacytic cells. These findings were confirmatory for testicular Tuberculosis. Of 500 cases, 0.8% of the cases were confirmed with the

diagnosis of testicular tuberculosis. Out of 143 cases that underwent Orchidectomy, 2.7% of cases were having testicular tuberculosis. These cases were further managed with anti tubercular therapy after adequate evaluation and examination.



Discussion

Scrotal infection with Mycobacterium tuberculosis is a rare entity, occurring in about 7% of patients suffering from tuberculosis⁽⁴⁾ Prevalence of an associated history of previous Tuberculous infection ranges from 0% to 70% of cases.⁽⁶⁾ With the rise of HIV infection in the world, the incidence of opportunistic extra pulmonary tuberculosis has also simultaneously increased, the genitourinary system being the most common affected site.⁽⁵⁾ Clinically, tuberculosis of the scrotum is not easily differentiated from a tumour or an infraction. It commonly presents without specific clinical symptoms in young men under the age of 40 and can be mistakenly diagnosed as a testicular tumour.⁽⁷⁾ Common symptoms are tense swollen testicles/epididymis

associated with / without groin pain, fever, dysuria and localised tenderness often divert the diagnoses to malignancies or inflammations.⁽⁸⁾ In cases of Tuberculous epididymitis where urine cultures can be negative for bacilli in half of the specimens and there are no clinical symptoms from other organs or systems, diagnosis is even more difficult. Moreover, radiographic illustrations cannot differentially diagnose in an adequate manner. Accurate differentiation is, however, important for ensuring proper treatment^(5,9) Both bacterial and Tuberculous infections usually involve both the epididymis and the testes, but finding a heterogeneously hypoechoic pattern of epididymal enlargement should point towards the diagnosis of testicular tuberculosis.⁽⁵⁾ According to this study it should keep in mind that testicular tuberculosis is

a possible differential, while diagnosing cases of scrotal swellings and in cases of epididymo-orchitis. This finding is consistent with Chudasama N et al study.⁽⁵⁾ In most cases the diagnosis is made following an orchidectomy via histopathological confirmation. These patients are further treated with Anti tubercular chemotherapy.

Conclusion

It is important to keep in mind that testicular tuberculosis is a possible differential, while diagnosing cases of scrotal swellings and in cases of epididymo-orchitis. A negative history of Pulmonary TB does not necessarily exclude the diagnoses of testicular TB. If diagnosed earlier the patient can be successfully managed with anti tubercular chemotherapy without the possible need for an orchidectomy. If diagnosed after an orchidectomy, a course of anti tubercular chemotherapy can be recommended.

References

1. Kumar V, Abbas AK, Aster JC, Fausto N. Robbins and Cotran Pathologic Basis of Disease. 8th ed. Philadelphia: WB Saunders Co; 2007.
2. Cotran RS, Kumar V, Stanley L, Robbins WB. Robbins' Pathologic Basis of Disease. 5th ed. Philadelphia: WB Saunders Co; 1994.
3. Coats J. A Manual of Pathology. Charleston: Nabu Press; 2010.
4. Muttarak, M and Peh, WC (2006). Case 91: tuberculous epididymo-orchitis. Radiology 238: 748–751.
5. Chudasama N, Sidhu R, Shah N. Classical case of tuberculous Epididymo-orchitis and how to rule out differentials on sonography. West Afr J Radiol 2016;23:32-5.
6. Dogra VS, Gottlieb RH, Oka M, Rubens DJ. Sonography of the scrotum. Radiology 2003;227:18-36.
7. Miu WC, Chung HM, Tsai YC, Luo FJ. Isolated tuberculous epididymitis

masquerading as a scrotal tumor. J Microbiol Immunol Infect 2008 Dec;41(6):528-30.

8. Papadopoulos A, Bartziokas K, Morphopoulos G, Anastasiadis A, Makris D. A rare case of isolated tuberculous epididymitis in a young man presenting with a swollen testicle. OA Case Reports 2013 Jan 31;2(1):3.
9. Mete C, Severin L, Kurt GN, Michael CB, Truls EBJ, Botto H. EAU guidelines for the management of genitourinary tuberculosis. Eur Urol 2005 Sep;48(3):353-62.