



Sternal Rhabdomyosarcoma Presenting As Generalised Seropositive Myasthenia Gravis

Authors

Vinit Suri^{1*}, Mohit Kalangi Venkata Naga², Swapnil Jain³, Kunal Suri⁴

¹Senior Consultant, Department of Neurology, Indraprastha Apollo Hospital, New Delhi, India

^{2,3}Senior Resident, Department of Neurology, Indraprastha Apollo Hospital, New Delhi, India

⁴Post Graduate Resident, Department of Medicine, Geetanjali Medical College, Udaipur, India

*Corresponding Author

Dr Vinit Suri

Senior Consultant, Department of Neurology, Indraprastha Apollo Hospital, New Delhi, India

Abstract

We report a 43 year old male patient who presented with pure motor generalised predominantly proximal quadriparesis with true fatigability, binocular diplopia, fatigable ptosis, dysarthria with mild hypernasality and dysphagia of 2 weeks duration with painless enlargement of a pre-existing sternal swelling, which was diagnosed as enchondroma previously. Repetitive nerve stimulation test confirmed the clinical diagnosis of Myasthenia gravis and acetylcholine receptor antibody was positive. Chest CT scan detected an anterior mediastinal mass which on histopathological examination revealed a pleomorphic rhabdomyosarcoma. We report this rare association of Myasthenia gravis being a presenting manifestation of pleomorphic rhabdomyosarcoma.

Keywords: Myasthenia Gravis, Seropositive, Rhabdomyosarcoma.

Introduction

Paraneoplastic involvement of neuromuscular junction usually presents as Lambert – Eaton syndrome. Only a few cases of paraneoplastic myasthenia gravis have been reported. Paraneoplastic myasthenia gravis is described commonly in association with thymoma and only rarely with extra thymic tumors which commonly include malignancies of breast and lung ; and rarely with squamous cell carcinoma of oral cavity, invasive bladder cancer, adenocarcinoma of prostate, basal cell carcinoma of skin, renal cell carcinoma, gastric and colon adenocarcinoma among others¹.

Rhabdomyosarcomas are relatively common tumors in children and rare in adults². Neurological anti – Hu syndrome, non - neurological cutaneous vasculitis and hypertrophic osteoarthritis are the paraneoplastic syndromes described in association with rhabdomyosarcoma^{3, 4, and 5}. Only 2 cases in the past of Myasthenia gravis presenting as a paraneoplastic manifestation of rhabdomyosarcoma have been described^{6,7}.

Case History

A 43 year old male with no significant past medical history noticed a painless sternal swelling at age 25 years, which on CT scan of chest

showed a mass in the manubrium sterni with calcification, suggestive of an Enchondroma. The lesion was excised and biopsy confirmed an Enchondroma. Subsequently, at age 37 years he noticed a new swelling just superior to the site of previous lesion. Over the next two years he noticed persistence of the swelling. CT scan of chest revealed a lytic lesion of size 3.9 X 4.7 X 6.6 cm with sclerotic margins in the left manubrium. Trucut biopsy revealed an Enchondroma with no cellular atypia. At age 43 years, patient developed generalised muscular weakness and easy fatigability, binocular diplopia with true fatigability with weakness of hand grip and difficulty climbing stairs. Within a week he developed fatigable ptosis, dysarthria, hypernasality with difficulty in chewing and swallowing solids. Simultaneously he noticed painless increase in the size of sternal swelling. Examination revealed subtle orbicularis oculi weakness, full extra ocular movements with binocular diplopia and diplopia charting suggestive of right lateral rectus palsy. Upper and lower limb power was 4-/5 with proximal more than distal weakness, with elicitable deep tendon jerks, flexor plantar responses and preserved exteroceptive and proprioceptive sensations. Non tender sternal bony swelling of size 6 X 7 cm was observed in the upper half of the sternum. Repetitive Nerve Stimulation (RNS) studies revealed bulbar and acral significant motor unit amplitude decrement without any post exercise increment. Anti-acetylcholine receptor antibody was significantly elevated (18.01 nmol/L). Oral Pyridostigmine challenge resulted in remarkable improvement of facial and acral motor weakness. CT scan of chest revealed lytic expansile lesion in manubrium with extraosseous soft tissue and intra-thoracic extension with the tumor matrix revealing ring and arcs of calcification with large enhancing necrotic mass lesion in the anterior mediastinum (7 X 8 cm) with the mass abutting the aorta and pulmonary arteries which was compressing the left brachiocephalic vein with

bilateral pulmonary parenchymal metastases (Fig. 1).

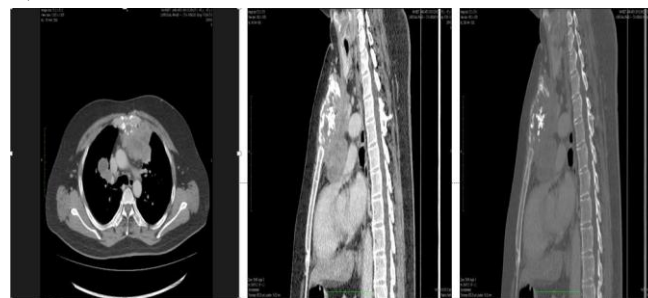


Figure 1- CT Chest

CT guided trucut biopsy of the mass revealed tumor cells arranged in sheets, cords and scattered singly with individual cells being medium to large, oval to elongated with abundant eosinophilic cytoplasm with nuclear pleomorphism and hyperchromasia, occasional mitotic figures and large areas of necrosis (Fig. 2).

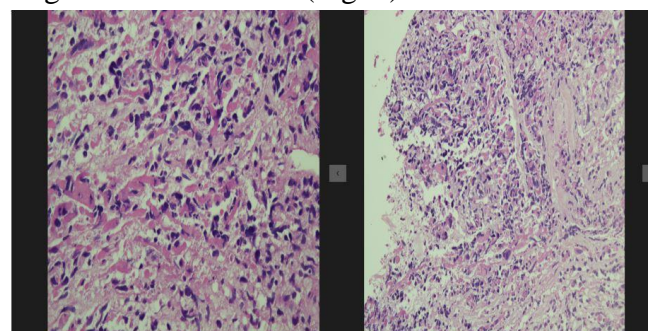


Figure 2- Trucut Biopsy

Immunohistochemistry revealed diffuse strong positivity for vimentin, desmin and myo D1 and patchy positivity for myogenin and SMA without expression for CK or S100 with Mib-1 labelling index of 60-70% suggestive of high grade sarcoma consistent with pleomorphic rhabdomyosarcoma (Fig. 3).

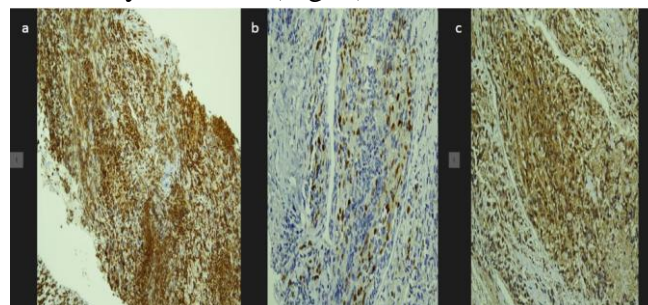


Figure 3- Immunohistochemistry

MRI scan of brain, serum creatine phosphokinase, serum electrophoresis and CSF analysis did not

reveal any significant abnormality. Patient had near complete resolution of oculo-bulbar and acral fatigue with oral pyridostigmine.

Discussion

Myasthenia gravis (MG) is an autoimmune disorder leading to skeletal muscle weakness and fatigability. Various subgroups of MG have been defined according to presence of pathogenic autoantibodies. Three autoantibodies of importance are anti-acetylcholine receptor antibodies, anti-MuSK antibodies and anti-LRP 4 antibody. MG has been associated with other comorbid illnesses. MG patients have an increased risk of other autoimmune disorders with a frequency of 15%⁸. Commonly associated autoimmune disorders include autoimmune thyroiditis, lupus, rheumatoid arthritis and rarely multiple sclerosis. Cardiomyositis, sub-clinical cardiac dysfunction, autoimmune encephalitis and neuro-psychiatric disturbances have been described to occur with a higher frequency in MG patients. MG can also be caused as a paraneoplastic manifestation of thymic lesions and has been described rarely with extra thymic malignancies commonly including neoplasms of lung and breast, and rarely squamous cell carcinoma of the oral cavity, invasive bladder cancer, adenocarcinoma of prostate, basal cell skin cancer, gastric or colon adenocarcinoma and renal cell cancer¹.

Rhabdomyosarcomas are high grade small round blue cell tumors with skeletal muscle differentiation. They occur commonly in children under 5 years age and are rarely seen in adults². They are slightly more common in boys than in girls. Although these tumors can arise almost anywhere, they commonly arise from the head and neck (40%), the genito-urinary tract (25%), and the extremities (20%). Tumors can even arise in locations where skeletal muscles are not found. Tumors that arise in the orbit, non-parameningeal head and neck and genital tracts are considered "favourable" for prognosis. All other sites are considered "unfavourable". Rhabdomyosarcomas

are known to express acetylcholine receptors and rhabdomyosarcoma cell lines have been used to quantify acetylcholine antibodies⁹. Despite this association with production of acetylcholine receptor antibodies only two cases of rhabdomyosarcoma related Myasthenia gravis have been reported wherein one patient had a chest rhabdomyosarcoma⁶ and the other had renal rhabdomyosarcoma⁷. To our knowledge ours is the third reported case of seropositive myasthenia gravis associated with rhabdomyosarcoma. Apart from Myasthenia, rhabdomyosarcoma has been associated with other paraneoplastic syndromes including neurologic Anti-Hu syndrome³, non-neurological cutaneous vasculitis⁴ and hypertrophic osteoarthritis⁵. Four variants of rhabdomyosarcoma are alveolar, embryonal, pleomorphic and botryoid. Pleomorphic subtype is more common in adults and primarily seen in the limbs². Prognosis of rhabdomyosarcoma is poorer in adults compared to children. Rhabdomyosarcoma can spread locally, regionally or distantly. Local spread is when the tumor infiltrates the tissues in the immediate vicinity of where it started. Regional spread is when the tumor as travels to the lymph nodes that drain the area where it arose. The highest chance that the rhabdomyosarcoma will spread to the lymph nodes is for children with tumors that arise in the extremities and in older boys (10 years of age or older) with para-testicular tumors. Distant spread or metastasis, occurs to the lungs, bones, very uncommonly to the brain, liver or spleen in less than 20% patients.

Our patient presented with an enchondroma which had secondarily transformed into a rhabdomyosarcoma. He simultaneously developed seropositive MG, and considering the temporal relation between the events, we can attribute the MG to be secondary to the anti-acetylcholine receptor antibody produced by the rhabdomyosarcoma. We would like to highlight this rare association of rhabdomyosarcoma associated MG, which though expected to be frequently found, is seen exceedingly rarely.

Conclusion

Rhabdomyosarcoma can rarely present as seropositive myasthenia and should be evaluated for in non-responding seropositive myasthenic patients, since management in this subgroup would primarily be based on the management of rhabdomyosarcoma.

References

1. Basta I, Pekmezovic T, Peric S, Nikolic A, Rakocevic-Stojanovic V, Stevic Z et al. Extrathymic malignancies in a defined cohort of patients with myasthenia gravis. *J Neurol Sci.* 2014 Nov 15; 346(1-2):80-84.
2. Dalfior D, Eccher A, Gobbo S, Brunelli M, Martignoni G, Menestrina F, Dalla PP, Dvornik G. Primary pleomorphic rhabdomyosarcoma of the kidney in an adult. *Ann Diagn Pathol.* 2008 Aug; 12(4):301-3. doi: 10.1016/j.anndiagnpath.2007.01.005. Epub 2007 Oct 29.
3. Schilstra A, van Tuijl JH, van Suylen RJ, Faber CG, ten Velde GP. Unclassified rhabdomyosarcoma in a patient with anti-Hu syndrome. *Acta Clin Belg.* 2005 Sep-Oct; 60(5):248-51.
4. Pelajo CF, de Oliveira SK, Rodrigues MC, Torres JM. Cutaneous vasculitis as a paraneoplastic syndrome in childhood. *Acta Reumatol Port.* 2007 Apr-Jun; 32(2):181-3.
5. Garganese MC, De Sio L, Serra A, De Ioris MA, Bock C, Donfrancesco A, Ciofetta G. Rhabdomyosarcoma associated hypertrophic osteoarthropathy in a child: detection by bone scintigraphy. *Clin Nucl Med.* 2009 Mar; 34(3):155-7. doi:10.1097/RLU.0b013e3181966dfb.
6. Mehmood QU, Shaktawat SS, Parikh O. Case of rhabdomyosarcoma presenting with myasthenia gravis. *J Clin Oncol.* 2011 Aug 1; 29(22):e653-5. Doi: 0.1200/JCO.2011.34.5991. Epub 2011 Jun 6.
7. Prakasa RB, Rambabu B, Sridhar P. Primary Renal Rhabdomyosarcoma in An Adult Patient Presenting With Myasthenia Gravis: Unusual Presentation of A Rare Malignancy. *INTERNATIONAL JOURNAL OF SCIENTIFIC RESEARCH.* 2015; 4:264-265.
8. Mao ZF, Yang LX, Mo XA, et al. Frequency of autoimmune diseases in myasthenia gravis: a systematic review. *Int J Neurosci* 2011; 121:121-129.
9. Lyons BW, Wu LL, Astill ME, Wu JT. Development of an assay for modulating anti-acetylcholine receptor autoantibodies using human rhabdomyosarcoma cell line. *J Clin Lab Anal.* 1998; 12(5):315-9.
10. Niimi K, Nagata E, Murata N, Sato M, Tanaka J, Horio Y et al. Lung cancer associated with Seronegative Myasthenia Gravis. *Intern Med.* 2015; 54(11):1381-1384.