



Case Report

Recurrent Intestinal Obstruction with Multiple Intussusception in a Patient of Peutz-Jeghers Syndrome

Authors

Dr Naresh Kumar Damerla, Dr Thogari Kranthi Kumar*

*Corresponding Author

Dr Thogari Kranthi Kumar

Abstract

Peutz-jeghers syndrome (PJS) is a rare hamartomatous polyposis syndrome characterised by the presence of intestinal polyps and mucocutaneous melanotic pigmentataion. It is associated with various gastrointestinal and extraintestinal malignancies. This case report deals with the clinical presentation, investigations, operative findings, and outcome of a 10-year-old male child harboring this disease.

Keywords: *intestinal obstruction, multiple intussusceptions, Intestinal hamartomatous polyps, Peutz–Jeghers syndrome.*

Introduction

Hamartomas result from a disorder of differentiation during embryonic development leading to disorganized overgrowth of mature and specialized tissue indigenous to its normal site. PJS is the second most common hamartomatous polyposis after juvenile polyposis syndrome. This case report aims towards depicting the importance of history taking, meticulous clinical examination in reaching a diagnosis for this entity, and providing appropriate surgical management to these patients in case of complications.

Case Report

A 10-year-old male child presented to us with intermittent episodes of colicky abdominal pain with associated multiple episodes of bilious vomiting for the last 3 months. He was admitted

in the past, was evaluated with ultrasound abdomen reported multiple transient intussusception. He was managed conservatively with nasogastric tube and intravenous fluids, he improved symptomatically with that. Later we referred the child to a higher centre to consult paediatric surgeon for further management. there he had colonoscopy which showed normal study and he didn't undergo any intervention there as he improved symptomatically. After couple of months he presented to us with acute abdomen, with aggravated similar complaints. Hence we decided to do diagnostic laparoscopy after getting consent from the parents. We converted laparoscopy to laparotomy as there were multiple intussusceptions. Intra-operatively we found multiple intussusceptions at a distance of 30cms, 80cms, 100cms, and 130cms from DJ flexure with

polyps at each level of intussusception. Oral cavity examination revealed hyperpigmented patches over lips. Then we had a suspicion of PJS. On table, we decided to reduce all intussusceptions, multiple enterotomies and polyps S excision and polyps were sent for histopathological examination.

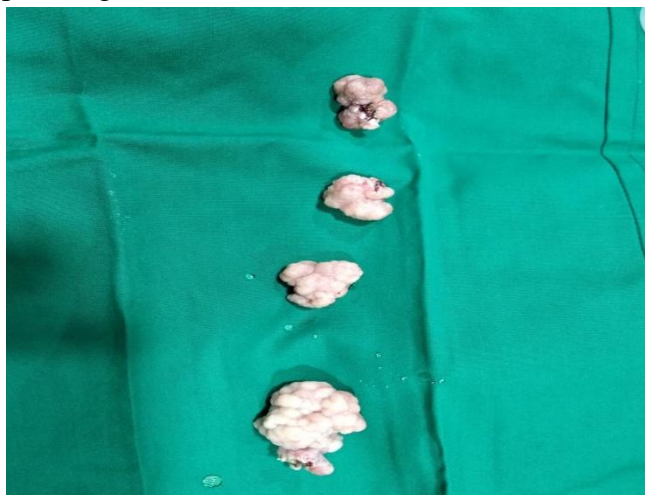


Fig 1: Polyps after excision

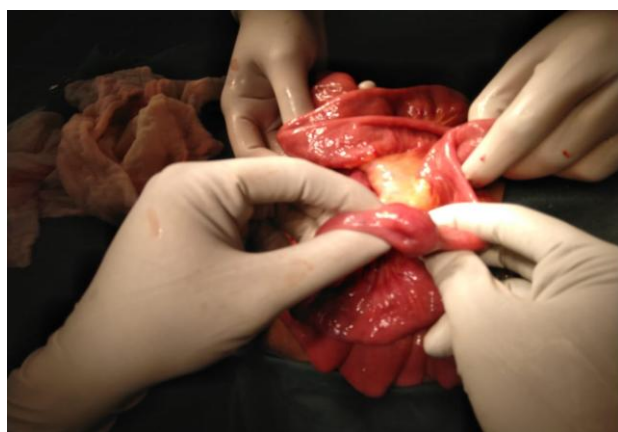


Fig 2: Intussusception Point

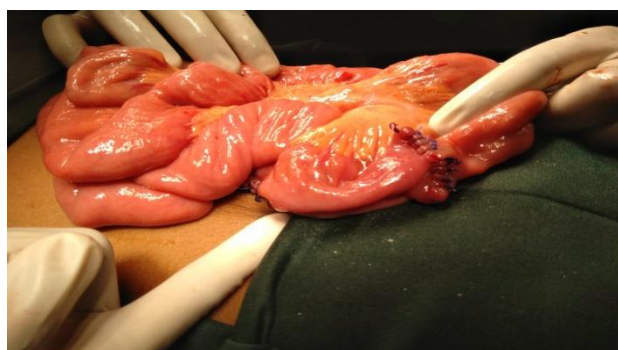


Fig 3: Enterotomy site after closure

The child had an uneventful recovery, histopathology suggested polyps to be PJS. A rare

combination of oral mucosal hyperpigmented macular spots and hamartomatous polyps predominantly in the jejunum in a child presenting with intestinal obstruction due to intussusceptions leading to clinical diagnosis of PJS. Child's family members were advised to undergo upper GI endoscopy and colonoscopy.

Discussion

PJS is a rare autosomal dominant syndrome whose diagnosis can be made in patients harboring hamartomatous intestinal polyp(s) with at least two of the following clinical criteria: labial melanin deposits, a family history of the syndrome, and small bowel polyposis.^[1] The incidence of PJS ranges from 1/50,000-1/200,000 live births.^[2] Germline mutation of the tumor-suppressor serine-threonine kinase gene LKB1/STK11 on chromosome 19 is implicated with this pathology.^[3] The pigmented mucocutaneous macules in this syndrome appear in the first few years of life, attain prominence during adolescence, and then may gradually fade away except for the buccal mucosal melanin spots which persist throughout life. These macules are dark brown, 1–5 mm in size, and located on the vermilion border of lips (94% of patients), buccal mucosa (66%), hands (74%), and feet (62%).^[4] Polyposis appears by the end of the 2nd decade of life occurring most commonly in the jejunum followed by colon and stomach. The polyps usually number between 1-20 per segment of the intestinal tract and vary in size from 0.1-5 cm in diameter.^[5]

The risks associated with this syndrome include a strong tendency of developing cancer at multiple sites. There is 2%–10% of increased risk for GI malignancies, anywhere from stomach to rectum. Increased risk for extraintestinal cancer of pancreas, gallbladder, common bile duct, breast, and thyroid is seen.^[6] There is an additional risk of gynecological malignancy of the ovary (bilateral sex cord tumor with annular tubules) and well-differentiated adenocarcinoma of the cervix known as adenoma malignum.^[7] Differential

diagnosis of familial adenomatous polyposis and hereditary nonpolyposis colorectal cancer can be made by use of colonoscopy and modified Amsterdam criteria, respectively.

Conclusion

This case report underlines the importance of a detailed history taking, clinical examination, and careful lookout for characteristic mucocutaneous hyperpigmented spots in patient presenting with intermittent intestinal obstruction in clinching the diagnosis of PJS. Histopathological finding of hamartomatous polyps of intestine further substantiates the diagnosis. The treatment is directed at dealing with the complications of obstruction in the form of reducing intussusceptions, multiple enterotomies and polyps excision. Considering the diffuse involvement of the gut, extensive resections aimed at cure are not fruitful. Since these patients carry risk for development of malignancy at various sites, regular follow-up is done to screen and detect these tumors at an early stage.

Acknowledgment

The authors acknowledge for the support by Department of General Surgery, Rural Development Hospital, Bathalapalli, Andhra Pradesh where the work has been done.

Conflicts of interest: There are no conflicts of interest.

References

1. Giardiello FM, Welsh SB, Hamilton SR, Offerhaus GJ, Gittelsohn AM, Booker SV, et al. Increased risk of cancer in the Peutz-Jeghers syndrome. *N Engl J Med* 1987;316:1511-4.
2. Utsunomiya J, Gocho H, Miyanaga T, Hamaguchi E, Kashimure A. Peutz-Jeghers syndrome: Its natural course and management. *Johns Hopkins Med J* 1975;136:71-82.
3. Hemminki A, Markie D, Tomlinson I, Avizienyte E, Roth S, Loukola A, et al. Aserine/threonine kinase gene defective in Peutz-Jeghers syndrome. *Nature* 1998;391:184-7.
4. Traboulsi EI, Maumenee IH. Periocular pigmentation in the Peutz-Jeghers syndrome. *Am J Ophthalmol* 1986;102:126-7.
5. Giardiello FM. Gastrointestinal polyposis syndromes and hereditary nonpolyposis colorectal cancer. In: Rustgi AK, editor. *Gastrointestinal Cancers*. Philadelphia: Lippincott-Raven Publishers; 1995. p. 370-1.
6. Boardman LA, Thibodeau SN, Schaid DJ, Lindor NM, McDonnell SK, Burgart LJ, et al. Increased risk for cancer in patients with the Peutz-Jeghers syndrome. *Ann Intern Med* 1998;128:896-9.
7. Srivatsa PJ, Keeney GL, Podratz KC. Disseminated cervical adenoma malignum and bilateral ovarian sex cord tumors with annular tubules associated with Peutz-Jeghers syndrome. *Gynecol Oncol* 1994;53:256-64.