



## Effect of Single Dose Intravitreal Ranibizumab in Central Retinal Vein Occlusion: A Single Center Study

Authors

Dr Ashwini Meherda<sup>1</sup>, Prof Dr Subhabrata Parida<sup>2</sup>, Dr Deepak Choudhury<sup>3</sup>,  
Dr Nikita Dash<sup>4</sup>, Mr Akbar Mehfuz Alam<sup>5</sup>

<sup>1</sup>Senior Eye Specialist, Capital Hospital, Bhubaneswar, Odisha, India

<sup>2</sup>Professor, Regional Institute of Ophthalmology, SCB Medical College, Cuttack, Odisha, India

<sup>3</sup>Senior Resident, Regional Institute of Ophthalmology, SCB Medical College, Cuttack, Odisha, India

<sup>4</sup>3<sup>rd</sup> year Resident, Regional Institute of Ophthalmology, SCB Medical College, Cuttack, Odisha, India

<sup>5</sup>Sightsaver, Regional Institute of Ophthalmology, SCB Medical College, Cuttack, Odisha, India

\*Corresponding Author

**Prof Dr Subhabrata Parida**

Regional Institute of Ophthalmology, SCB Medical College, Cuttack, Odisha, India

### Abstract

**Aim:** To find out outcome following single intravitreal injection of ranibizumab in central retinal vein occlusion (CRVO) patients in a government hospital in the capital of Odisha.

**Methods:** This study was a prospective interventional study of 18 months duration done from August 2017 to February 2019 included 15 cases of CRVO. Thorough history was taken and detail ophthalmological evaluation was done. Best corrected visual acuity (BCVA) was examined with Snellen's chart and central macular thickness (CMT) was measured using optical coherence tomography (OCT). Routine blood tests were done. Intravitreal injection of ranibizumab 0.5 mg in 0.05 ml was given. BCVA and CMT was measured at 1 day, 1 week, 1 month and 3 month follow up visit.

**Results:** Mean age was  $59.53 \pm 8.65$  years. Male: female ratio was 2.8:1. Diastolic blood pressure of  $\geq 90$  was found in 46.7% patients. 60% cases showed improvement at 1 week post-operatively. At post-operative day 1 CMT was significantly decreased ( $p= 0.0193$ ). Reduction in mean CMT at post-operative day 7 was  $>290 \mu$ .

**Conclusion:** Single intravitreal injection of ranibizumab 0.5 mg in 0.05 ml causes significant increase in vision and significant reduction of central macular thickness in patients with branch retinal vein occlusion.

**Keyword:** CRVO, ranibizumab, OCT.

### Introduction

The central retinal vein and artery possesses a common sheath at crossing points posterior to the lamina cribrosa so that atherosclerotic changes of the artery may precipitate CRVO.<sup>1</sup> Hematological prothrombic factors may also amplify the effects of an atherosclerotic predisposition. After venous

occlusion, elevation of venous and capillary pressure with stagnation of blood flow ensues, resulting in retinal hypoxia that leads to damage to the capillary endothelial cells, extravasation of blood constituents and liberation of blood mediators such as VEGF. Systemic risk factors associated with RVO include hypertension,

diabetes mellitus, cerebrovascular disease, cardiovascular disease, increased body mass index, reduced high-density lipoprotein cholesterol levels, smoking, thyroid disorder, and peptic ulcer.<sup>2</sup> Ocular risk factors associated with RVO include glaucoma or ocular hypertension, shorter axial length, and focal arteriolar narrowing and arteriovenous (AV) nicking.<sup>3</sup>

CRVO can be divided into 2 types: - Non- ischaemic CRVO and ischaemic CRVO. Non- ischaemic CRVO is called as venous stasis retinopathy and is more common than ischaemic CRVO.<sup>4</sup> Around a third will progress to ischaemic CRVO within months. Macular edema is common, but mild in these cases. Other names for ischemic central retinal vein occlusion include complete, nonperfused, or hemorrhagic retinopathy.<sup>5</sup> Central retinal vein occlusion is one of the main causes of sudden, painless vision loss in adults.<sup>6</sup> Ischaemic CRVO is characterized by substantially decreased retinal perfusion with capillary closure and retinal hypoxia. Findings typically show marked retinal edema, venous dilation, and extensive 4-quadrant haemorrhage.<sup>7</sup> Macular ischaemia and neovascular glaucoma (NVG) are the major causes of visual morbidity. Visual acuity is usually counting finger (CF) or worse. RAPD is usually present. Hundred day glaucoma may occur. Central macular edema is present in all cases. Central macular thickness (CMT) of  $>250 \mu$  requires treatment. Intravitreal anti-VEGF agents or dexamethasone may be used. Ranibizumab is a humanized, VEGF antibody fragment that neutralizes all isoforms of VEGF-A. Intravitreal injection of ranibizumab 0.5 mg in 0.05 ml may be given in CRVO. In this study the effects of single dose intravitreal injection of ranibizumab 0.5 mg in 0.05 ml in CRVO patients were evaluated.

## Methods

This study was a prospective interventional study of 18 months duration done from August 2017 to February 2019 in a government run hospital in the

capital of Odisha included 15 cases of CRVO. Detailed history was taken in patients attending retina out patients department (OPD). Visual acuity was measured using Snellen's chart. Anterior segment examination was done with slit lamp. Posterior segment examination was done with indirect ophthalmoscope and slit lamp biomicroscope with +90 D lens. Optical coherence tomography (OCT) was done to measure macular thickness. Patients having CRVO were included in the study. They were admitted and routine blood tests were done. Fasting blood sugar, post prandial blood sugar, HbA1C, serum urea, serum creatinine, lipid profile tests were checked. Thorough cardiovascular checkup was done in all patients. In the operation theatre under all aseptic conditions intravitreal injection of ranibizumab 0.5 mg in 0.05 ml provided free of cost by state government was given under topical anaesthesia in all patients. Visual acuity and macular thickness were examined at post-op day 1. Follow up examinations were done at the end of 1 week, 1 month and 3 month.

## Inclusion Criteria

1. All patients diagnosed with CRVO.

## Exclusion Criteria

1. Patients with CRVO unwilling to participate in the study.
2. Patients lost to follow up.
3. Patients with diabetic macular oedema.
4. Patients with other retinal diseases.

## Results

15 patients with CRVO of age group 48 year to 77 year were included in the study. Mean age was  $59.53 \pm 8.65$ . Age distribution is shown in table no- 1.

**Table no- 1:** Age distribution

Age group	No. of patients	percentage
40-50	2	13.3%
51-60	8	53.4%
61-70	3	20%
71-80	2	13.3%

11(73.3%) patients were male and 4 (26.7%) patients were female. Male: female ratio was 2.8:1. In 9 (60%) cases right eye was involved and in 6 cases (40%) left eye was involved. In most of

the patients fasting blood sugar was within normal limit with mean FBS =  $95.47 \pm 24.57$ . Systolic blood pressure of  $\geq 150$  was found in 4 (26.7%) patients and diastolic blood pressure of  $\geq 90$  was found in 7 (46.7%) patients. 4 (26.7%) patients

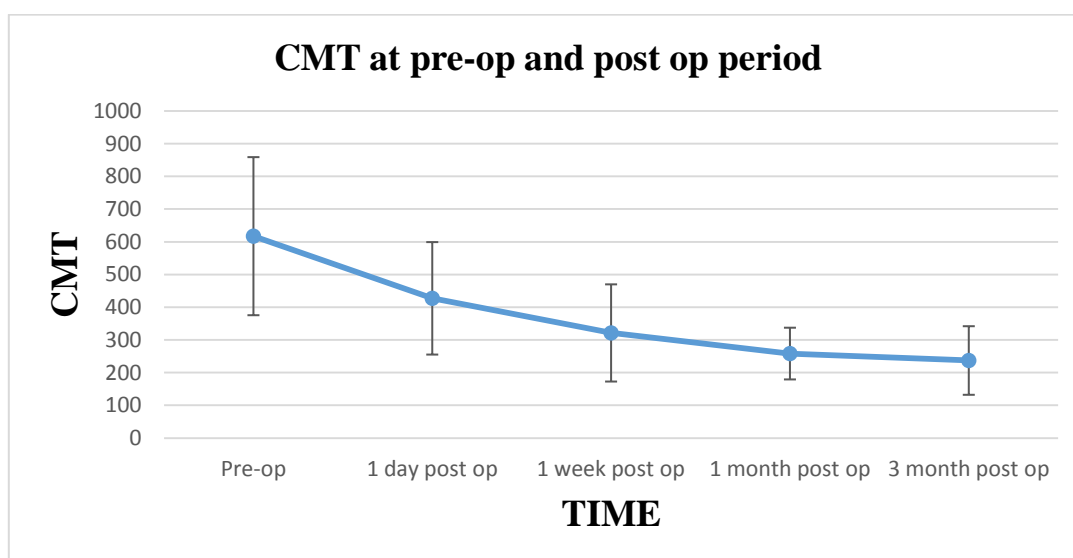
had HbA1C  $> 6.5\%$  with mean =  $6.33 \pm 0.005\%$ . In 5 (33.3%) patients LDL level was  $> 100$  mg/dl. Table 2 shows the pre-operative and post-operative best corrected visual acuity (BCVA).

**Table-2:** Pre-operative and post-operative BCVA

BCVA	Pre-operative (No. of patients)	Post-operative day 1 (No. of patients)	Post-operative 1 week (No. of patients)	Post-operative 1 month (No. of patients)	Post-operative 3 month (No. of patients)
6/6- 6/12	0 (0%)	0 (0%)	1 (6.7%)	2 (13.3%)	3 (20%)
6/18- 6/24	0 (0%)	1 (6.7%)	1 (6.7%)	4 (26.7%)	3 (20%)
6/36- 6/60	4 (26.7%)	6 (40%)	8 (53.3%)	5 (33.3%)	7 (46.7%)
$< 6/60$	11 (73.3%)	8 (53.3%)	5 (33.3%)	4 (26.7%)	2 (13.3%)

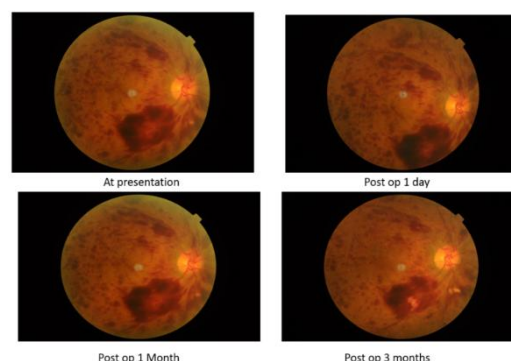
Most of the patients (73.3%) presented with BCVA of  $< 6/60$  followed by 26.7% patients with BCVA of 6/36- 6/60. 9 cases (60%) showed improvement at 1 week post-operatively. At the end of 1 month 6 patients (40%) showed good vision with BCVA  $\geq 6/24$  and 4 cases (26.7%)

still had BCVA of  $< 6/60$ . At the end of 3 month 13 cases (86.7%) had BCVA of  $\geq 6/60$  and in 2 cases (13.3%) BCVA didn't improve. Graph-1 shows pre-operative and post-operative central macular thickness (CMT).

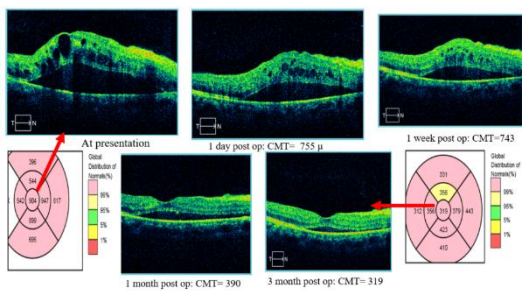


**Graph-1:** Pre-operative and post-operative mean central macular thickness

CMT at presentation was  $617.13 \pm 241.66 \mu$ . CMT at post-op day 1 was  $427.07 \pm 171.94 \mu$ , at 1 week  $321.27 \pm 148.6 \mu$ , at 1 month  $258.2 \pm 79.09 \mu$  and at 3 month  $237 \pm 104.85 \mu$ . At post-operative day 1 CMT was significantly decreased ( $p = 0.0193$ ). Gradual decrease in post-operative CMT was noted at each follow up visit. At the end of 3 month CMT became almost normal. Figure 1 shows the fundus photograph of a CRVO patient. Figure 2 shows the OCT images of retina at presentation and each follow up after giving intravitreal injection of ranibizumab.



**Figure-1:** Fundus photograph of a patient with CRVO.



**Figure-2:** OCT image of retina at presentation and each follow up.

## Discussion

In our study 15 patients with CRVO of age group 48 year to 77 year were included with mean age of  $59.53 \pm 8.65$ . However Iturralde et al in a study involving 16 eyes of 15 patients of CRVO found that patients have mean age of  $76.1 \pm 9.8$  years.<sup>8</sup> Brown et al in a study found average age of patients were 68 years. In their study 57% were males.<sup>9</sup> In our study males were 73.3% and male: female ratio was 2.8:1. In our study most of the patients (73.3%) presented with BCVA of  $< 6/60$  followed by 26.7% patients with BCVA of  $6/36-6/60$ . The central venous occlusion study group in a study of 725 patients of CRVO found visual acuity outcome was largely dependent on initial acuity. 65% of patients with initially good visual acuity ( $< 20/200$ ) had an 80% chance of having a visual acuity less than  $20/200$  at final visit.<sup>10</sup> Brown et al in a study found 46.9% patients achieved BCVA of  $\geq 6/12$  after 6 months following 0.5 mg ranibizumab intravitreal injection. Poor visual outcome of BCVA  $\leq 6/60$  was found in 15.2% cases after 6 month of injection.<sup>9</sup> In our study at the end of 3 month 86.7% cases had BCVA of  $\geq 6/60$  and in 13.3% cases BCVA didn't improve which is in correlation with Brown et al study. CMT at presentation was  $617.13 \pm 241.66 \mu$ . CMT at post-op day 1 was  $427.07 \pm 171.94 \mu$ , at 1 week  $321.27 \pm 148.6 \mu$ , at 1 month  $258.2 \pm 79.09 \mu$  and at 3 month  $237 \pm 104.85 \mu$ . The mean central macular thickness at baseline was  $887 \mu$  and decreased to a mean of  $372 \mu$  at month 1 ( $P <$

$0.001$ ) after giving intravitreal bevacizumab.<sup>8</sup> The mean central macular thickness at baseline was  $887 \mu$  and decreased to a mean of  $372 \mu$  at month 1 ( $P < 0.001$ ) after giving intravitreal bevacizumab.<sup>8</sup> Iturralde et al in their study found the mean central macular thickness at baseline was  $887 \mu$  and decreased to a mean of  $372 \mu$  at month 1 ( $P < 0.001$ ) after giving intravitreal bevacizumab.<sup>8</sup> Brown et al in a study found CMT had decreased by a mean of  $452 \mu$  (0.5 mg) in the ranibizumab groups after 6 month.<sup>9</sup> At day 7, mean reduction from baseline CFT was  $>250 \mu$  after injection.<sup>9</sup> In our study mean CMT decreased by  $>290 \mu$  after 7 days of giving operation. At the end of 3 month decrease in mean CMT was  $>380 \mu$ .

## Conclusion

Single intravitreal injection of ranibizumab 0.5 mg causes significant increase in vision and significant reduction of central macular thickness in patients with central retinal vein occlusion.

## References

1. Woo Y, Lip G, Lip P. Associations of retinal artery occlusion and retinal vein occlusion to mortality, stroke, and myocardial infarction: a systematic review. *Eye*. 2016 June; 30:1031-8.
2. Lim L, Cheung N, Wang J, Islam F, Mitchell P, Saw S, Aung T, Wong T. Prevalence and risk factors of retinal vein occlusion in an Asian population. *Br J Ophthalmol*. 2008 Oct;92(10):1316-9.
3. Cugati S, Wang J, Rochtchina E. Ten-year incidence of retinal vein occlusion in an older population the Blue Mountains eye study. *Arch Ophthalmol*. May 2006; 124(5):726-32.
4. Hayreh S, Klugman M, Beri M, Kimura A, Podhajsky P. Differentiation of ischemic from non-ischemic central retinal vein occlusion during the early acute phase. *Graefes Arch. Clin. Exp. Ophthalmol*. 1990;228(3):201-17.

5. Baseline and early natural history report. The Central Vein Occlusion Study. Arch. Ophthalmol. 1993 Aug;111(8):1087-95.
6. Klein R, Moss S, Meuer S, Klein B. The 15-year cumulative incidence of retinal vein occlusion: the Beaver Dam Eye Study. Arch. Ophthalmol. 2008 Apr;126(4):513-8.
7. Parodi MB, Bandello F. Branch retinal vein occlusion: classification and treatment. Ophthalmologica. 2009;223(5):298-305.
8. Iturralde D, Spaide R, Meyerle C, Klancnik J, Yannuzzi L, Fisher Y et al. Intravitreal bevacizumab (Avastin) treatment of macular edema in central retinal vein occlusion: a short term study. Retina. 2006 Mar; 26(3): 279-84.
9. Brown D, Campochiaro P, Singh R, Li Z, Gray S, Saroj N et al. Ranibizumab for macular edema following central retinal vein occlusion: six-month primary end point results of a phase III study. Ophthalmology. June 2010; 117(6): 1124-33.
10. The Central Vein Occlusion Study Group. Natural history and clinical management of central retinal vein occlusion. Arch Ophthalmol. 1997 April; 115:486–91.