

**Original Article****Meningioma - A common tumor with diagnostic challenge**

Authors

Pranita Mohanty¹, Anima Hota², Sunil Patra³, Shirin Dasgupta⁴¹Prof. Pathology, Dept. of Pathology, IMS & SUM Hospital²Asst. Prof. Pathology, Dept. of Pathology, IMS & SUM Hospital³Prof. Neurosurgery, IMS & SUM Hospital⁴Tutor, Dept. of Pathology, IMS & SUM HospitalIMS & SUM Hospital, S'O'A (Deemed to be University), Kalinga Nagar, Bhubaneswar, Odisha
Bhubaneswar

*Corresponding Author

Dr Anima Hota

Asst. Prof. Pathology, Dept. of Pathology, IMS & SUM Hospital, K8, Kalinga Nagar, Bhubaneswar, Odisha

Abstract**Background:** *Meningioma are generally solid tumor. Rarely they are associated with cysts and mistaken as glial or metastatic tumor with cystic or necrotic changes. It is easily recognized with modern imaging techniques.***Method:** *A prospective study of 21 meningioma cases was conducted out of total 98 intracranial CNS tumors within a period of 2 & ½ yr i.e., from Sept 2015 to Feb 2018. Cases were studied with clinical findings, radiological appearance and reviewed with histopathological examination using routine haemotoxylene and eosin stain, also immunohistochemical whenever necessary.***Results:** *Of the 21 cases of meningioma; were presented mostly in 5-6 decade with female predominance. Histopathological diagnoses were found to be meningothelial meningioma, transitional meningioma with extremely rare forms like intraparenchymal cystic meningioma, chordoid meningioma, microcystic meningioma & NF2 associated Schwannoma and meningioma.***Keywords:** *Intraparenchymal, cystic Meningioma, Intratumoural Cyst, MRI.***Introduction**

Meningiomas are common tumours of the central nervous system which counts for 15 % of all intracranial tumours and are most common extra-axial benign neoplasms^[1]. Malignant meningiomas are relatively infrequent. Typical imaging characteristics include a well circumscribed, homogenously enhancing extra-axial mass on both CT and MRI^[1]. However intraparenchymal cystic meningiomas are rare, accounting 4-7% of all meningiomas and are

challenging to diagnose both radiologically and intraoperatively and may be mistaken as a glial / metastatic tumour with cystic and necrotic change/hemangioblastoma/ neuroblastoma on imaging^[2,3,4].

But chordoid meningioma, an atypical meningioma though have conventional imaging picture, is found to be clinically more aggressive with higher rate of recurrence.

We studied clinical presentations, radiological appearances and pathological characteristics of 21

cases of intracranial meningiomas out of total 98 cases of intracranial central nervous system tumors over a period of two and a half years (i.e., September 2015-February 2018). One extremely rare form encountered: that is an intraparenchymal cystic meningioma (21.4%). & Three rare types: one microcystic meningioma, a chordoid meningioma and other is meningioma with schwannoma and Neurofibromatosis 2.

Material and Methods

A prospective review of 21 cases of intracranial meningiomas that are operated in between

September 2015 to February 2018 was undertaken. The clinical details, radiological appearances, operative findings & histopathological details with both routine haematoxylin and eosin and immunostained sections are elaborately studied.

Results

The male:female ratio was 1:1.3 and mean age was 51 years.(25-70years).The chief complaints were headache, hemiparesis, dizziness, seizure and slurring of speech.

Table 1: Age, sex, location and histological type distribution of meningiomas

No.	Histological Subtype	No. Of Cases	Age(years) / Sex	Location
1	Meningothelial	4	70 / Female 62/ Male 45/ Female 58/ Female	Left Frontal Lobe Parasagittal region Frontal Region Sphenoid ridge
2	Chordoid	1	63/ Male	Lt. Temporo parietal region
3	Microcystic	1	45/ Male	Left Frontal lobe
4	Transitional	3	43/ Male 55/ Female 50/ Female	Frontal lobe Parietal lobe Lt Frontal lobe
5	Psammomatous	3	48/Female 51/Male 58/Female	Parasagittal region Front parietal Lobe Frontal lobe
6	Cystic (Transitional)	1	41/Female	Fronto parietal lobe
7	Anaplastic	1	44/Female	Frontal lobe
8	Clear cell	1	54/Female	Parietal lobe
9	Fibrous	2	56/Male 25/Female	Cerebellar cortex Parietal lobe
10	Angiomatous	1	61/Female	Tentorial region
11	Papillary	2	49/Male 62/Male	Supratentorial region Left temporal region
12	NF2 associated Meningioma (Transitional type) and Schwannoma	1	33/Male	Left Frontal and Temporal lobe

Out of total 21 meningiomas 17 cases were the classical histological variants (Fig. 1). There were 3 rare histological forms of meningioma which has been extensively studied along with an extremely rare form of intraparenchymal cystic meningioma which has been elaborately reviewed with the literature.

The sites were in different parts of the extra axial locations as cited (Table 1), except cystic meningioma which was intra axial in location. The mean duration of complain was 1.8 months (2

days-6 months). Preoperatively all were diagnosed as meningioma on imaging (CT/MRI) as per its classical description whereas the cystic type were misdiagnosed as ganglioglioma/DNET.

Illustrative Cases

Case 1

A 50 year old female presented with right hemiparesis for 1 month. In the MRI it was noted as a well defined intra axial complex solid cystic mass lesion in left frontal lobe closely abutting

falx and SGS having enhancing solid component as well as cystic areas within. The lesion was hypointense in T1W and hyperintense in T2W. It measured 6x6x5.5cm. The lesion was having significant mass effect causing contralateral shift to midline of about 2cm, subfalcine herniation and compression of ipsilateral ventricles. There was mild surrounding edema seen as well [Fig. 2].

Operative finding-Left frontal SOL craniotomy and tumour exenteration was done. Greyish white intraaxial soft to firm moderately vascular lesion excised in piece meal and submitted for histopathological study [Fig.3]. Routine histopathology with Hematoxyline and eosin revealed meningothelial cells with complex cystic pattern arranged both in whorls and fascicles which was diagnosed as Transitional meningioma with intra tumoral cysts [Fig 4]. Which showed immunoreactivity towards EMA and PR [Fig. 5].

Case 2

A 63 year old male presented with Right hemiparesis with features of raised intracranial pressure for last 10 days. His CECT brain revealed rim of extradural haemorrhage (1.4cm thickness) noted in left temporoparietal convexity. Edema and gyral swelling in the left temporoparietal lobe with significant mass effect & midline shift, infarct. MRI showed Left temporoparietal convexity Meningioma with perilesional edema, mass effect and midline shift. Operative finding and postoperative follow up revealed Craniotomy with evidence of pneumocephalus/small extradural hematoma and soft tissue edema in left side without any residual enhancing soft mass seen in post CT.

The tumour mass was submitted, which revealed chordoid meningioma (grade 2) in histopathology with features reminiscent of chordomas. Tumor was composed of cords & nests of eosinophilic vacuolated cells with an abundant myxoid matrix and focal areas of typical meningothelial pattern [Fig 6A]. Immunohistochemistry showed EMA and Vimentin positivity. Patient was followed up for next 6months without any recurrence.

Case 3

A 45 year old male presented with tonic clonic seizure attack with mild dizziness within 3 month whose CT showed low density with intense homogenous enhancement in left frontal area and MRI revealed low intensity with solid component & T₂ with very high signal. Craniotomy followed by Histopathological diagnosis was Microcystic variant of meningioma. (Grade 1) [Fig 6B]. This variant is an unusual histological subtype of meningioma & was challenging for its morphology revealing extensive microcyst formation though the clinical and neuro-imaging features were identical with those of meningioma in general. Diagnosis was confirmed by PR & EMA immune positivity.

Case 4

A 33 year old man admitted to the hospital for an attack of generalized seizure with features of NF2 with similar history in other 2 siblings. There was no associated vomiting, visual difficulty. CT-revealed two mass lesions; one at temporal, other one at frontal location of left side. Surgical removal of both the mass lesions & then histopathological diagnosis-revealed Transitional type of meningioma (frontal lobe) & Schwannoma (temporal lobe). Patient being followed of for last 10 months without any neurological deficit.

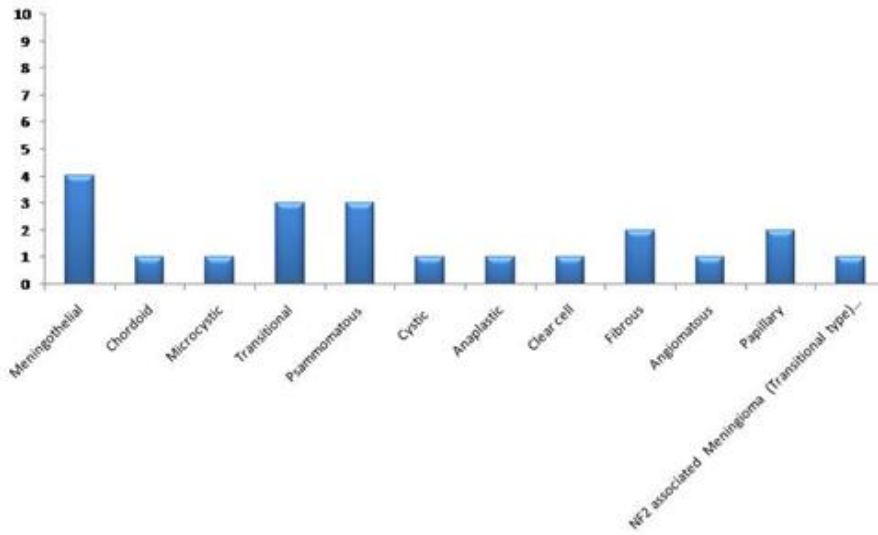


Figure 1: Distribution of Histological types of meningioma cases

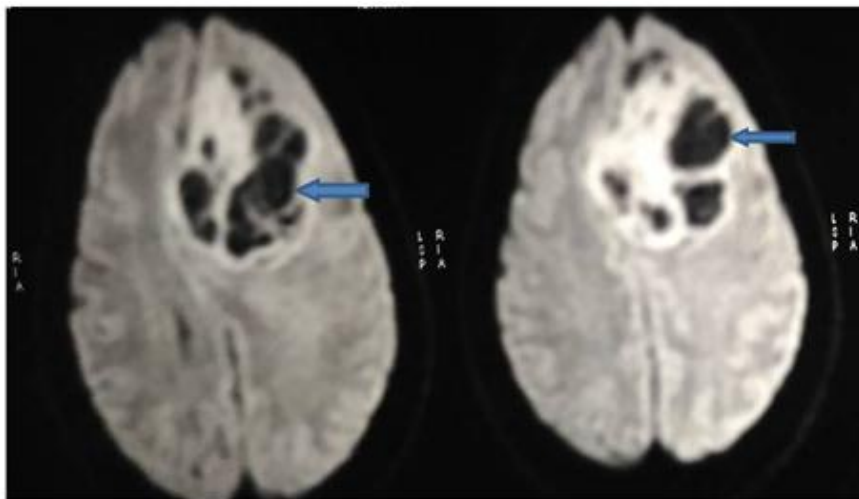


Figure 2: Image of Intraparenchymal cystic meningioma showing cystic structures (Arrow marked) within the brain tissue

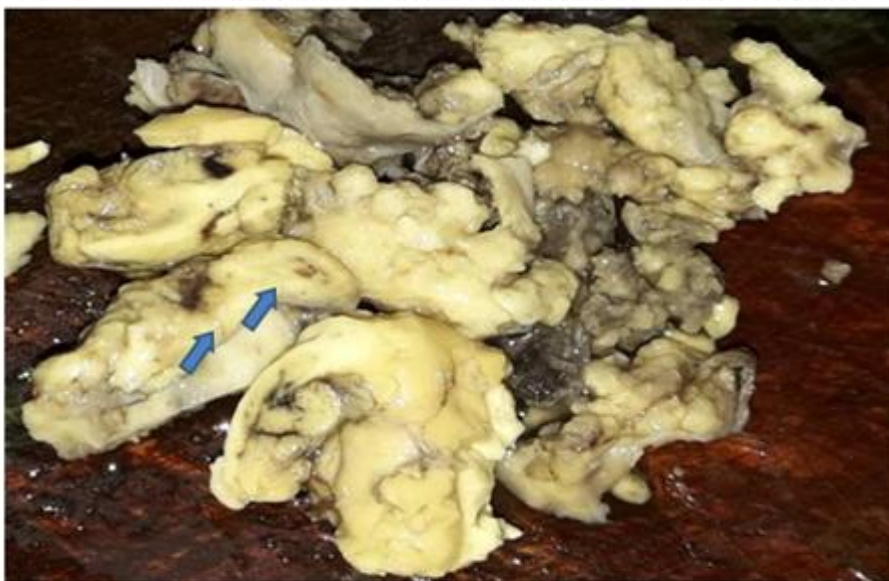

Figure 3: Gross picture of intraparenchymal cystic meningioma showing cystic structures (Arrow marked) within the brain tissue

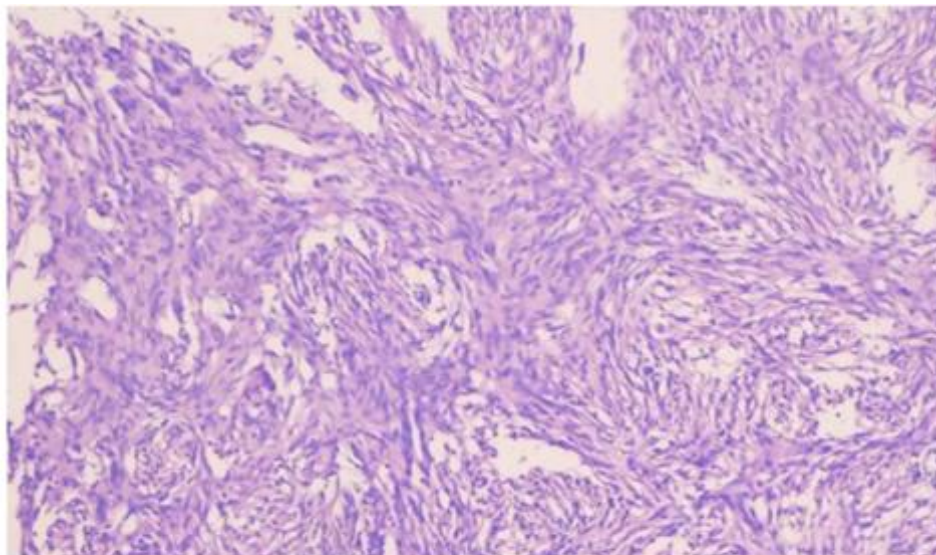


Figure 4: Photomicrograph of Transitional Meningioma (100x, H & E)

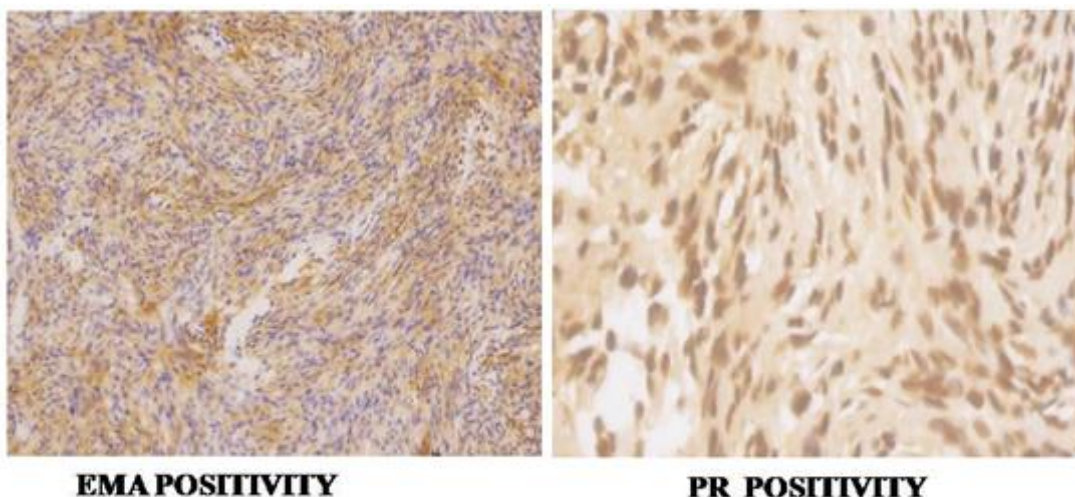


Figure 5: Photomicrograph showing Immunohistochemistry of fibroblastic Meningioma (100x)

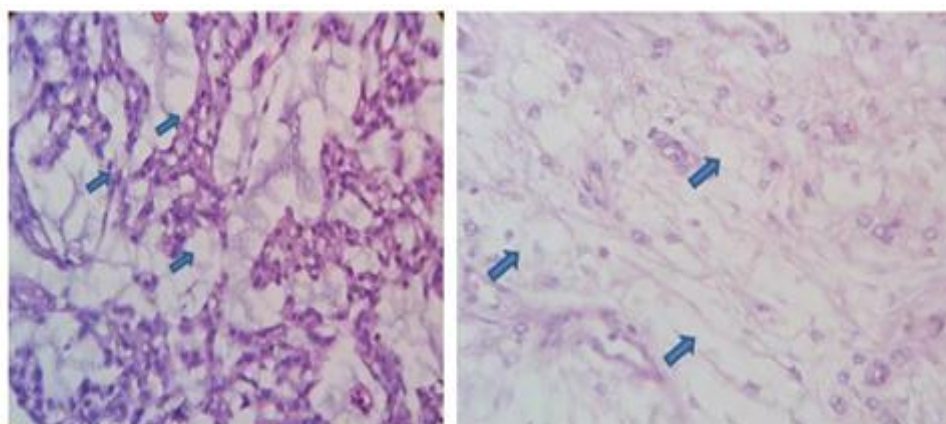


Figure 6: A: Photomicrograph of chordoid Meningioma showing abundant extracellular mucin (arrow marked) (400x, H & E).
 B: Photomicrograph of microcystic Meningioma showing numerous microcysts (arrow marked) with vacuolated cells (400x, H & E)

Discussion

Meningiomas are most common extraaxial neoplasms, accounting approximately 15% of all intracranial tumours^[1]. Affects mostly adults, women almost twice as that of men. Most meningiomas are benign and grow slowly; arise from arachnoidal cells located anywhere in the brain and spinal cord and about half of them arise over the cerebral convexities and one fifth at the sphenoid ridge.

WHO classifies and grades meningiomas into many different subtypes based on histological parameters. Of these subtypes meningothelial, transitional, fibroblastic ones are most common. Some histological types such as papillary, chordoid, rhabdoid and clear cell meningioma have a more aggressive behavior and high recurrence rate.

The etiology of meningioma is not entirely known though these tumours are occasionally seen at locations of prior trauma/radiation^[5]. Genetic alterations, including inherited mutation of NF 2 in the setting of neurofibromatosis type 2 and loss of chromosome 22q in sporadic cases are associated with a higher incidence^[5]. Patients with neurofibromatosis type 2 have an association with increased incidence of other CNS tumours, including schwannoma and ependymomas. Our case 4 a bright example of it.

Meningiomas are uncommonly associated with cysts and their occurrence has been reported at 4-7% of all intracranial meningiomas^[2,3]. However high incidence rate of >10% has been in record in case of children^[2,3]. Cysts are more commonly found in males^[6] and are of peritumoral cyst types whereas females predominates in tumours with intratumoural cysts.

Nauta et al^[7] described four types of cysts associated with meningiomas 1. a centrally located intratumoural cyst that is surrounded by microscopic tumour throughout, 2. A peripherally situated intratumoural cyst, 3. A peritumoral cyst that actually lies within the adjacent brain and 4. Peritumoral cyst at the interface of tumor and brain.

Cysts in meningioma is divided into intratumoural or peritumoural cysts depending on whether the cyst walls are lined by meningothelial cells^[8]. Fortuna et al believe that intratumoural cysts develop due to microcystic degeneration, ischemic necrosis and / haemorrhage in addition to secretory changes within the tumour whereas peritumoural cysts are large, contain xanthochromic fluid with a high protein content and are lined by fibrillary astrocytes and their processes –a glial response to the presence of a meningioma^[9,10]. From surgical point of view the Nauta type 2 cysts are important as neoplastic cells are found in the distal cyst wall. So scrupulous search should be made so as to remove all the neoplastic tissue component to prevent recurrence.

Szilwowski and Cummings studied the chemical nature and enzyme levels of 214 cerebral cysts. The protein concentration from their two meningiomas was within the range for cysts associated with malignant tumours. SGOT and LDH levels tended to be lower in the meningioma cysts and were considered to be non diagnostic^[11].

Our cystic meningioma (case1) though diagnosed histopathologically as Transitional Meningioma with intratumoural cyst its radiological and surgical findings were misleading and mimicked with that of glial tumor hence misdiagnosed preoperatively with a differential of Glioma/DNET. Because of its unusual appearance of no dural attachment, intraparenchymal location, complex solid cystic mass lesion (intratumoural type), it was quite challenging to be diagnosed preoperatively and established the fact that not all meningiomas are dura based.

Conclusion

Meningiomas though easily diagnosed usually by conventional radiological (CT and MRI), operative findings yet some misdiagnosis occurs due to its atypical intraparenchymal location and intracystic lesion. Which is a crucial fact that has to be always kept in mind as a potential surgically curable tumor can be prevented from recurrence

and other pattern of treatment modalities. So the role of pathology is ultimate in establishing a diagnosis by submitting a specimen for histopathological and immunohistochemical study.

Source (s) of support in the form of grants: Nil

Conflict of interest: Nil

References

1. Buetow MP, Buetow PC, Smirniotopoulos JG. Typical, atypical, and misleading features in meningioma. *Radiographics* 1991;11(6):1087- 1106.
2. Chan RC, Thompson GB. Intracranial meningiomas in childhood. *SurgNeurol* 1984; 21: 319-322.
3. Parisi G, Tropea R, Guiffrida S, Lombardo M, Giuffre F. Cystic meningiomas. Report of seven cases. *J Neurosurg* 1986; 64: 35-38.
4. Penfield W. Tumors of the sheaths of the nervous system. In: Penfield W, editor. *Cytology and cellular pathology of the nervous system*, vol. 3. New York: Paul B Hoeber; 1932. 955-90.
5. Riemenschneider MJ, Perry A, Reifenberger G. Histological classification and molecular genetics of meningiomas. *Lancet Neurol* 2006;5(12):1045-1054
6. Guthrie BL, Ebersold MJ, Scheithauer BW. Neoplasms of intra-cranial meninges. In: Youmans JR, ed. *Neurological surgery*, Vol 5, Ed. III. Philadelphia: WB Saunders, 1990:32-53.
7. Nauta HJW, Tucker WS, Horsey WJ, Bilbao JM, Consalves C. Xanthochromic cysts associated with meningiomas. *J Neurol Neurosurg Psychiatry* 1979; 42:529- 535.
8. Rengachari S, Batnitzky S, Kepes JJ, Morantz RA, O'Boynick P, Watanabe I. Cystic lesions associated with intracranial meningiomas. *Neurosurgery* 1979;4:107-10.
9. Fortuna A, Ferante L, Acqui M, Guglielmi G, Mastronardi L. Cystic meningioma. *Acta Neurochirur (Wien)* 1988;90:23-30
10. Odake G. Cystic meningioma: report of three patients. *Neurosurgery* 1992;30:935-40.
11. Szilwowski HB, Cummings JN. Diagnostic value of chemical examination of cerebral cyst fluids. *Brain* 1961;84:202-12.