



## Study of Foreign Bodies in Aerodigestive Tract in Tertiary Care Hospital

Authors

**Nemiwal A<sup>1\*</sup>, Sharma M<sup>2</sup>, Hada M.S.<sup>3</sup>**

<sup>1</sup>Senior Resident, Department of ENT, SMS Medical College and Hospital, Jaipur

<sup>2</sup>Senior Professor, Department of ENT, SMS Medical College and Hospital, Jaipur

<sup>3</sup>Associate Professor, Department of ENT, SMS Medical College and Hospital, Jaipur

\*Corresponding Author

**Nemiwal A**

Senior Resident, Department of ENT, SMS Medical College, Jaipur, India

### Abstract

**Background:** A foreign body is an endogenous or exogenous substance incompatible with the anatomy of the part of body where it is found. In small children the habit of eating while playing can cause the inhalation of foreign body. Accidental ingestion or aspiration tends to be twice as common in boys<sup>1</sup>. Highest incidence is in 1-3 years old (25% less than 1 year) and one of the third leading cause of death worldwide in that age group.<sup>2</sup>

**Material and Methods:** The material is chiefly those patients with foreign body in aerodigestive tract attending ENT OPD/IPD in SMS hospital. Total 60 cases attending opd during June 201 to December 2019 were reviewed. Hematological and radiological investigations conducted on 60 patients. Foreign bodies retrieved from aerodigestive tract under general anaesthesia.

**Result:** Most common age group was 0-10 year, in which <4 years age group most affected. Male to female ratio was 2.3:1. Most common site of foreign body impaction was right main bronchus in airway and cricopharynx in digestive tract. Vegetative foreign bodies more common in airway whereas non vegetative foreign bodies more common in digestive tract.

**Conclusion:** Meticulous history and thorough examination are the key factor for the management. All the impacted foreign bodies should be removed via endoscopy, no foreign body should be left alone that it will come out spontaneously.

**Keywords:** Foreign bodies, Aerodigestive tract, radiology, endoscopy.

### Introduction

A foreign body is an endogenous or exogenous substance incompatible with the anatomy of the part of body where it is found. In small children the habit of eating while playing can cause the inhalation of foreign body. Accidental ingestion or aspiration tends to be twice as common in boys<sup>1</sup>. Highest incidence is in 1-3 years old (25% less than 1 year) and one of the third leading cause of death worldwide in that age group.<sup>2</sup>

The most common item ingested is probably the coin upto 70 % cases. Adults account for only about 20% of the reported cases of aspirations. The leading causes are associated with altered mental status, trauma with a decreased level of consciousness, and impaired airway reflexes, when airway protective mechanisms function inadequately or facial traumas<sup>3</sup>.

Computed tomography, virtual bronchoscopy is highly sensitive in identifying a foreign body within the airway<sup>4</sup>

For oesophageal foreign bodies, the standard PA and lateral radiographs are recommended.

Material and methods: The material is chiefly those patients with foreign body in aerodigestive tract attending ENT OPD/IPD in SMS hospital. Total 60 cases attending OPD/IPD during June 201 to December 2019 were reviewed. All cases of foreign bodies in aerodigestive tract (oesophagus, larynx, trachea and bronchus) are included. In every suspected case of foreign body thoroughly history taking, clinical examination, other relevant haematological and radiological investigation done.

#### Relevant laboratory investigation

Haematological examination: Haemoglobin, HCT, TLC, DLC, total platelet count and coagulation profile were done in all cases.

#### Results

**Table 1:** Distribution of aerodigestive foreign bodies between adults and children

	Airway (29)	Digestive tract (31)
<b>Children</b>	28 (96.6%)	27 (87.1%)
<b>Adults</b>	1 (3.4%)	4 (12.9%)

**Table 2:** Sex distribution

	Airway (29)	Digestive tract (31)	Total (60)
<b>Male</b>	23 (79.3%)	19 (61.3%)	42(70%)
<b>Female</b>	6 (20.7%)	12 (38.7%)	18(30%)

**Table 3:** Radiological findings

	No. of cases	Percentage (%)
<b>X ray (Done in All 60 cases)</b>		
Radio-opacity	31	51.7
Hyperinflation	21	35
Tracheal shifting	16	26.6
Doubtful	7	11.7
<b>HRCT(Performed in 12 cases)</b>		
Radio-opacity/Soft tissue density	12	100
Air trapping	6	50
collapse	1	8.3
Other findings(consolidation/effusion)	2	16.7

Serological marker, blood grouping and typing, LFT, RBS and ECG.

#### Radiography

X-ray neck -AP and lateral view, X-ray chest PA and lateral view and HRCT thorax with virtual bronchoscopy and barium esophagogram (in selected cases) to find out the site of impaction of foreign body and to assess the secondary changes due to the presence of foreign body. Post operative x-ray taken after endoscopic retrieval of foreign body to assess the condition.

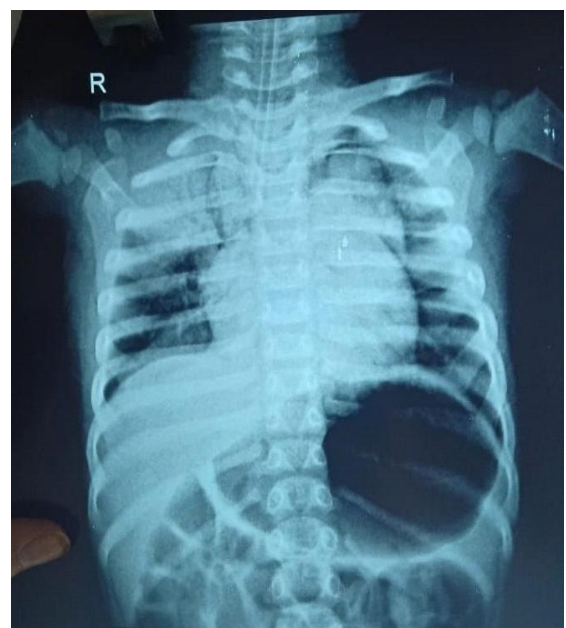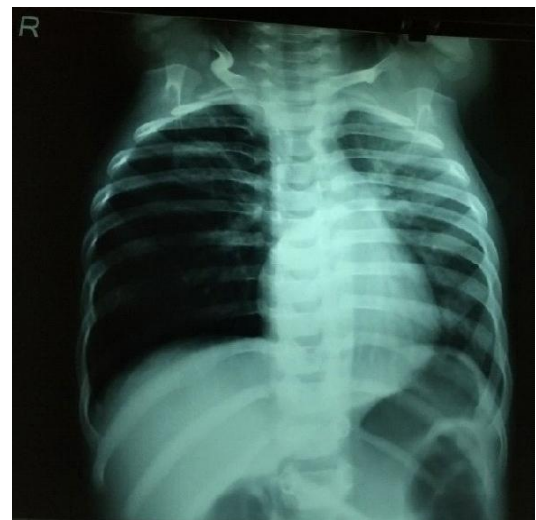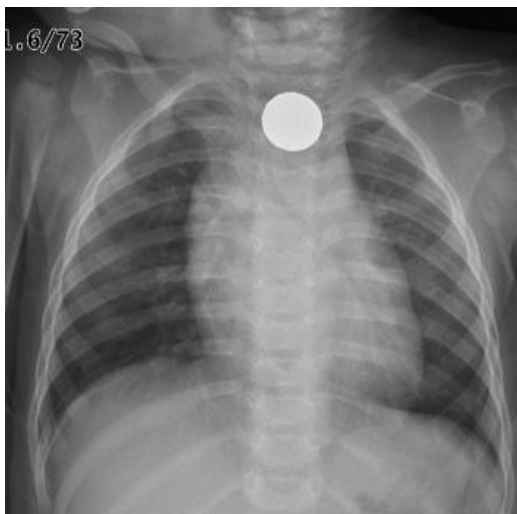
#### Treatment

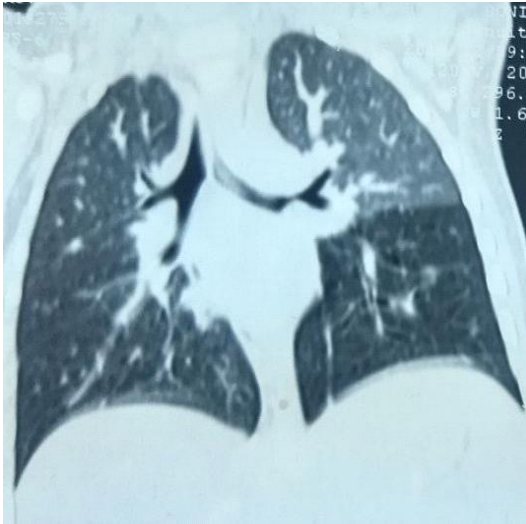Rigid esophagoscopy, rigid bronchoscopy performed under general anaesthesia in clinically and radiologically confirmed or suspected cases. Foreign body retrieval via endoscopes depending upon nature of foreign body, site of lodgement and outcome recorded.

**Table 4:** Site of impaction of foreign bodies

	No. of cases	Percentage (%)
<b><u>Bronchoscopy(26)</u></b>		
Trachea	3	11.5
RMB	12	46.1
LMB	7	26.9
Multiple sites	3	11.5
NO FB	1	3.8
<b><u>Oesophagoscopy(30)</u></b>		
Cricopharynx	19	63.3
Upper oesophagus	1	3.3
Mid oesophagus	2	6.7
Lower oesophagus	6	20
NO FB	2	6.7
<b><u>Direct laryngoscopy(4)</u></b>		
Vocal cord	3	75
PFS	1	25

**Images**





### Discussion

Foreign body inhalation and ingestion occur commonly in children. Children are common victims due to their tendency to put things in their mouth, inability to masticate well and inadequate control of deglutition, as well as the tendency to cry, shout and play during eating. Chavallier Jackson developed modern techniques of endoscopic removal of foreign bodies that reduced the mortality approximately 02% from 20%. Advancement in illumination sources and general anaesthesia, complication rate much reduced, added by quick approach to patient and radiological investigation.

In this observational study 60 cases of foreign bodies in aerodigestive tract studied at ENT Department of SMS medical college Jaipur.

Following were noted in this study:

- 1) There was bimodal peak with one at below 10 year and another was between 51-70 years.
- 2) There was male predominance in our study.
- 3) Most of the foreign bodies in the aerodigestive tract are due to carelessness of the children, their parents and people staying with them, however, the definitive history of foreign body was available in 80% of cases.
- 4) 60% patients belongs to the rural areas.
- 5) Right main bronchus was most common site of airway foreign body impaction.( 46.1%)

and cricopharynx found to be site of impaction in 63.3% of cases of digestive tract foreign body.

- 6) Most of the foreign bodies of digestive tract found to be non vegetative origin out of which coin found in 56.7 % cases.

These findings were similar to the observation by the **Debabrata et al (2017)<sup>5</sup>** and **Dr. Kiran Ravindranath Bongale (2017)<sup>6</sup>** study.

**Management:** Rigid bronchoscopy and Oesophagoscopy performed under general anesthesia in clinically and radiologically confirmed or suspected cases. Foreign body retrieval via endoscopes depending upon nature of foreign body, site of lodgement and outcome recorded. The size of bronchoscope and oesophagoscope chosen depending on the age of the patient. After removing the foreign body entire tracheobronchial tree, Oesophagus re-examined for any remains of foreign body or another foreign body.

### Conclusion

It was observed in our study that foreign body in digestive tract found more common than respiratory tract with higher incidence in rural population. Male to female ratio was 2.3:1. Most common site of impaction of foreign bodies in airway was right main bronchus and in digestive tract was cricopharynx. Vegetative foreign bodies more common in airway whereas non-vegetative foreign bodies are more common in digestive tract. Coin was most common type of foreign body retrieved from digestive tract whereas groundnut found more commonly in foreign body. Airway foreign body associated with high incidence of morbidity and mortality compare to digestive tract. Meticulous history and thorough examination are the key factor for the management. All the impacted foreign bodies should be removed via endoscopy, no foreign body should be left alone that it will come out spontaneously.

**References**

1. T. George and R. Andrew, "Update on foreign bodies in the esophagus: diagnosis and management", *Current Gastroenterology Reports*, vol. 15, article 317, 2013
2. Lauren D Holinger, Sheri A. Poznanovic. *Cummings Otorhinolaryngology and Head and Neck surgery*, 5<sup>th</sup> edition, Philadelphia, Elsevier Mosby, 3:2935-2943
3. N. Al-Sarraf, H. Jamal-Eddine, F. Khaja, and A. K. Ayed, "Headscarf pin tracheobronchial aspiration: a distinct clinical entity," *Interactive Cardiovascular and Thoracic Surgery*, vol. 9, no. 2, pp. 187–190, 2009
4. Bhat KV, Hegde JS, Nagalotimath US, Patil GC. Evaluation of computed tomography virtual bronchoscopy in paediatric tracheobronchial foreign body aspiration *J Laryngol Otol* 2010; 124: 875–9
5. Debabrata Das, Tanmoy Maitra, Ashis Kumar Ghosh, Jayanta Saha. Management of Aerodigestive Tract Foreign Bodies In A Rural Based Tertiary Care Hospital: An Experience of Two Years. *IOSR Journal of Dental and Medical Sciences (IOSR-JDMS)*. e-ISSN: 2279-0853, p-ISSN: 2279-0861. Volume 16, Issue 10 Ver. X (Oct. 2017), pp 01-07
6. Dr. Kiran Ravindranath Bongale. Foreign Bodies in Aerodigestive Tract. DOI: 10.21276/sjams.2017.5.3.84.