



Functional Outcome of Uncemented Total Hip Arthroplasty in Osteoarthritis

Authors

Dr Sudhir Ravindran¹, Dr Vishnu.S²

¹Associate Professor, Department of Orthopedics, Medical College Trivandrum

²Senior Resident, Department of orthopaedics, Medical College Trivandrum

Background

Total hip replacement is most commonly surgical procedure used to treat joint abnormality due to osteoarthritis and other disorders affecting function of the hip joint.

The best mode of implant fixation in primary total hip replacement (THR) has been a source of debate. Cemented implants achieve stability from cement-bone mechanical interlock, once the polymethylmethacrylate has set, whereas cementless fixation relies on primary press fit stability with long term stability occurring secondary to endosteal microfractures at the time of preparation and subsequent bone on growth or in growth. The optimum fixation choice should be guided by patient-based outcomes, in particular the implant survivorship.

The adverse effects of bone cement led to the popularity of uncemented total hip arthroplasty. Here porous and hydroxy apatite coated components are used. This creates a biological interface called bone ingrowth (osteointegration). Instead of fatiguing and failing of bone cement, this type of fixation continually grows stronger, remodelled and becomes more permanent. The three criteria for bone ingrowth are pores > 40mm in diameter, absence of micromotion, intimacy of porous surface with bone. This study here is to analyze the functional outcome of uncemented THR.

Aim of Study: To study the functional outcome of uncemented total hip arthroplasty.

Background

Total hip replacement has been termed as “Operation of Century” as it has revolutionized the treatment of patients with advanced hip disorders⁽¹⁾. The history of hip arthroplasty can be traced back to early 1800’s^(2,3) when resection arthroplasty was described.

Total Hip Arthroplasty

The origin of total hip arthroplasty dates back to 1890, when Gluck⁽⁶⁾ in Germany reported first total hip replacement with ivory femoral and acetabular components cemented to bone. Sir John Charnley⁽¹⁴⁻¹⁶⁾ is credited as the “Father of total

hip arthroplasty” for ushering the era of modern hip arthroplasty. He introduced the concept of ‘low friction torque arthroplasty’ and ‘self-curing acrylic cement’.

Osteoarthritis of Hip Joint

The hip joint, including the small joints of the hand and the knee, is one of the most commonly affected joints with osteoarthritis (OA) clinically, hip OA is characterized by fluctuating pain, crepitation, and decreased range of motion, which results with walking disability of the patient and are generally associated with some particular radiological changes of the hip joint. The

diagnosis of hip osteoarthritis is made on the basis of medical history, clinical presentation, physical examination, as well as basic and (if necessary) additional diagnostic imaging techniques. The most commonly used clinical criteria for the diagnosis of hip OA are the criteria of the American College of Rheumatology for the diagnosis and classification of hip OA.

Clinical criteria for the diagnosis of hip osteoarthritis (OA)

Table 1

Traditional criteria
Hip pain in the presence of one of the following criteria: – ESR <20mm/hour – radiographic femoral or acetabular osteophytes – radiographic JSN (superior, axial, and/or medial)
The criteria according to the classification tree
Hip pain and radiographic femoral and/or acetabular osteophytes or Hip pain with radiographic axial JSN and ESR \leq 20mm/hour

ESR – Erythrocyte sedimentation rate;

JSN – Joint space narrowing

The most common classification for hip arthritis used in literature is that of the Subcommittee on Classification Criteria of Osteoarthritis, a subcommittee of the Diagnostic and Therapeutic Criteria Committee of the American Rheumatism Association from 1986 (26). OA can be divided into primary and secondary. Primary OA is a disease of unknown etiology (but with pro-inflammatory character), which occurs in the elderly. Secondary OA occurs predominantly at a younger age, and it is usually a consequence of other diseases or conditions with a known cause such as developmental disorders, trauma, or the like, which leads to the process also characterized by the appearance of inflammatory mediators.

Biomechanics of total Hip Arthroplasty

In total hip arthroplasty the components must withstand many years of cyclical loading at least 3 to 5 times the body weight and at times subjected to 10-12 times the body weight.

Forces acting on the Hip

The lever arm of body weight extends from the body's centre of gravity to the centre of femoral

head. The abductor musculature acting on a lever arm extending from the lateral aspect of greater trochanter to the centre of femoral head must exert an equal moment to hold the pelvis level when in a one-legged stance

The forces on the joint act not only in the coronal plane, but because the body's centre of gravity (in the midline anterior to S₂) is posterior to the axis of the joint, they also act in the sagittal plane to bend the stem posteriorly. The forces acting in this direction are increased when the loaded hip is flexed as when arising from the chair, ascending and descending stair case. During stair climbing and straight leg raising, the resultant force causes posterior deflection or retroversion of the femoral stem.

Rotational Stability

Increasing the width of proximal stem to better fill the metaphysis increases the torsional stability of the stem when it is implanted without cement.

Centralisation of Head

An integral part of Charnley's concept of total hip arthroplasty was to shorten the lever arm of body weight by deepening the acetabulum (centralization of femoral head) and to lengthen the lever arm of abductor mechanism by reattaching the osteotomized greater trochanter laterally. Thus, the moment produced by the body weight is decreased.

Neck Length and Offsets

The normal centre of rotation of femoral head is determined by three factors:

Vertical height (vertical offset)-of femoral head is measured as the distance to the centre of femoral head from a fixed point such as the lesser trochanter. Restoring this distance is essential to correct leg length discrepancy.

Medical or Horizontal offset or simply offset is the distance from the centre of femoral head to a line through the axis of the distal part of the stem.

Vertical height and offset both increase as the neck is lengthened and proper reconstruction of

both features is the goal when selecting the length of femoral neck.

Version – refers to orientation of neck in reference to the coronal plane. Normal femur has 10-15° of anteversion of neck in relation to the coronal plane. Retroversion can result in posterior dislocation especially when posterior approach has been used. Similarly, excessive anteversion of the neck can result in anterior dislocation.

Design and Selection of Implants

Basically 4 parameters are used in deciding if an uncemented or cemented stem is to be implanted. Each parameter is allotted a point scale. The total points for the patient concerned, produce a value which can be used to determine appropriate implantation. The parameters are as follows:

1. Sex

The loss of bone substance which begins around the age of 40 years is higher among females. Later it is increased by hormonal changes which is typical of menopause.

2. Age

Before the age of 60 years an uncemented prosthesis is indicated in all cases. This will allow easy removal of the implant if revision be required later. For patients over the age of 70 years, cemented stem is usually indicated.

3. Singh's Index

It is based on the changes in the trabecular pattern of the upper end of femur which is used as an index of osteoporosis.

Stage 7 denotes normal femur

Stage 6 & 5 reveal slight osteoporosis

Stage 4 & 3 indicate advanced osteoporosis and uncemented stem is indicated only in young male patients.

Stage 2 & 1 are absolute contraindication for an uncemented stem.

4. Morphological cortical index

It is based on 2 variables

- Morphology — shape of femur — femora can be divided into 3 categories morphologically into trumpet shape, cylindrical and dysplastic. Due to its form the trumpet shaped femur is ideal for cementless implantation.
- Morphological cortical index — it consists of ratio of 2 sizes which can be measured on a standard AP X-ray of the femur.

$$MCI = \frac{CD}{AB}$$

CD - Distance between the outer limit of lateral and medial cortical layers measured at the greatest prominence of lesser trochanter and vertically to the longitudinal axis of femur.

AB - Diameter of the medullary canal 7 cm distal to CD line.

Evaluation of Points

Table 2

SEX	POINTS	AGE	POINTS	SINGH'S INDEX	POINTS	MCI	POINTS
Male	0	< 50	0	7	0	>3	0
Female	1	50 - 60	1	6-5	1	3-2.7	1
		61 - 70	2	4-3	2	2.6-2.3	2
		> 70	4	2-1	4	<2.3	4

Table 3: Parameters used for selection of implants

TOTAL	
0-4	Uncemented
5	Possible
≥ 6	Cemented

Cementless Acetabular Components

In an attempt to increase longevity and lessen the incidence of aseptic loosening, cementless cups were introduced. The following types have been described:

Press Fit Cups

There are no pure press fit cups. Some additional fixation form is always present. Mathys hemispherical cups are such examples which have two plastic pegs superiorly that are driven into predrilled holes. Two metal screws through the rim of the cup are used for supplementary fixation. Spitorno cup is a metal backed press fit cup that has flexible metal spiked ribs that are driven into host bone. Spiked cups have also been

described in which spikes vary from small rounded spikes to huge pagoda like structures.

Threaded Cups

The threaded cups of Mittlemeir and Lord have been used in Europe with quite acceptable results. Threaded cups can be divided into three broad groups:

Truncated cones: Conical implant with a flat base, e.g. Lord prosthesis

Threaded ring: Threaded hemispherical ring with a large apical hole, e.g. Mecron ring

Hemispherical shells: Majority have conical threads.

A search for additional fixation led to the development of hybrid, threaded porous cups, where threads provide initial fixation and later, bony ingrowth on porous surface provides long term stability.

Cementless Femoral Stems

Press Fit Stems

R Judet is credited for the development of first press fit total hip replacement. These stems can be calcar support or wedge fit. Moore implant is an example of calcar support press fit stem. Usually all other stems are wedge fit stems. If a collared stem is used and the collar makes contact with calcar, before the stem becomes wedge fit, implant would not be stable. On the other hand, if stem becomes wedge fit before the collar touches calcar, collar is of no use. These implants can be either metaphyseal fit

Macro Interlock Fixation

In these stems, press fit is supplemented by some mechanical interlocking. Various designs to achieve this interlocking have been described, e.g. steps, ribs, threads, dimples, flutes, wings.

Metal Coatings (bioinert and bioactive)

In growth is the formation of bone inside a porous surface whereas on growth refers to bone growth over a roughened surface. The surface characteristics and coatings over an implant

decide whether in growth or on growth would occur. For bone in growth to occur, the pore size needs to be between 50-100 μm

The cementless stems have been classified into 4 categories based on the geometry and fixation into by Berry et al⁽³⁶⁾. Khanuja et al⁽³⁷⁾ further modified these categories into 6 types based on shape, amount of osseous contact and the progression of stem fixation from proximal to distal. Type 1-3 are tapered stems designed to have proximal fixation. Type 4 is fully coated to obtain distal fixation. Type 5 is a modular prosthesis whereas type 6 stems are curved anatomic designs

Fixation of Cementless Implants

The success of uncemented total hip arthroplasty depends on biological fixation. Stable immediate (primary) fixation is a requirement for success such that secondary fixation via bone growth can occur. The bone growth occurs due to the direct formation of woven bone without cartilaginous intermediary and there is lamellar bone remodelling around the implant that contributes to bone in growth.

Engl and Bobyn proposed a simple classification for implant fixation based on roentgenographic inspection. Fixation is classified as

1. Fixation by bone in growth is defined as an implant with no subsidence and minimal or no radiopaque line formation around the stem. Cortical hypertrophy may be present at the distal end of porous surface and "spot welds" may be evident between the stem and periosteum. Varying degrees of proximal stress shielding are present.

2. Fixation by stable fibrous in growth: Here no progressive migration of the implant occurs but an extensive radiopaque lines from around the stem. These lines surround the stem in a parallel fashion and are separated from the stem by a radiolucent zone upto 1mm wide. The femoral cortex shows no signs of local hypertrophy suggesting uniform load carrying function.

3. An unstable implant: is defined as one with either progressive subsidence or migration within the canal and is at least partially surrounded by

divergent radiopaque lines that are more widely separated from the stem at its extremities. Increased cortical density typically occurs beneath the collar and at the end of the stem indicating lack of uniform stress transfer

Methods

Study Design: Prospective study

Study Setting: Government Medical College Thiruvananthapuram.

Study Population: Patients with osteoarthritis undergoing uncemented THR in Government Medical College Thiruvananthapuram.

Study Duration: One year

Study Subjects

Inclusion Criteria

- Patients undergoing Uncemented THR for osteoarthritis in MCH Thiruvananthapuram
- Age < 70

Exclusion Criteria

- Patients undergoing cemented THR
- Age > 70
- Patients not giving consent

Sampling Method

No sampling will be done as consecutive cases meeting eligibility criteria will be included in the study.

Sampling Technique

Patients admitted with primary osteoarthritis and undergone uncemented THR Govt medical college, Trivandrum in consecutive order.

Variables

1. Sociodemographic variables.
2. Side of hip presented with arthritis.
3. Pre-operative and Postoperative Harris hip scores.

Data Collection

- All patients with osteoarthritis and undergoing uncemented THR was seen during pre-operative period, clinical history and clinical examination was done.
- Relevant investigations done including blood investigations, X-ray pelvis ap view, CT

pelvis in relevant cases. Anaesthetic check up and assessment for fitness for surgery.

- Hip score using modified Harris hip scoring system.
- Counselling the patient regarding the disease, regarding the procedure, the expected outcome, possible complications.
- Consent of patient for the procedure.
- Further assessment by follow up by modified Harris hip scoring.

After obtaining the institutional Research committee and Ethics Committee approval for the study, 20 patients posted for uncemented THR for osteoarthritis were selected. Only those patients who satisfied the inclusion criteria were considered for the study. A valid written consent was taken from each patient. All patients underwent a thorough pre-anaesthetic check-up. A detailed history and physical examination of the patient was performed along with all relevant investigations which includes haemoglobin, total WBC count, differential count, platelet count, renal function tests, serum electrolytes, chest X-ray, ECG, viral markers and LFT. Pre-op Harris score is taken.

All patients were kept nil per oral for at least 8 hours. Pre-op antibiotic cefoperazone + sulbactam were given. Cases were done under epidural anaesthesia all were catheterized.

Posterior approach or a lateral approach was done. Incision applied, fascia divided, muscles retracted and divided. Capsule divided, limb externally rotated traction applied and head dislocated. Head and neck removed, femoral canal reaming done. Acetabulum identified and reaming done. Correct size femoral head prosthesis applied, acetabular cup introduced and screws applied. Head relocated, all movements checked, incision closed in layers after putting a suction drain.

Post operatively antibiotics were continued for 10 days (iv for 5 days and then oral for another 5 days). Suction drain was removed on day 2 and dressings changed on third day. Sutures are removed after wound healing on tenth or twelfth day. On the first or second postoperative day

patient can sit on the side of the bed or in a chair in a semirecumbant position. Gait training was started on 1st post-operative day. On the 3rd post-operative day patient is encouraged to walk with walker. 1st follow-up examination is 6weeks after surgery where another hip score assessment is done. Further follow-up at 3months, 6 months were done.

The result of treatment was assessed by noting the preoperative and post-operative Harris hip score. Data collected was entered into excel sheet and analysed with the help of SPSS-18 software

Modified Harris Hip Score has the following components:

- a. Pain – (44 Points Maximum)
- b. Gait (walking maximum distance) (33 points maximum)
- c. Functional Activity (14 points maximum)
- d. Absence of deformity (4 points maximum)
- e. 5. Range of motion (5 points maximum)

Total – 100 points.

The Harris Hip score is graded as follows:

< 70 – Poor

70-79 – fair

80 – 90 – good

90-100 – Excellent

Results

Total number of 20 cases were taken for the study.

Age Incidence

The mean age of patients in this study was 46 years (+/_8.3), the oldest patient being 60 years and the youngest patient was 33 years old.

Table 4: Percentage distribution of sample according to age

Age in years	Frequency	Percent
<= 40	6	30.0
41 - 50	7	35.0
51+	7	35.0
Total	20	100.0

Sex incidence

12 patients in this study were males and 8 were females

Table 5: Percentage distribution of sample according to sex

SEX	Frequency	Percent
Male	12	60.0
Female	8	40.0
Total	20	100.0

Side of lesion

9 of the hips involved were right and 11 involved were left

Table 6: Percentage distribution of sample according to side

SIDE	Frequency	Percent
Right	9	45.0
Left	11	55.0
Total	20	100.0

Etiology

10 patients were having c/c osteoarthritis and was the most common cause. Second most common was AVN

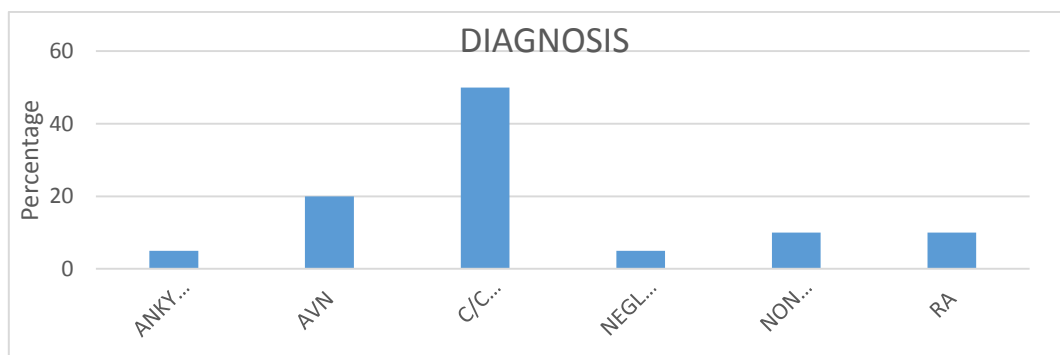


Figure 12: Percentage Distribution of Sample according to Etiology

Analysis of Complications

Majority of the patients did not show any complications undergoing uncemented THR. 2 patients had complaints of DVT. 1 patient developed anterior thigh pain and another patient had sciatic nerve palsy

Statistical analysis of functional outcome based on Harris hip score

Based on pre-op Harris hip score all the 20 hips were found to have poor score (<70). Postoperatively 5 hips showed excellent scores (>90), 8 hips showed good scores (81-90), 6 hips showed fair scores (71-80) and only 1 postoperative hip had shown poor score (<70)

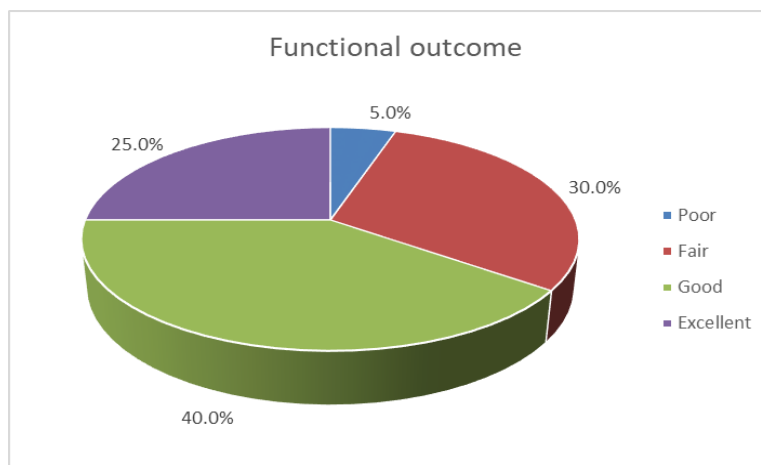


Figure 14: Distribution of Harris hip score

The hips under this study has shown an overall improvement in the Harris hip score as the mean scores have improved from 44.5 to postoperative

values of 83. The p value obtained was less than 0.0001

Table 10: Evaluation of Harris hip score

HIP Score	Pre - OP	Post OP
N	20	20
Minimum	32	69
25 % Percentile	37.25	78
Median	46	84
75 % Percentile	49.5	89.5
Maximum	55	95
Mean	44.5	83
Std. Deviation	6.894	7.305

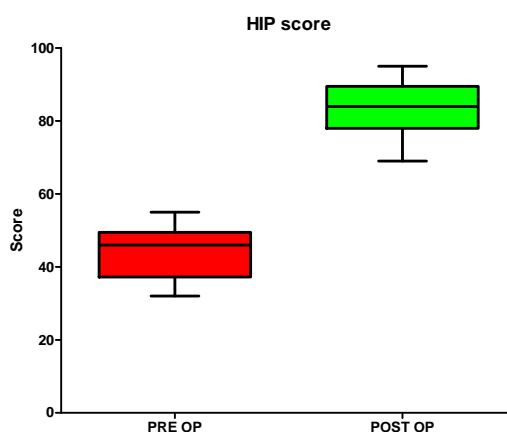


Figure 15: Range of distribution of Harris hip score

One patient above 50 years showed poor outcome post operatively. None of the other age groups were showing poor outcome post operatively

Table 11: Functional outcome with relation to age

Age in years	FUNCTIONAL OUTCOME				Total
	Poor	Fair	Good	Excellent	
< = 40	0	3	2	1	6
41 - 50	0	1	4	2	7
51+	1	2	2	2	7
Total	1	6	8	5	20

Discussion

Uncemented Total hip arthroplasty has a definitive role in the management of chronic arthritis of young patients. In our study the mean age was 46 years, the youngest patient being 33 years old and the oldest being 60 years old. Seven patients were of the age group 41-50 and another seven in the age group 51-60. The mean age group in other studies were Schramm et al⁽⁵¹⁾ 47 years and Peter Aldinger et al⁽⁵²⁾ 51 years.

The sex distribution in our study was males 60 % and females 40% which were similar to other western studies. Schramm et al⁽⁵¹⁾ had 56 % males and 44 % females and Alexander et al⁽⁵³⁾ had 61 % males and 39 % females. The study suggested that the incidence of osteoarthritis due to various causes is more in males than in females, in contrary to other studies showing the incidence of osteoarthritis is more in females than in males. The reverse scenario seen here may be due to the relative less number of female patients opting for treatment.

The most common indication for uncemented THR in our study was chronic osteoarthritis 50 % followed by avascular necrosis 20 %, non-union fracture neck of femur and rheumatoid arthritis 10 %. In Alexander et al⁽⁵³⁾ study most common indication was chronic arthritis – 89%. The other indications were AVN head of femur 8.7 % and Fracture neck of femur 0.5%. This study showed data that was similar to other studies showing that chronic osteoarthritis is the most common indication for uncemented osteoarthritis because of the relatively good amount of bone stalk there is no need for cementing the implants. AVN is

seen in young adults who are mostly initially managed by core decompression and bone grafting and if there is no improvement or further progression of the disease as suggested by MRI then uncemented THR becomes the treatment of choice. The quality of life is very much increased because of this surgery as shown by the post-operative Harris hip scores.

The immediate success of Total hip arthroplasty is determined by the ability of the patient to return to maximum possible level of functional activity. Thus, maximum points are given to pain and mobility of patients. Patients with chronic arthritis are incapacitated by pain and restricted motion and thus the relief of these two factors greatly determines the satisfactory outcome of the surgery. We believed that maintaining considerable activity is important for bone remodelling and osteo integration. Only those activities that do not produce considerable joint load such as swimming, cycling and walking are recommended. The activities that increase the joint load are cross legged sitting, squatting for toilet purposes and any strenuous physical activity. Restoration of the biomechanics of the hip is important for the good outcome and longevity of the prosthesis. In all our cases we tried to restore the centre of rotation, limb length, medial and vertical offset the reason for some of the failures in our study is the noncompliance of the patient with respect to post-operative counselling.

The most common complication associated with uncemented THR in our study was deep vein thrombosis 10 %. Causes can be many from patient in compliance to physiotherapy to delay in starting DVT prophylaxis to various other patient factors. In the work of Alexander et al⁽⁵³⁾ the incidence of DVT was only 1 %. This suggested that DVT was a preventable complication of this surgery.

Other complications include anterior thigh pain 5% and sciatic nerve palsy 5 %. Pain following Total hip arthroplasty confined to thigh indicates loosening of femoral component and pain in the

hip indicates loosening of acetabular component. The incidence of anterior thigh pain in study of Schramm et al⁽⁵¹⁾ was 17 %. Loosening of femoral component is due to improper stem size due to inadequate templating or due to the poor quality of bone. Sciatic nerve palsy occurred in the case where a posterior Moore's approach was taken for the procedure. In the study of Alexander et al⁽⁵³⁾ only 1 % sciatic nerve palsy occurred. There lateral or anterior approach was mainly used. In the posterior approach sciatic nerve is near the field of surgery, so the chance for nerve injury is very high. Selecting the appropriate techniques and careful dissection can prevent such complications. The limitation of the study was further following up in long duration was not possible, so the long-term effects of uncemented THR was not possible to be studied.

Conclusions

The present study shows that functional outcome of uncemented THR in osteoarthritis is functionally significant ($p < 0.0001$) as evident by the pre and post-operative Harris hip score. Uncemented Total hip arthroplasty is mainly indicated in young patients with adequate bone stock. Careful patient selection along with preop and postop evaluation of both patients and radiographs is essential for the success of total hip arthroplasty. Failure of the patients to follow post op instructions regarding life style changes is one of the reasons for fair to poor results in our study. In our study the results are fair to poor in non-compliant young patients with high functional demands. The results are far better in young patients with low functional demands. The complications like pneumonia, fatal pulmonary embolism, Periprosthetic femoral stem fracture etc., were not seen in our study. Few complications like deep vein thrombosis sciatic nerve palsy were seen.

References

1. Learmonth DI, Young C, Rorabeck C. The operation of the century: total hip

- replacement. *The Lancet* 2007; 370:1508-19.
2. Pettier LF. A history of hip surgery. In Callgan JJ, Rosenberg AG, Rubash HE (Eds). *The Adult hip*. Philadelphia Lippincott-Raven 1998. pp.3-36.
3. Shands AR. Fundamentals in hip surgery. In Tronzo RG (Ed). *Surgery of the hip*. 2nd edition. New York. Springer-Verlag 1984. pp.1-26.
4. White A. Obituary. *Lancet* 1849; 1:324
5. Thompson FR. An essay on the development of arthroplasty of hip. *Clin Orthop* 1966; 44:73-82.
6. Bhan S, Pankaj A. History and evolution of hip arthroplasty. Bhan S, Malhotra R (Ed). *Key Issues in Hip Arthroplasty*. New Delhi. Mediworld publications 2007. pp.4-10.
7. Smith Peterson MN. Evolution of mould arthroplasty of the hip joint. *J Bone Joint Surg* 1948;30B:59-73.
8. Townley CO. Hemi and total articular replacement arthroplasty of the hip with the fixed femoral cup. *Orthop Clin North Am* 1982; 13:242-77.
9. Steinberg ME. Evolution and development of surface replacement arthroplasty. *Orthop Clin NorthAm* 1982; 13:661-2.
10. Steinberg ME. Summary and conclusions. *Orthop Clin North AM* 1982; 13:895-902.
11. Moore AT, Boklman Hr. Metal hip joint, a case report. *J Bone Joint Surg* 1943; 25:688-92.
12. Moore AT. The self-locking metal hip prosthesis. *J Bone Joint Surg* 1947;39A: 811-27
13. Thompson FR. Two and a half years' experience with a vitallium intramedullary hip prosthesis. *J Bone Joint Surg* 1954. pp.489-502.
14. Charnley J. Total hip replacement by low friction arthroplasty. *Clin Orthop* 1970; 72:7-21.

15. Charnley J. Total prosthetic replacement of the hip. *Triangle* 1968; 8:211
16. Charnley J. Sub specialization or supra specialization in surgery? *Br Med J* 1970; 2:719.
17. *Thieme Atlas of Anatomy* (2006), p 378
18. *Faller* (2004), pp 174-175
19. Lequesne, M (2004). "The normal hip joint space: variations in width, shape, and architecture on 223 pelvic radiographs". *Annals of the Rheumatic Diseases*. 63 (9): 1145-1151
20. *Platzer* 2004, pp. 198
21. *Platzer* 2004, pp. 200
22. *Thieme Atlas of Anatomy* (2006), pp 383, 440,
23. National Institute for Health and Care Excellence (NICE). Osteoarthritis: Care and management in adults. [Internet] Available from: <http://www.nice.org.uk/guidance/cg177/apter/introduction>
24. JOTANOVIC Z, MIHELIC R, SESTAN B, DEMBIC Z 2012 Role of interleukin-1 inhibitors in osteoarthritis: an evidence-based review. *Drugs Aging* 29(5): 343-58
ALTMAN R, ALARCON G, APPELROUTH D, BLOCH D, BORENSTEIN D, BRANDT K et al. 1991 The American College of Rheumatology criteria.