



Evaluation of Cervical Lymphadenopathies with the Help of Aspiration Cytology: A One Year Study

Authors

Dr Varsha Argal, Prof. Dr Ashok Panchonia, Dr Manish Panth, Dr Smita Doharey

MGM Medical College Indore, MP, India

*Corresponding Author

Prof. Dr Meena Mittal

Abstract

Introduction: *Fine needle aspiration cytology is the easy and affordable method for diagnosis of cervical lymphadenopathies. In developing countries such as India, it plays a significant role as it is an inexpensive, easy to perform procedure, and has almost no complication.*

Aims & Objective: *To diagnose various cervical lymph nodes with the help of fine needle aspiration cytology.*

Material & Method: *A one year study was conducted in the cytopathology section of Department of Pathology. Lymph nodes were examined clinically and then aspirated and after routine cytological staining cases are evaluated.*

Result: *Out of 235 cases 183 were tubercular, 32 reactive hyperplasia of lymph node/ inflammatory and 16 were metastatic and 1 of lymphoma and 03 were hemorrhagic.*

Conclusion: *FNAC is a useful and reliable diagnostic tool that also appears to be a safe and minimally invasive procedure that provides preoperative information for the appropriate management.*

Keywords: *FNAC, Lymphadenopathy, TB.*

Introduction

Fine-needle aspiration cytology (FNAC) in lymph node enlargements is a simple and an important diagnostic tool.^[1] It is first-line investigation for significantly enlarged lymph nodes.^[2] In developing countries such as India, it plays a significant role because it is an inexpensive and easy to perform procedure with almost no complications.^[1]

Enlarged and generally asymptomatic lymph nodes often occur in the head and neck or inguinal areas and are common in clinical practice. Cervical Lymphadenopathy is defined as cervical

nodal tissue measuring more than 1 cm in diameter. It may be due to infection or malignancy^[3]. It is classified into acute lymphadenopathy (2 weeks duration), subacute lymphadenopathy (2-6 weeks duration), and chronic lymphadenopathy is considered in any lymphadenopathy that does not resolve by 6 weeks^[4]. Fine needle aspiration cytology is a cheap and accurate first line investigation in lymphadenopathy^[5].

Aims & Objective

To diagnose various cervical lymph nodes with the help of fine needle aspiration cytology.

Material & Methods

A one year study was conducted in the cytopathology section of Department of Pathology MGM Medical College Indore. Detailed clinical history was evaluated. After proper clinical assessment aspiration cytology was performed. Smears were stained with routine cytology stain and proper microscopic examination was done.

Inclusion Criteria– cases with enlarged cervical lymph nodes

Exclusion Criteria– other sites lymphadenopathy.

Before performing the procedure written consent was taken from patient along with USG details.

Result and Observation

TABLE NO. 1 Distribution of FNAC diagnosis of cervical lymphadenopathies:

FNAC DIAGNOSIS	NO. OF CASES
TUBERCULAR LYMPHADINITIS	183
REACTIVE HYPERPLASIA OF LYMPH NODE/ INFLAMMATORY LESIONS	32
NEOPLASTIC/METASTATIC	16
LYMPHOMA	1
HEMORRHAGIC	3
TOTAL	235

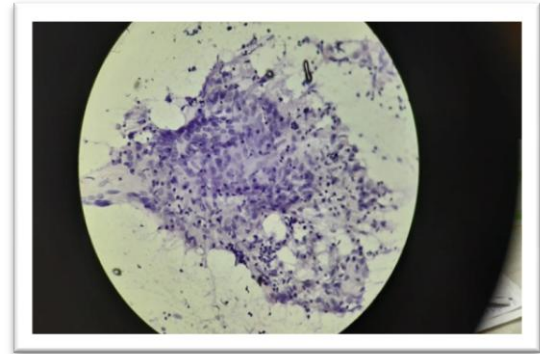


Fig: 1 Showing 10x view of tubercular lymph node

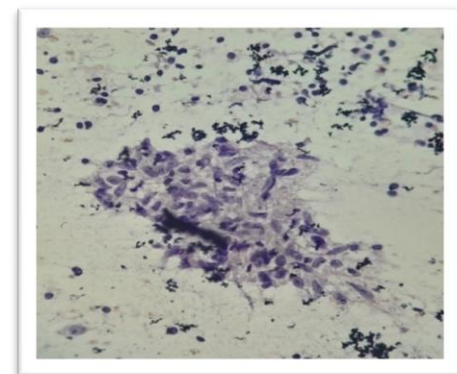
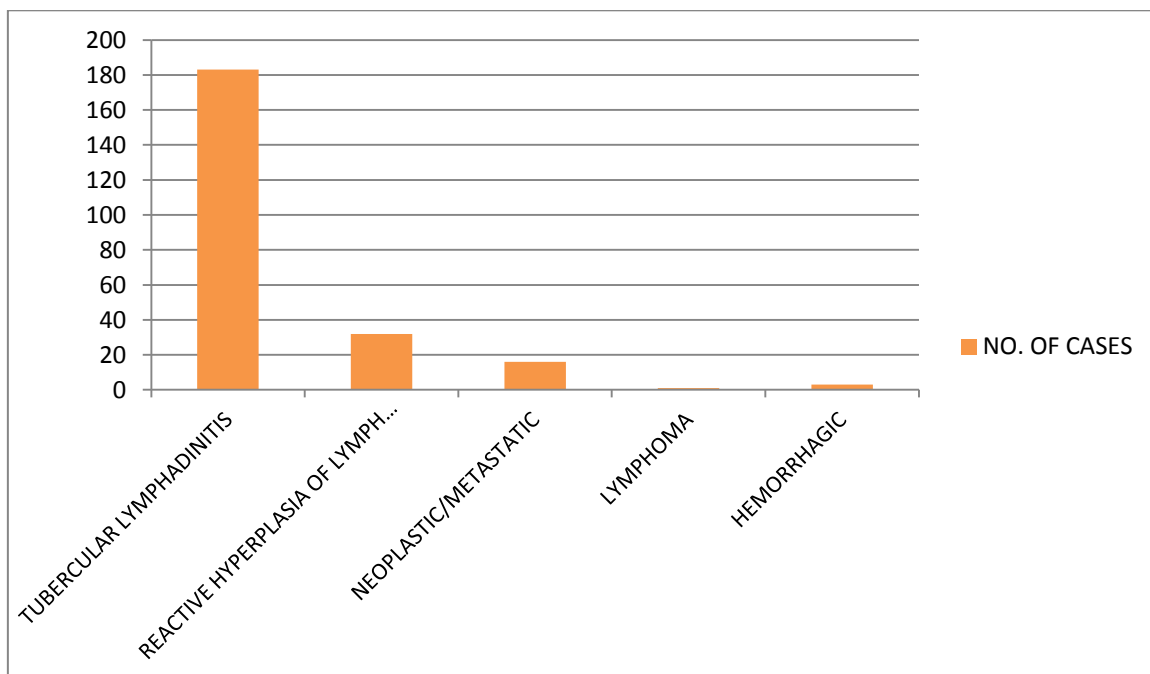


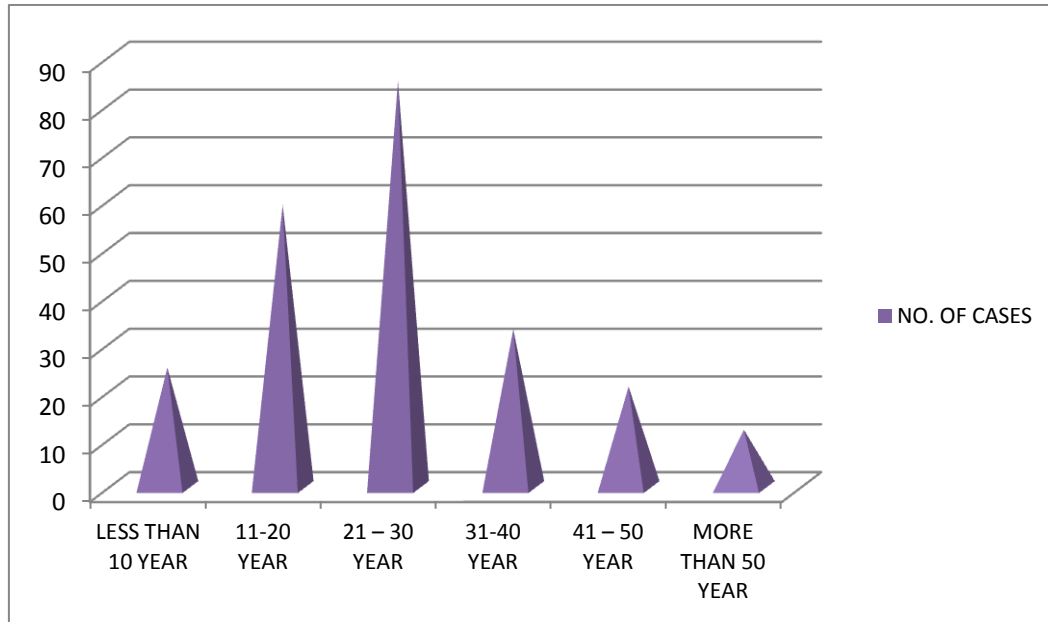
Fig: 2 Showing 40x view of tubercular lymph node with granuloma formation.



Graph no. 1: showing distribution of cases as per cytological diagnosis

Table no. 2: Age Wise Distribution of Cases

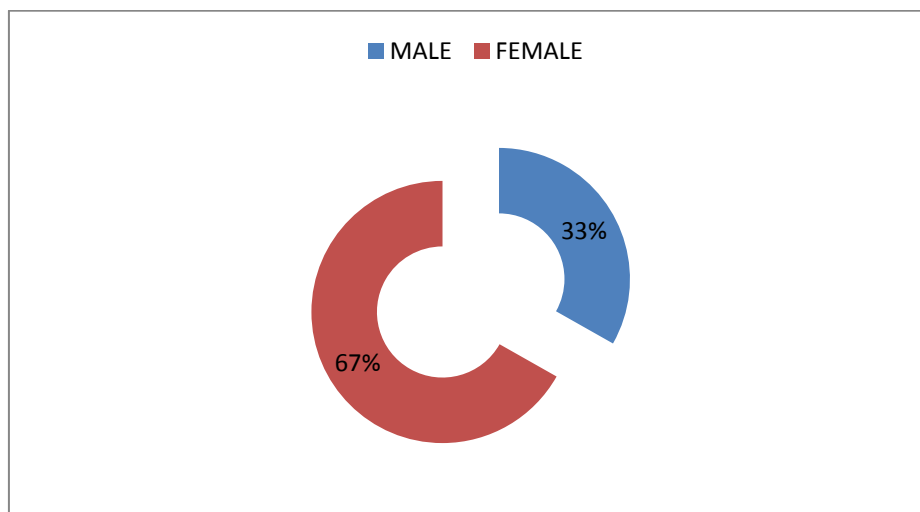
AGE GROUP	NO. OF CASES
LESS THAN 10 YEAR	25
11-20 YEAR	59
21 – 30 YEAR	85
31-40 YEAR	33
41 – 50 YEAR	21
MORE THAN 50 YEAR	12
TOTAL	235



Graph no. 2 showing age wise distribution of cases

Table no. 3: Sex Wise Distribution of Cases

SEX GROUP	NO. OF CASES
MALE	78
FEMALE	157
TOTAL	235



Graph no 3: showing sex wise distribution of cases.

Discussion**Table no. 4**

CRITERIA	PRESENT STUDY	Lakmini K.et al	B C Jha et al
AGE	21 – 30 YEAR	Less than 30 year	mean age of 23.7 years
SEX	F>M	-	F>M i.e 1:1.3
COMMON CYTOLOGICAL FINDING	TUBERCULOSIS	25.58%	Tuberculosis accounted for 60 out of 94 cases of cervical lymph node enlargement.

In present study we have found that tuberculosis is most common diagnosis in cervical lymphadenopathies which is followed by inflammatory lesions. We have found that most of the patients were of age group 21 to 30 years similar results were observed in the studies done by Lakmini K.et al and B C Jha et al. Females were mostly presented with cervical lymph node enlargement.

In our study most of the patients presented with complaints of fever and weight loss similar results were found in study done by Patel and Mehta observed weight loss in 77% and fever in 73% cases.⁽⁶⁾

Similarly Dandapat et al also noted weight loss in 85% and fever in 40% of their patients.⁽⁷⁾

Conclusion

Tuberculosis is still the commonest cause of cervical lymph node enlargement in developing countries. Fine needle aspiration cytology is a rapid, cheap, simple, and effective method of diagnosis for cervical lymphadenopathy.

Reference

1. Wilkinson AR, Mahore SD, Maimoon SA. FNAC in the diagnosis of lymph node malignancies: A simple and sensitive tool. *Indian J Med Paediatr Oncol* 2012;33:21-4.
2. Mehdi G, Singh AK, Hasan M, Ansari HA, Rehman S, Mirza S, *et al*. Cytological evaluation of enlarged lymph nodes in metastatic disease: A hospital-based assessment. *Clin Cancer Investig J* 2015;4: 152-7
3. Mukul Patar, Kusum Borsaikia , Biraj K. Das, Anupam Hazarika. A clinicopathological evaluation of cervical lymphadenopathy in children (0-14 Years) By fine needle aspiration cytology and histopathological examination - A hospital based study. *National Journal of Otorhinolaryngology and Head & Neck Surgery*.2014;2(11):12-14.
4. Allhisier JN, McKnight TA, Shank JC. Lymphadenopathy in a family practice. *J.Fam Pract.* 1981 ; 12 (1) :27-32.
5. Steel BL, Schwartz MR, Ramzy I. Fine needle aspiration biopsy in the diagnosis of lymphadenopathy in 1,103 patients: role, limitations, an analysis of diagnostic pitfalls. *Acta Cytol* .1995;39(1):76-81.
6. Patel RV, Mehta RT. Short term chemotherapy in tuberculous lymphadenitis. *Indian Journal Surgery* 1987;49:336–41.
7. Dandapat MC, Mishra BM, Dash SP, *et al*. Peripheral lymph node tuberculosis: a review of 80 cases. *Br J Surg* 1990; 77:911–2.