



Various Intraoperative Findings Encountered during Appendectomies- An Observational Study

Authors

Karan Singh Thakur¹, Purnima Patial^{2*}

¹Department of Surgery, ZH Mandi, H.P. India

²Department of Medicine, ZH Mandi, H.P.India

*Corresponding Author

Purnima Patial

Abstract

Appendicitis is one of the common diseases faced by the surgeons. Appendectomy is also the most frequently being performed urgent general surgical case. The diagnosis of appendicitis is challenging and requires a skill on the part of the general surgeon to lead to a successful treatment of this disease, thus avoiding the significant morbidity and mortality associated with perforation of appendix. Diagnosis is made on clinical, laboratory and radiological evidences. Standard management is appendectomy. The appendix may be seen in different conditions varying from case to case depending on the duration. Thus quick diagnosis and treatment is helpful in early management and good outcome of the disease. Most of the complications occur when appendix gets perforated. It may simply be found inflamed, but in some cases gets perforated leading localized and even generalized peritonitis. So, Surgeon should be ready to encounter different situations while performing appendix surgery. Surgeon should keep a wide range of possibilities in mind while heading to perform appendectomy. So thorough knowledge is essential for better management and prognosis of the disease.

Keywords: *Appendicitis, peritonitis, lump, perforation, mucocele.*

Introduction

The appendix is a midgut organ and has been long considered to be a vestigial organ. It may be found in a different locations, with the most common being retrocecal in approximately sixty percent of patients, pelvic in thirty percent, and retroperitoneal in 7-10% cases. Appendix has its importance in surgery because of its tendency for inflammation, which leads to events of disease called as acute appendicitis. Appendicitis is the commonest cause of acute abdominal pain among young age group. Appendectomy is the most frequently performed abdominal surgery in

Emergency.

Diagnosis is clinical aided with laboratory and radiological investigations. Management is surgical.

Etiology

There is no single hypothesis to explain cause of appendicitis. Low dietary fiber and high intake of refined carbohydrates may be important. Growth of both aerobic and anaerobic organisms is responsible. Obstruction of appendicular lumen has been widely held responsible. Luminal obstruction with fecolith or a stricture is found in

majority of cases. Fecolith is made up of thickened faecal material, calcium phosphates, bacteria & epithelial debris.

Pathology

Obstruction of the lumen of appendix seems to be essential for gangrene and perforation. Following obstruction, intraluminal pressure increases leading to edema and mucosal ulceration with bacterial translocation to submucosal layer. Further progressive distension leads to venous congestion and ischemia of appendix. With ischemia, bacterial invasion occurs through the muscularispropria and submucosa. Finally, ischemic necrosis leads to gangrenous appendicitis, with free bacterial contamination of peritoneal cavity. The time from onset of obstruction to perforation is variable and may range anywhere from a few hours to a few days. The presentation after perforation is also variable. Alternatively some bowel loops and omentum adheres to inflamed appendix forming phlegmonous mass or paracecal abscess.

Differential diagnosis of appendicitis includes-

Children	Adults(in both males and females)	Adult-females	Aged
Meckels diverticulitis	Ureteric colic	PID	Ca colon
Intususception	Enteritis	Endometriosis	Intestinal obstruction
Gastroenteritis	Rectus sheath hematoma	Ectopic pregnancy	Diverticulitis
HSP	Pancreatitis	Mittelschmerz	Mesentric infarction
Mesentric adenitis	Testicular torsion	Pyelonephritis	Leaking aortic aneurysm
Pneumonia-Lobar	Perforation peritonitis	Ovarian cyst torsion/rupture	Torsion Appendix epiploicae

Diagnosis

The diagnosis of appendicitis is essentially clinical; although, a decision to operate based on clinical grounds alone can lead to the removal of a normal appendix in 15–30 percent of cases. Laboratory reports should be interpreted with caution in cases of suspected appendicitis and should be used to support the clinical picture rather than definitively to prove or exclude the diagnosis. Leukocytosis, often with a “left shift”, is present in 90% of the cases. A normal white blood cell count is found in 10% of cases,

Sometimes inflammation settles which leaves a mucous filled structure called as mucocele of appendix. Knowledge of appendicitis is essential because of its risk of perforation and peritonitis.

Risk factors for appendicular perforation are-

1. extremes of age
2. immuno-compromised state
3. diabetics
4. appendicolith
5. pelvic position of appendix
6. previous abdominal surgery

Clinical features

Symptoms of acute appendicitis include periumbilical pain shifting to right iliac fossa, often associated with anorexia and nausea. Fever may be present. Atypical presentations are often seen in elderly. Clinical signs include pyrexia, tenderness and rebound tenderness. Other signs include Rovsing’s sign, obturator sign and psoas sign. Clinical features may vary according to position of appendix, age, obesity and pregnancy.

however, and it should not be used as a single test to exclude the presence of appendicitis.

A variety of radiological studies may be used to diagnose appendicitis. These consist of x-rays, computed tomography scanning, ultrasonography and magnetic resonance imaging. Abdominal USG or contrast enhanced CT scan further lowers the chances of negative appendectomy. Contrast-enhanced CT abdomen is especially useful in cases where there is a diagnostic dilemma, particularly in the older patients, where other conditions like acute diverticulitis; intestinal

obstruction and neoplasm are likely differential diagnosis.

Many clinical and lab. based scoring systems have been devised to assist the diagnosis. The most widely used is the Alvarado (MANTRELS) score. A score of 7 or more is strongly goes in favor of acute appendicitis.

Alvarado/MANTRELS Score	
Parameter	Score
Symptoms	
Migratory pain in RIF	1
Anorexia	1
Nausea	1
Signs	
Tenderness in RIF	2
Rebound tenderness	1
Elevated temprature	1
Lab.	
Leucocytosis	2
Shift to left	1
Total	10

Treatment

Conservative treatment may be considered in a patient with limited signs or in those having high risk of surgery (e.g. with multiple comorbidities). However, appendectomy is the standard of care. While there should be no undue delay, all patients, mainly those at risk of serious morbidity, benefit by a short duration of intensive preoperative preparation. When peritonitis is anticipated, intravenous antibiotics to cover gram-negative bacilli as well as anaerobic cocci should be started. Appendectomy may be done by open as well as laparoscopic techniques. Postoperative complications following appendectomy are

relatively uncommon and reflect the degree of peritonitis that is present at the time of surgery and con-current diseases that may predispose to complications.

Cases Study

An Observational study was conducted in the department of surgery of this institution. Study period was of one year. Study was conducted on 70 patients who underwent appendectomies between August 2019 to July 2020. Patients diagnosed clinically, after laboratory tests and radiological confirmation were taken for surgery. Open appendectomy approach was done in all these patients. Different intraoperative findings were encountered in operating room ranging from inflamed appendix to generalized peritonitis.

Observations and Results

Total 70 patients who were operated in one-year study period, were taken in study group. In 39 patients features only of acute appendicitis i.e. inflammation, distension and edema were found. So majority of patients had acutely inflamed appendix.

In 12 patients appendix was found be perforated. In 10 patients perforation with localized peritonitis was seen. Perforation with generalized peritonitis was seen in 2 patients.

Appendicular lump/mass was found in 5 patients. Appendicular abcess was seen in 7 patients. In 5 patients gangrenous appendicitis was found. Mucocele of appendix was seen in 2 patients.

Overall presentation was as in the table below-

S.no.	Finding Intra-op	Number	Percentage (%)
1	Appendicitis- inflammation only	39	55.7
2	Perforation with localised peritonitis	10	14.3
3	Perforation with generalised peritonitis	2	2.9
4	Appendicular lump	5	7.1
5	Appendicular abcess	7	10
6	Gangrenous appendicitis	5	7.1
7	Mucocele of appendix	2	2.9
	Total cases	70	100

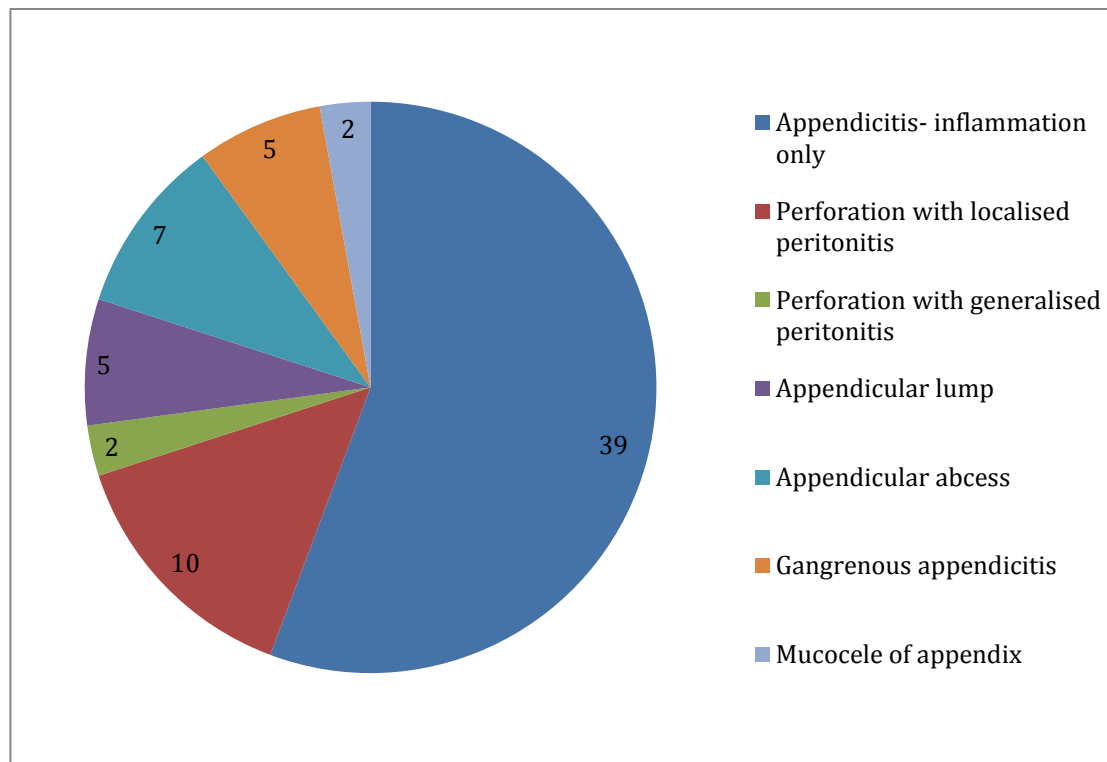


Fig. Diagrammatic presentation of the intra-op findings of 70 patients

Discussion

Appendicitis is the common surgical condition, which can affect any age group, ranging from early childhood to elderly. Diagnosis may be made clinically, aided with laboratory and radiological reports. Standard treatment is surgical. Appendectomy is the most common abdominal surgery being performed. A surgeon may encounter different conditions while performing surgery for appendix. As noticed in this study, acutely inflamed appendix is the most common finding, which is followed by perforated appendix. In majority of perforated appendix, peritonitis is limited to right iliac fossa i.e. localized. Diffuse peritonitis is although seen in very less cases, is associated with increased morbidity. Other findings encountered are appendicular abscess and gangrenous appendicitis. Few cases may show mucocele of appendix. So surgeons should be aware to encounter these situations, which may avoid any unfavourable circumstances.

References

1. Norman SW, Ronan P, Andrew WM. The vermiform appendix, 27th ed., Bailey and Love Short Practice of Surgery: 1299-1317.
2. Kumar V, Cotran RS, Robbins SL. Appendix; in Robbins Basic Pathology. 5th edition London: W.B. Saunders 1992; 520.
3. Shrivastava UK, Gupta A, Sharma D. Evaluation of the Alvarado score in the diagnosis of acute appendicitis. *Twip Gastroenterol* 2004; Oct.- Dec.,25(4): 184-6.s
4. Margenthaler JA, Longo WE, Virgo KS, Johnson FE, Oprian CA, Henderson WG, et al. Risk factors for adverse outcomes after the surgical treatment of appendicitis in adults. *Ann Surg.* 2003;238:59–66.
5. Varadhan KK, Neal KR, Lobo DN. Safety and efficacy of antibiotics compared with appendicectomy for treatment of uncomplicated acute appendicitis: meta-analysis of randomised controlled trials. *BMJ.* 2012;344:e2156.

6. Alvarado A. A practical score for acute appendicitis. *Ann Emerg Med.* 1986 May; 15(5): 557-64.
7. Courtney MT, Daniel B, Mark, E, Kenneth LM, Richmond B. The Appendix, 20th ed. *Sabiston textbook of Surgery*: 1296-1311.