



Clinical Case

Endodontic Management of Mandibular Premolars with Two Roots and Two Root Canals: A Case Series

Authors

**Binawara Kamal Kishore¹, Parvez Shahina^{2*}, Agarwal Manoj³, Jain Anil⁴,
Khatri Sunil Kumar⁵, Gupta Amit Kumar⁶**

^{1, 4, 5, 6}Postgraduate Student, Department of Conservative dentistry and Endodontics, RUHS College of Dental Sciences, Jaipur, Rajasthan

²Associate Professor and Head of Department of Conservative Dentistry and Endodontics, RUHS College of Dental Sciences, Jaipur. Rajasthan

³Assistant Professor and Head of Department of Conservative Dentistry and Endodontics, RUHS College of Dental Sciences, Jaipur. Rajasthan

*Corresponding Author

Dr Shahina Parvez

Abstract

Recognition of unusual variations in the canal configuration is critical. Mandibular premolars are one of the most difficult teeth to treat endodontically because of the variations on root canal anatomy. Thorough knowledge of the root canal morphology, critical interpretation of radiographs is a prerequisite for successful root canal therapy. This article reports case series of mandibular premolars with two roots and two root canals, which was successfully treated with root canal therapy.

Keywords: mandibular premolars, CBCT, canal pattern.

Introduction

Successful endodontic therapy of a tooth demands that the dentist should have thorough knowledge of the root canal morphology, making it mandatory towards thorough radiographic evaluation and diagnosis of the status of the pulp canals as well as the periapical areas. Improper diagnostic protocol may lead to the failure of endodontic treatment.

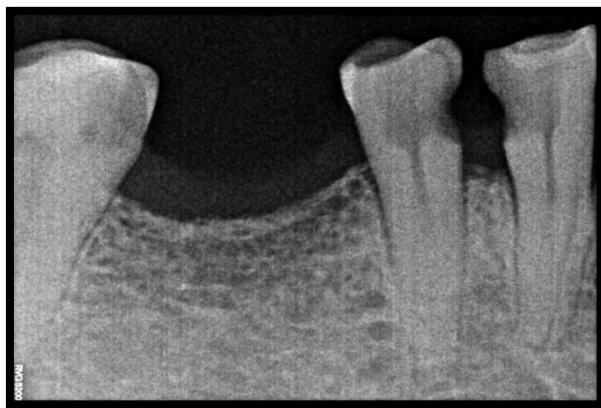Slowey has suggested that mandibular first premolars, often called as “Endodontist’s enigma,” may present the greatest difficulty of all teeth to perform successful endodontic treatment.¹

Brescia (1961) reported that the mandibular premolar teeth had the most variable canal pattern (Ingle and Taintor 1985). It is well known fact that the root canal system varies with race and gender [Trope et al 1986, Sert and Bayirli (2004), Ahmed et al (2007)². The anatomy of the pulp space decides the parameter with which root canal therapy will be carried out and its success. Root canal variations pose a challenge for the clinician. According to Weine (1995)³, the major cause of endodontic failure are incorrect canal instrumentation, incomplete obturation and untreated major canals.

The use of CBCT in this rare case greatly contributed toward making a confirmatory diagnosis and successful endodontic management. This article reports on the clinical cases of mandibular premolars with two roots and two root canals.

Case 1

A 62 year old male patient reported to the Department of Conservative dentistry and Endodontics, RUHS, college of dental sciences, jaipur with the Chief complaint of Pain in lower right back tooth region since 3 months. History revealed patient had spontaneous pain in the same region and aggravated on chewing and lying down. The patient's medical history was non contributory. He gave the history of previous dental treatment before 3 month. Clinical examination revealed carious exposure of the pulp in relation with #44 and #45.

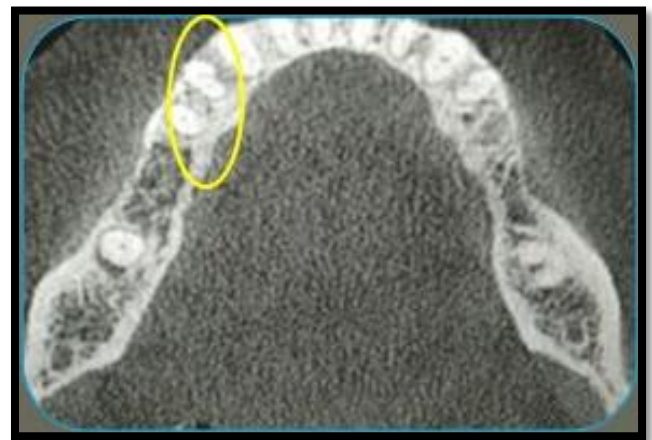

Radiographic examination of the tooth indicated an unusual anatomy of two roots in first premolar, and also there was widening of the apical periodontium and the necessity for root canal treatment. Extra medially and distally angulated periapical radiograph was taken to help in a better interpretation of the canal system. Based on the clinical and radiographic evidences, it was diagnosed as previously initiated therapy in relation to the mandibular right first and second premolar.

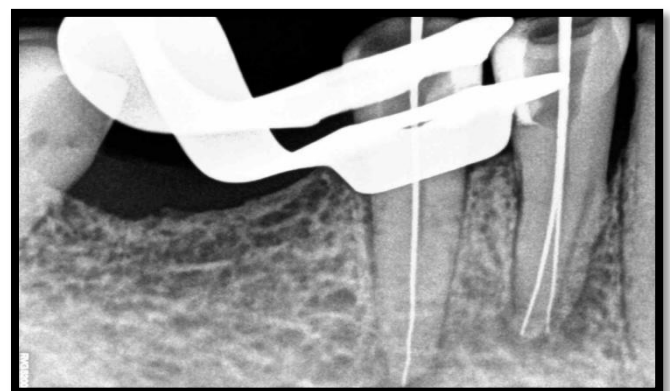
Anesthesia was achieved by means of mental nerve block with 1ml of 2% lignocaine with

1:80,000 adrenaline. Teeth were isolated using rubber dam and all caries were removed and Endodontic access cavity was modified for a straight line access using an Endo-access bur. The pulp chamber was frequently flushed with 3% sodium hypochlorite to remove debris. A DG 16 explorer was used to locate canal orifices and Examination of the pulp chamber floor revealed two distinct orifices.

CBCT was advised to confirm the number of root canals. CBCT detect the presence of two root canals in mandibular right first premolar and single canal in second premolar.



Canal patency was checked with #10 K file. Working length was determined using #10 k file with the i root electronic apex locator and confirmed radiographically.

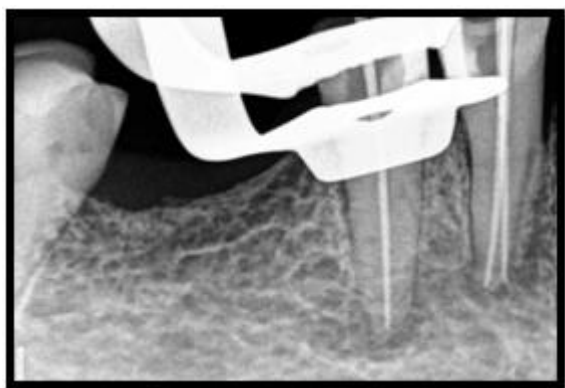


Working length radiograph

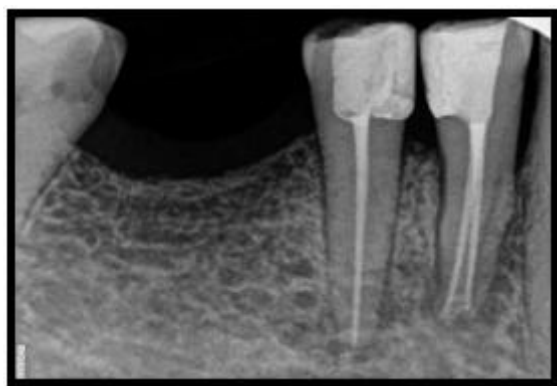
Cleaning and shaping was started with establishing a glide path. Both the canals were prepared with master apical file #30 with 2% taper. Copious irrigation with normal saline solution and 3% sodium hypochlorite and 17%

EDTA was used between each file throughout the entire procedure. After cleaning and shaping the teeth were then dried with sterilized paper points and Intra-canal dressing of calcium hydroxide powder mixed with saline, carried through lentulo spirals, was given for 1 week.

After 1 week patient was asymptomatic and canals were obturated with cold, lateral condensation of gutta percha cones (Dentsply) and seal apex sealer. Post endodontic restorations was done with composite.



Master cone radiograph

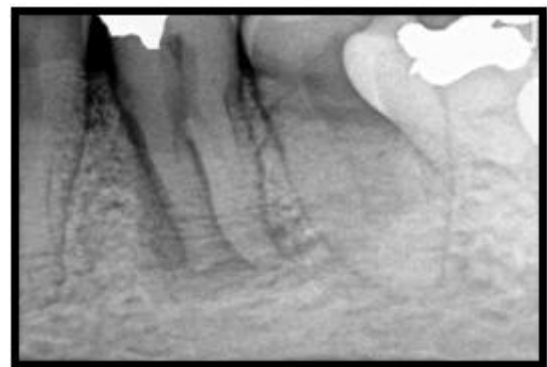


Post obturation radiograph

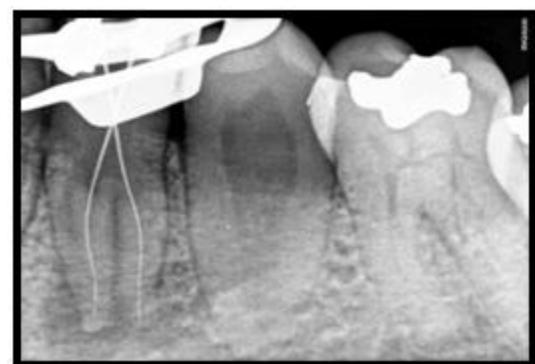Case 2

A 42 year old male patient reported to the Department of Conservative dentistry and Endodontics, RUHS College of Dental Sciences, Jaipur with Chief complaint of Pain in lower left back tooth region since 2 months. History revealed that patient had first experienced sensitivity to cold drinks followed by pain. Pain was spontaneous in nature and aggravated on chewing and lying down. Clinical examination Revealed restoration in mandibular left first

premolars which was tender on percussion. The patient's medical history was non contributory.

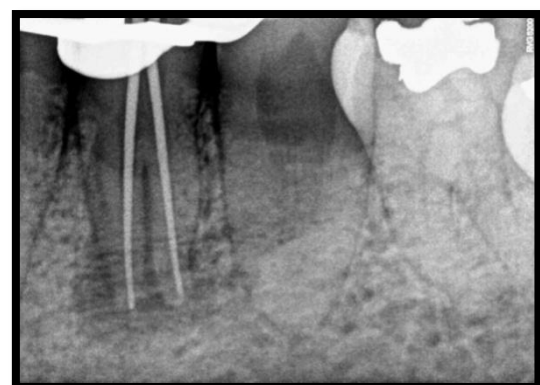


Preoperative IOPA

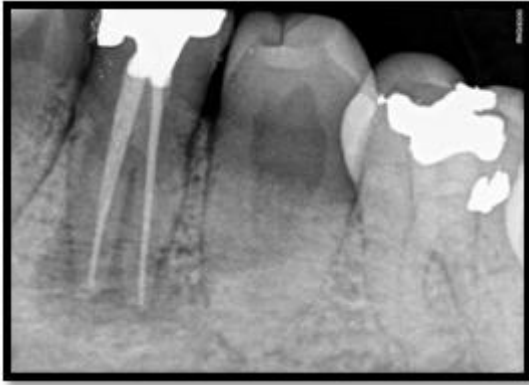

Working length IOPA

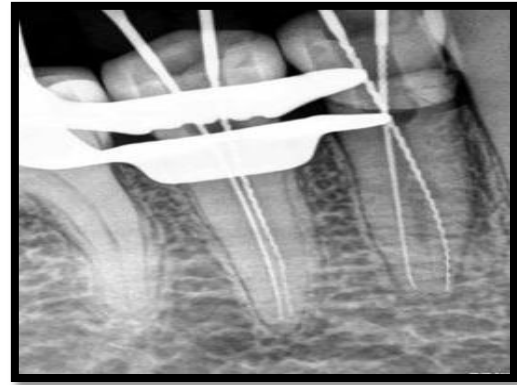
Radiographic examination revealed restoration on the mesial aspect of crown, root bifurcation with distinct outline of the mesial and distal root with ill defined periapical radiolucency. Based on the clinical and radiographic evidences diagnosis of acute exacerbation with chronic apical periodontitis was made. Root canal treatment procedure was same as described in case 1.



Master cone IOPA



Post obturation IOPA



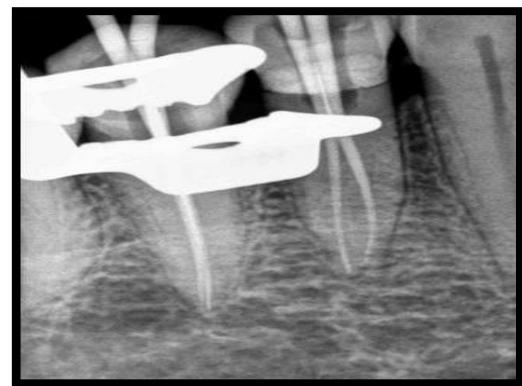
Working length IOPA

Case 3

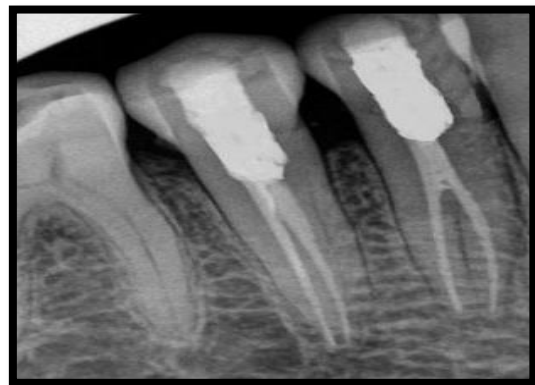A 53 year old male patient reported to the Department of Conservative dentistry and Endodontics, RUHS College of dental sciences, Jaipur with Chief complaint of Pain in lower right back tooth region since 2 months. Patient gave a history of pain before 1 week for which he undergone dental treatment in right lower jaw region in relation to #44 and #45 before 5 days. On intra oral examination the access cavity of mandibular right first and second premolar is filled with cotton and associated with food lodgement in the same. Tenderness on percussion was +ve in relation to #44 and #45.

Radiographic examination revealed radiolucency in coronal structure of 44 and 45 showing access opening has already been attempted. Radicular portion of 44 and 45 shows to distinct root canal morphology. Based on the clinical and radiographic evidences, diagnosis of previously initiated therapy in relation to 44 and 45 was made.

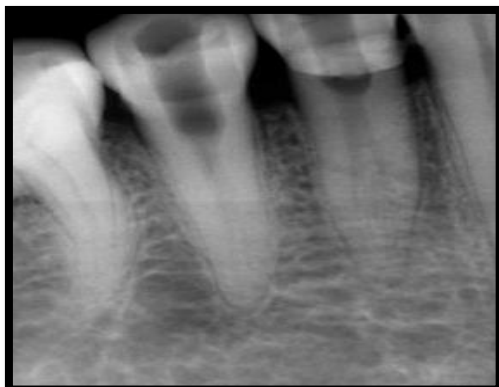Root canal treatment procedure was same as described above.



Master cone IOPA



Post obturation IOPA



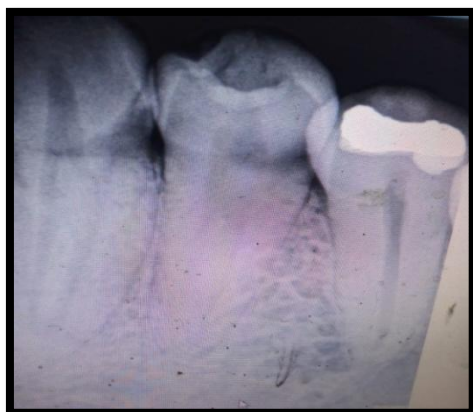Preoperative IOPA

Case 4

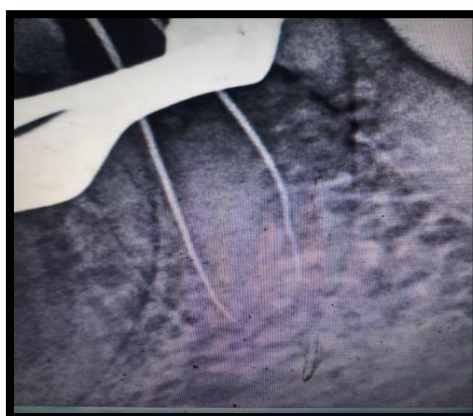
A 35 year old male patient was reported to the RUHS College of Dental Sciences with Chief complaint of Pain in lower left back tooth region since 3 months. History Revealed patient had spontaneous pain in the same region and aggravated on chewing and lying down. Clinical examination Revealed carious exposure of the

pulp in relation to mandibular left first premolar (#34). The tooth was tender on percussion.

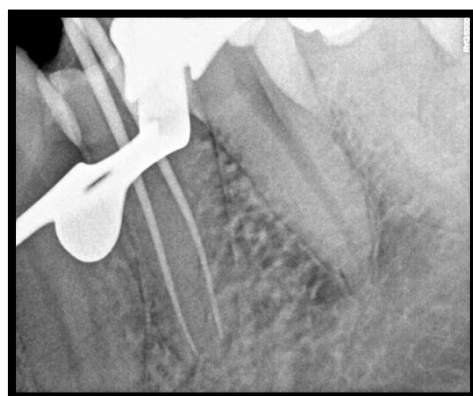
Radiographic examination revealed caries extending to pulp and an unusual root anatomy. Based on the clinical and radiographic evidences, Diagnosis of irreversible pulpitis with symptomatic apical periodontitis was made. Root canal treatment procedure was same as described above



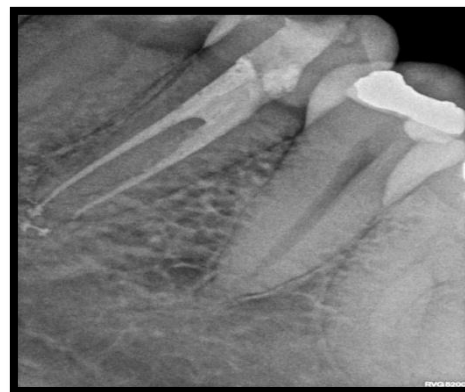Preoperative IOPA



Working length IOPA



Master cone IOPA



Post obturation IOPA

Discussion

Since 1870 the literature reveals a periodic renewal of interest in the root canal morphology of teeth. Many methods have been used to investigate the^(4,5,6) morphology of root canals. Variation in root canal morphology was suggested as the most likely reason for the high frequency of endodontic flareups and failures⁷.

The mandibular premolars is usually a single rooted teeth with single root canal system. The root morphology and canal morphology of the mandibular premolar can be extremely complex and highly variable⁸. The incidence of the number of roots and of the number of canals reported in anatomic studies varies greatly in the literature.

The mandibular first premolar had one canal at the apex in 74.0% of the teeth, two canals at the apex in 25.5%, and three canals at the apex in 0.5% of the teeth. The mandibular second premolar had one canal at the apex in 97.5% and two canals at the apex in 2.5% of the teeth⁹.

When endodontic therapy is performed, the dentist should first consider the internal anatomy of the tooth. Before beginning the preparation for access, he should study radiographs from several different angles. Preoperative radiographs are helpful to identify anatomical alterations of the root canal system. The analysis of the dentin map of floor of pulp chamber can help identifying variations thus, facilitating the proper location of all root canals¹⁰. It is usually on these angle radiographs that the presence of more than one root canal is first apparent. In addition, if the direct periapical view of a root canal shows a sudden narrowing or even

if it disappears, the dentist should realize that the canal diverges at that point into two parts that may either remain separate or merge before reaching the apex.

Recently, we can also take the help of microscope and dental CT scanning for better treatment of such anatomical complexity.

Conclusion

Successful endodontic outcome in such cases is dependent upon careful use of all the available diagnostic aids to locate and treat the entire root canal system. Careful interpretation of angled radiograph, Proper access preparation, detailed exploration of the interior of the tooth ideally under magnification. Recently CBCT is an important diagnostic tool to determine or confirm the presence and location of canal .

References

1. Slowey RR. Root canal anatomy. Road map to successful endodontics. Dent clin North Am 1979;23:555-73.
2. Cohen S, Hargreaves KM (2006) Pathways of pulp, 9th edn. Pg:216-7.
3. L.A. Awawdeh & A.A.Al-Qudah, International Endodontic Journal 41,240-248, 2008.
4. Weine.F.S. Non surgical retreatment of endodontic failure. Compendium of continuing education in dentistry – 1995; 16:p326-35.
5. Skidmore AE, Bjorndal AM. Root Canal morphology of the human mandibular first molar. Oral Surg 1971; 32:778-84.
6. Mayo CV, Montgomery S, del Rio C. A computerized method for evaluating root canal morphology. J Endodon 1986;12:2-7.
7. Kasahara E, Yasuda E, Yamamoto A, Anzai M. Root canal system of the maxillary central incisor. J Endodon 1990;16:158-61.
8. England MC Jr, Hartwell GR, Lance JR. Detection and treatment of multiple canals in mandibular premolars. J Endodo 1991; 17:174-8.
9. Ash M, Nelson S. Wheeler's Dental anatomy, physiology and occlusion. 8th ed. Philadelphia: Saunders, 2003.
10. Vertucci FJ: Root canal morphology of mandibular premolars, J Am Dent Assoc 97:47, 1978.
11. De Moor RJG, Calberson FLG. Root canal treatment in a mandibular second premolar with three root canals. J Endod 2005; 31:310- 313.