

**Original Article****Outcome of Small Incision Cataract Surgery in patients with pseudoexfoliation syndrome**

Authors

Dr S. Vishali¹, Dr Loganathan^{2*}, Dr Annapurna Kumar³¹Post graduate, Department of Ophthalmology, Sri Venkateshwaraa Medical College Hospital and Research centre, Pondicherry²Professor and HOD, Department of ophthalmology, Sri Venkateshwaraa Medical College Hospital and Research centre, Pondicherry³Professor, Department of ophthalmology, Sri Venkateshwaraa Medical College Hospital and Research centre, Pondicherry

*Corresponding Author

Dr Loganathan**Introduction**

Lindberg first described pseudoexfoliation (PXF) in 1917.⁽¹⁾⁽²⁾ Pseudoexfoliation syndrome is an age related, genetically determined, multifactorial disease of the elastic structures. It is usually a bilateral disorder but markedly asymmetric. This disease remains subclinical. It is commonly deposited on the corneal endothelium, iris, anterior lens capsule, zonules of the lens and trabecular meshwork.⁽³⁾⁽⁴⁾

Apart from ocular tissues, it is also seen in other parts of the body such as lungs, heart, kidney, liver, blood vessels and cerebral meninges. Presence of pseudoexfoliation material in extra ocular tissues suggest PXF is a multi-organ disorder. Hence patients having ocular PXF may present with systemic manifestations like hypertension, angina, cardiovascular disease, abdominal aortic aneurysm, transient ischemic attacks and stroke.⁽⁴⁾⁽⁵⁾⁽⁶⁾

It is important to diagnose PXF before cataract surgery since it predisposes to complications

mainly due to poor mydriasis and weak zonules. The complications that can occur before and during cataract surgery are poor mydriasis, subluxation or dislocation of lens, glaucoma, zonular dialysis, posterior capsule rupture, vitreous loss.⁽¹⁾⁽⁷⁾ Postoperatively decentration or dislocation of the Intra ocular lens (IOL) can occur due to progressive proteolytic disintegration of the suspensory ligament causing weakening of the capsular support and zonular apparatus.⁽⁸⁾⁽⁹⁾

Further pupillary dilatation is poor or inadequate due to iris atrophy. Post operatively fibrinous reaction and inflammation in the anterior chamber are more common in pseudoexfoliation patients compared to patients without pseudoexfoliation, this is due to a weak blood aqueous barrier in patients with pseudoexfoliation.⁽¹⁰⁾ Corneal endothelial loss also occurs among these patients which can lead on to corneal decompensation.⁽¹¹⁾⁽¹²⁾

In this study our aim is to analyse the visual outcome of cataract surgery in patients with

pseudoexfoliation syndrome and to study the clinical features of pseudoexfoliation in eyes with cataract.

Materials and Methods

This was a prospective study, conducted in the Department of Ophthalmology, Sri Venkateshwaraa Medical College Hospital and Research Centre, Ariyur, Pondicherry between November 2017 and May 2019 for a period of 18 months. This study was done after getting clearance from institutional scientific and ethical committees according to Helsinki declaration and valid written informed consent from 80 patients with cataract and pseudoexfoliation (PXF).

All patients with senile cataract and clinical evidence of pseudoexfoliation who have given written informed consent to participate in this study were included. Patients with the following conditions were excluded from the study -

Traumatic cataract, complicated cataract, congenital cataract and metabolic cataract

Glaucoma

Corneal opacities

Uveitis, retinal pathology or ocular pathology other than PXF.

Pre operatively, all patients underwent a complete ophthalmic evaluation, as well as necessary systemic examination and investigations were done.

Visual acuity preoperatively was recorded. Slit lamp examination was done to look for pseudoexfoliation material over the anterior segment structures, to grade the lenticular opacity and to check for phacodonesis in case of zonular weakness. Keratometry and A-Scan were done to calculate the IOL power. Posterior segment was evaluated with +90D and Indirect ophthalmoscopic examination. Intra ocular pressure was measured by Goldman's applanation tonometry and patency of nasolacrimal duct was ensured by doing syringing.

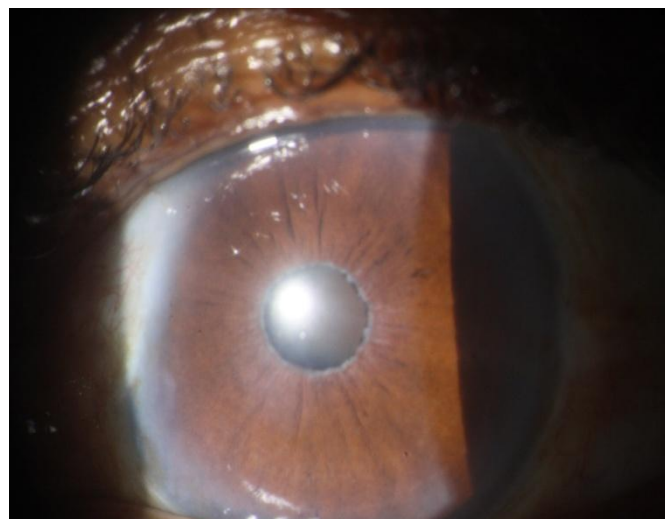

Figure: 1 Pre-op pseudoexfoliation patient with nuclear cataract

Manual SICS was done to all patients. Depending on the degree of mydriasis, intracameral adrenaline, mechanical stretching of pupil or sphincterotomy were done to dilate the pupil. Single piece rigid PMMA IOL was placed in the capsular bag in most of the patients. 3 piece rigid PMMA PCIOL was used in patients with weak zonular support. Patients who had posterior capsule rupture underwent secondary iris claw lens implantation after a month.

Postoperatively, patients were given topical antibiotics (ciprofloxacin 0.3%) and steroid (dexamethasone 0.1%) eye drops in tapering dose for 6 weeks.

Patient was followed up for 3 months after the discharge as follows- after 1 week, after 1 month and after 3 months. During each visit patients were evaluated for BCVA, slit lamp examination to look for corneal edema, uveitis, pigment dispersion, IOL stability (decentration and displacement), IOP measurement for glaucoma.

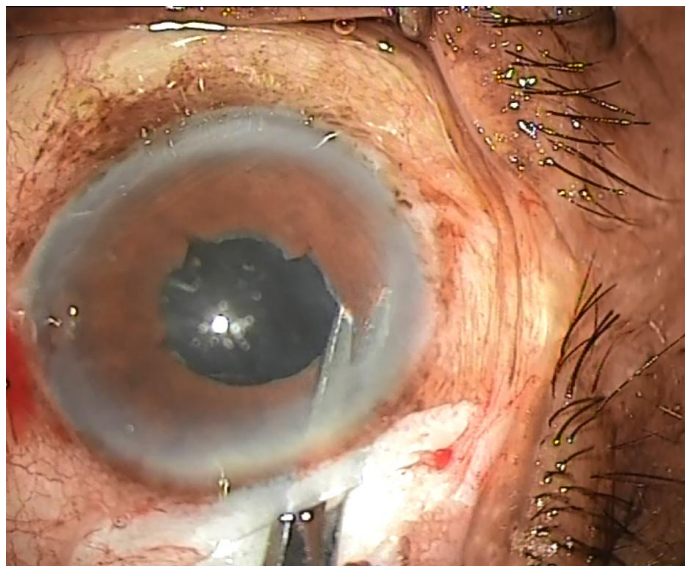


Figure: 2 Intra-op during sphincterotomy

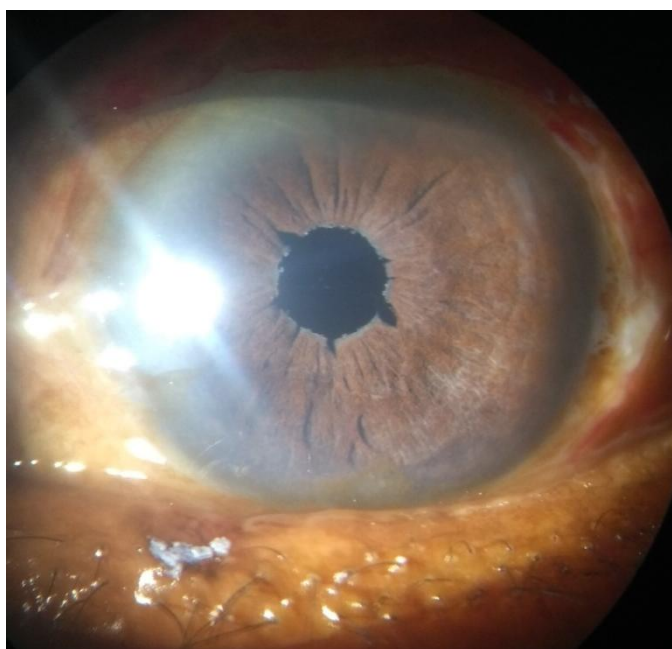


Figure: 3 Post op Manual SICS

The collected data were entered in Microsoft excel sheet 2013 and analysed with IBM. SPSS statistics software 23.0 Version. To describe the data descriptive statistics, frequency analysis and percentage analysis were used for categorical variables and the mean & standard deviation were used for continuous variables. To find the significance in categorical data Chi-Square test was used. In the above statistical tool the probability value 0.05 is considered as significant level.

Results

The age group of our patients was from 50 to 81 years with a mean age of 66.36. The patients were divided into four groups based on the decade wise age range. Most of the patients (38 patients) were in the 60-69 years category. 45 (56.3%) were male and the rest were female. Thirty eight patients had associated systemic co-morbidities. Hypertension was the most common co-morbidity with a prevalence of 30% (24 patients), followed by diabetes mellitus (14 patients), then heart disease (6 patients), bronchial asthma and kidney disease. Most of these patients had more than one systemic disease. In our study, 58 patients (72.5%) had pseudoexfoliation in both eyes while 22 patients (27.5%) had unilateral pseudoexfoliation. It is also noted that younger patients had unilateral pseudoexfoliation while older patients had bilateral pseudoexfoliation. Fifty seven patients (71.3%) had poor mydriasis. We considered the patient to have poor mydriasis if the patient has size of the pupil less than or equal to 5 mm. Three fourths of the patients had an average pupillary size of 4-5 mm.

Table 1 Grading of mydriasis in eyes with pseudoexfoliation

Mydriasis (mm)	Frequency	Percentage
3	14	17.5
4	25	31.3
5	18	22.5
6	9	11.3
7	12	15
8	2	2.5
Total	80	100

Grading of cataract was done with slit lamp examination. Among these maximum patients were found to have nuclear sclerosis grade 2.

Table 2- Cataract grading

Cataract grading	Frequency	Percentage
NS 2	28	35.0
NS 3	18	22.5
NS 4	12	15.0
NS 5	6	7.5
Mature cataract	16	20

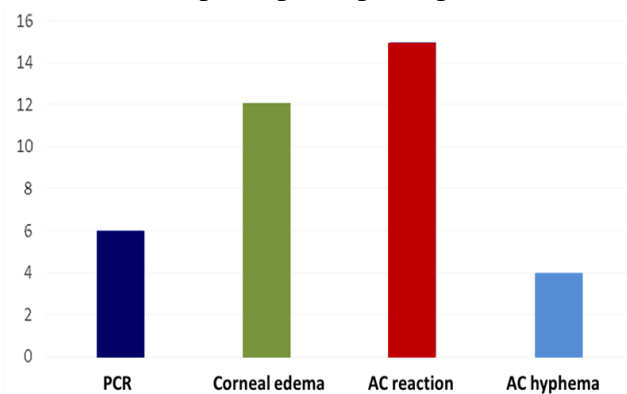
Six of the 80 patients (7.5%) had intraoperative posterior capsular rent necessitating anterior vitrectomy. IOL implantation was deferred for these patients, who were implanted with a posterior chamber iris claw as a secondary procedure one month later. The remaining patients were implanted with either a single or 3 piece PMMA IOL according to zonular stability.

Table 3- IOL implanted

IOL implanted	Frequency	%
Single piece IOL	39	48.75
3 piece IOL	35	43.75
Iris claw lens	6	7.5

There were four main complications that occurred during and after the cataract surgery out of which anterior chamber reaction is the most common one.

Chart 1 Intra-op and post-op complications



The rate of complications was greater in patients with poor mydriasis when compared to patients with good mydriasis. This was found to be statistically significant (p value 0.005). More than half of the patients with poor mydriasis had complications whereas less than one fourth of the patients with good mydriasis had complications. The best corrected visual acuity (BCVA) was checked after one week, one month and three months after the surgery, and was graded as good(6/6-6/18), fair(6/24-6/60) and poor(<6/60). BCVA of 1st week and 3rd month compared and

found to have improvement which is statistically significant (p value 0.005). The good BCVA improved from 81.25% to 88.75%.

Table 4- Frequency distribution of BCVA in post-operative period

Grading of BCVA	At the end of one week		At the end of one month		At the end of 3 months	
	Frequency	%	Frequency	%	Frequency	%
Good	65	81.25	68	85	71	88.75
Fair	14	17.5	12	15	9	11.25
Poor	1	1.25	0	0	0	0

It is also found that soft cataract (NS2) had better visual outcome than hard cataract (>/= NS3) which was also statistically significant. (P value 0.0019). Patients with poor mydriasis <5mm had poor visual outcome which was also statistically significant. (p value 0.001)

Discussion

Pseudoexfoliation is a common condition seen in elderly people. The prevalence of PXF in South India is reported to be 3.8% with male preponderance (58%).⁽¹⁾ Our study has slight male preponderance (56.3%) when compared to female. Fifty eight patients (72.5%) had pseudoexfoliation in both eyes while 22 patients (27.5%) had unilateral pseudoexfoliation. It is also noted that younger patients had unilateral pseudoexfoliation while older patients had bilateral pseudoexfoliation. Pseudoexfoliation is more commonly associated with systemic illness because of the deposition of pseudoexfoliation material in vessel wall and various organs like lungs, heart, kidney, liver, and cerebral meninges causing degeneration. It increases the odds of vascular disease by 72%.⁽⁴⁾⁽⁵⁾In our study 38 patients had systemic illness, among which more number of patients had hypertension(24). Most of the patients had one more than one systemic disease.

Pseudoexfoliation is seen as flake like deposits on transillumination in slit lamp. Krukenburg spindle

may be seen on the cornea.⁽¹¹⁾⁽¹³⁾⁽¹⁴⁾ Aqueous flare may also be seen due to weakening of blood aqueous barrier. Sampaolesi line is a pigmented line found anterior to Schwalbe's line which is seen on gonioscopy.⁽¹⁴⁾⁽¹⁵⁾ Iris sphincter may show moth eaten appearance. Loss of raphe in the pupillary area is one of the earliest sign of pseudoexfoliation. Other signs are pseudoexfoliation material in pupillary border seen as greyish white deposits. When the pupil is dilated a double ring with target appearance is seen on anterior lens capsule- the central translucent disc and the peripheral granular band of PXF with the clear area in between is seen.⁽¹⁴⁾ In our study, significant number of patients (27) had pseudoexfoliative material only over the anterior lens capsule. This signifies the need to do slit lamp examination after pupillary dilatation, as these cases can be easily missed. Such missed preoperative diagnosis of pseudoexfoliation makes the surgeon unprepared for intraoperative complications.

The degree of zonular weakness does not correlate with the amount of pseudoexfoliative material present in the eye. The signs of zonular instability include iridodonesis, lens subluxation, phacodonesis and zonular dialysis of which iridodonesis is the earliest sign.⁽¹⁶⁾⁽¹⁷⁾

A well dilated pupil is one of the main requirements for a safe and successful cataract surgery.⁽¹⁸⁾ This is even more important in eyes with pseudoexfoliation syndrome, in which surgery is more complicated because of the risks associated with loss of zonular integrity and poor pupillary dilatation.⁽¹⁰⁾ In this study, patients with dilatation less than or equal to 5mm were considered to have poor mydriasis which was present in 57 eyes (71.3%). It was found that poor mydriasis was associated with more number of complications and which in turns affected the post-operative visual outcome which was consistent with similar types of studies.⁽¹⁾⁽⁷⁾⁽¹⁰⁾⁽¹⁶⁾⁽¹⁹⁾⁽²⁰⁾

Intra operatively small pupils were managed by one or more of the following techniques according

to grade of cataract and amount of mydriasis. Intracameral adrenaline was given to 11 patients, stretch pupilloplasty was done in 10 patients and multiple small sphincterotomy in 33 patients. In some of these patients more than one technique were used to manage small pupil and judicious use of OVDs were done in all patients. Pupil expanders were not used in these patients because of their poor affordability. These patients who underwent stretch pupilloplasty and multiple small sphincterotomies, were found to have pigment dispersion and irregular pupil post operatively.

There was significant improvement in BCVA from 1st post op week to 3rd post op month which was statistically significant. The most common intra-operative complication encountered was posterior capsular rent in 6 patients (7.5%). Out of these 5 patients had vitreous loss. These patients underwent iris claw lens implantation as a secondary procedure after 1 month.

In our study, postoperative AC reaction (flare, cells and inflammatory membrane) is the most common complication in patients with pseudoexfoliation. This may be due to multiple reasons like breakdown of blood aqueous barrier, more frequent instrumentation intraoperatively and more manoeuvres due to poor mydriasis and protein leakage from iris vessels.⁽²¹⁾⁽²²⁾

Another common complication encountered post-operatively was corneal edema which was found in 12 patients. This may be due to pre-existing endothelial decompensation, prolonged surgery and increased use of instrumentation and manoeuvres. But in most of these cases, corneal edema subsided after medical management. This result is comparable with previous studies conducted Naseem et al, Madhavi et al, Sufi et al.⁽¹⁾⁽⁷⁾⁽²⁰⁾

Six patients (7.5%) had posterior capsular opacification after 3 months for whom Nd Yag Laser capsulotomy was done and vision improved significantly. There are many possible mechanism postulated for higher incidence of PCO formation in patients with pseudoexfoliation. Firstly, poor mydriasis intra operatively, weak zonular support,

posterior synechiae, and corneal decompensation may force the surgeon to minimise removal of equatorial lens cortex and lens epithelium and to reduce polishing of the posterior capsule during cataract surgery, thus predispose to proliferation of lens epithelium and formation of posterior capsular opacification. Secondly, zonular weakness causing zonular dialysis which leads to capsular folds and migration of lens epithelial cells. Thirdly as we already know there is breakdown of blood aqueous barrier leading to leakage of protein. This protein may act as 'culture media' for proliferation of epithelial cells. Lastly, it has been demonstrated that intraocular hypoxia acts as strong stimulant for proliferation of cells. Since there is anterior segment hypoxia in pseudoexfoliation patients, it can stimulate proliferation of lens epithelial cells leading to posterior capsular opacification.⁽⁹⁾⁽²¹⁾⁽²³⁾

Limitation of this study was that our follow-up period was only 3 months, so late post-operative complications like IOL decentration/ dislocation and after cataract could not be evaluated. Also a control group was not available for comparison. Our study was small-scale; while a larger scale study is required to test the findings in larger population.

Conclusion

Major problems in pseudoexfoliation patients are small pupil and weak zonules, if not handled properly can lead to several complications. However good visual outcome is possible by careful planning of surgery. In our study Manual Small Incision Cataract Surgery is found to be cost effective and safe to do in patients with pseudoexfoliation. Limitations of this study includes small sample size, no control group for comparison and duration of follow up was only 3 months.

References

1. Madhavi C, Latha YS, Pyaraka D, Kumar MA. A Study on the Visual Outcomes and Complications of Cataract Surgery in the

- Rural Population of Indian Patients with Pseudo exfoliation. *Indian J Clin Exp Ophthalmol.* 2015;1(3):168.
2. Tarkkanen A, Kivela T, John G, Lindberg and the discovery of exfoliation syndrome. *Acta Ophthalmol Scand.* 2002 Apr;80(2):151–4.
3. Fontana L, Cossain M. Cataract surgery in patients with pseudoexfoliation syndrome. [cited 2018 Nov 16]; Available from: <https://www.dovepress.com/cataract-surgery-in-patients-with-pseudoexfoliation-syndrome-current-u-peer-reviewed-fulltext-article-OPHTH>
4. Conway RM, Schlötzer-Schrehardt U, Kühle M, Naumann GO. Pseudoexfoliation syndrome: pathological manifestations of relevance to intraocular surgery. *Clin Experiment Ophthalmol.* 2004 Apr 8;32(2):199–210.
5. Wang W, He M, Zhou M, Zhang X. Ocular Pseudoexfoliation Syndrome and Vascular Disease: A Systematic Review and Meta-Analysis. *PLOS ONE.* 2014 Mar 25;9(3):e92767.
6. Akarsu C, Ünal B. Cerebral haemodynamics in patients with pseudoexfoliation glaucoma. *Eye.* 2005 Dec;19(12):1297–300.
7. Naseem A, Khan S, Khan MN, Muhammad S. Cataract Surgery in Patients with Pseudoexfoliation. :6.
8. Shingleton BJ, Yang Y, O'Donoghue MW. Management and outcomes of intraocular lens dislocation in patients with pseudoexfoliation. *J Cataract Refract Surg.* 2013 Jul 1;39(7):984–93.
9. Mansour AM, Antonios RS, Ahmed IIK. Central cortical cleanup and zonular deficiency. *Clin Ophthalmol Auckl NZ.* 2016 Oct 4;10:1919–23.
10. Dwivedi NR, Dubey AK, Shankar PR. Intraoperative and Immediate Postoperative Outcomes of Cataract Surgery using Phacoemulsification in Eyes

- with and without Pseudoexfoliation Syndrome. *J Clin Diagn Res JCDR*. 2014 Dec;8(12):VC01–5.
11. Schlötzer-Schrehardt UM, Dörfler S, Naumann GO. Corneal endothelial involvement in pseudoexfoliation syndrome. *Arch Ophthalmol Chic Ill* 1960. 1993 May;111(5):666–74.
 12. Klamann MKJ, Gonnermann J, Maier A-KB, Ruokonen PC, Torun N, Jousen AM, et al. Combined clear cornea phacoemulsification in the treatment of pseudoexfoliative glaucoma associated with cataract: significance of trabecular aspiration and ab interno trabeculectomy. *Graefes Arch Clin Exp Ophthalmol*. 2013 Sep 1;251(9):2195–9.
 13. Naumann GOH, Schlötzer-Schrehardt U. Keratopathy in pseudoexfoliation syndrome as a cause of corneal endothelial decompensation. *Ophthalmology*. 2000 Jun 1;107(6):1111–24.
 14. Rand Allingham. *Shields Textbook of Glaucoma*. Sixth ed. Gurgaon, India: Wolters Kluwer; 2012. 248–261 p.
 15. Elias EK, Sathish G, Narayaniyamma V. Gonioscopic features of pseudoexfoliation syndrome and its relation with glaucoma. *Kerala J Ophthalmol*. 2018;30(2):112.
 16. Jawad M, Nadeem A, Khan A ul H, Aftab M. Complications of cataract surgery in patients with pseudoexfoliation syndrome. *J Ayub Med Coll Abbottabad JAMC*. 2009 Jun;21(2):33–6.
 17. Schlötzer-Schrehardt U, Naumann GOH. A Histopathologic Study of Zonular Instability in Pseudoexfoliation Syndrome. *Am J Ophthalmol*. 1994 Dec 1;118(6):730–43.
 18. Malyugin B. Cataract surgery in small pupils. *Indian J Ophthalmol*. 2017;65(12):1323.
 19. Sathish, D N P, Srivastava N, Acharya A, Afshan R, Johnson S, et al. Management of intraoperative complications and visual outcome in patients with pseudoexfoliation syndrome. *J Evol Med Dent Sci*. 2014 Aug 25;3(38):9829–36.
 20. Sufi AR, Singh T, Mufti AA, Rather MH. Outcome of Phacoemulsification in patients with and without Pseudoexfoliation syndrome in Kashmir. *BMC Ophthalmol*. 12(1):2–5.
 21. Kuchle M, Amberg A, Martus P, Nguyen N, Naumann G. Pseudoexfoliation syndrome and secondary cataract. *Br J Ophthalmol*. 1997 Oct;81(10):862–6.
 22. Naumann GO, Schlötzer-Schrehardt U, Kuchle M. Pseudoexfoliation syndrome for the comprehensive ophthalmologist. *Intraocular and systemic manifestations*. *Ophthalmology*. 1998 Jun;105(6):951–68.
 23. Jacob S, Agarwal A, Agarwal A, Agarwal S, Patel N, Lal V. Efficacy of a capsular tension ring for phacoemulsification in eyes with zonular dialysis. *J Cataract Refract Surg*. 2003 Feb 1;29(2):315–21.