



### Original Article

## Evaluation of p16 and HER-2/neu expression in Adenocarcinoma of uterine cervix- A study from tertiary health care center

Authors

**Dr Shalini Tripathi<sup>1</sup>, Dr Prakriti Shukla<sup>2\*</sup>, Dr Rashmi Chaturvedi<sup>3</sup>, Dr Sonia Luthra<sup>4</sup>**

<sup>1</sup>Resident, Department of Pathology, Hind Institute of Medical Sciences, Barabanki, Uttar Pradesh, India

<sup>2</sup>Assistant Professor, Department of Pathology, Hind Institute of Medical Sciences, Barabanki, Uttar Pradesh, India

<sup>3</sup>Professor, Department of Pathology, Hind Institute of Medical Sciences, Barabanki, Uttar Pradesh, India

<sup>4</sup>Professor, Department of Obstetrics and Gynaecology, Hind Institute of Medical Sciences, Barabanki, Uttar Pradesh, India

\*Corresponding Author

**Dr Prakriti Shukla**

Assistant Professor, Department of Pathology, Hind Institute of Medical Sciences, Barabanki, Uttar Pradesh, India

### Abstract

**Background:** Cervical cancer is the most common cancer in women worldwide with current knowledge showing rising trends of adenocarcinoma over Squamous cell carcinoma. They are more aggressive with relatively worse prognosis. Thus, to improve the overall disease free duration, a novel diagnostic and therapeutic immunomarker is required. The present study aims to evaluate the significance of p16 and HER-2/neu expression in patients of adenocarcinoma cervix.

**Material and Methods:** A Prospective study on 33 cases of adenocarcinoma cervix diagnosed on resected specimens as well as core biopsies was conducted from January 2019 to December 2019. All relevant clinical data was retrieved from Institute's electronic medical record system. Histopathological examination and Immunohistochemistry using p16 and HER-2/neu antibodies were performed on all formalin fixed paraffin embedded tissues.

**Results:** A total of 33 cases of adenocarcinoma cervix were observed in the present study. Positive p16 expression with variable intensity was noted in all the cases. HER-2/neu was strongly expressed in only 4 cases (12%) of Adenocarcinoma cervix. However, positivity was associated with all cases showing parametrial extension and all these cases were histologically diagnosed as high grade. Although statistically significant correlation between HER-2/neu expression, stage of tumor, presence of lympho-vascular invasion and nodal metastasis could not be established but cases with high grade of the tumor and parametrial extension did show strong immunoreactivity with HER-2/neu oncoprotein.

**Conclusion:** To conclude, p16 positivity was observed in all cases of adenocarcinoma cervix but role of Her2/neu is still debatable and needs further studies with larger sample size to establish its significance.

**Keywords:** Adenocarcinoma cervix; p16; HER-2/neu; Prognosis.

## Introduction

Cervical cancer is the fourth most common malignancy in women worldwide and a major cause of morbidity and mortality particularly in developing countries. Eighty four percent of the cervical cancer cases and deaths occur in developing countries because of socioeconomic challenges, pattern of health care delivery, and social factors. Epidemiological and molecular analysis have shown that human papillomavirus (HPV) infection is the most significant factor for cervical carcinogenesis.<sup>1</sup> Recently, the incidence of cervical adenocarcinoma is increasing over squamous cell carcinoma in young women. Adverse prognosis with early local extension and lymph node metastasis along with resistance to therapy are the major issues that necessitate their early detection and management. Therefore, search for a novel, useful diagnostic marker and therapeutic target is the need for today to meet this concern.<sup>2</sup>

Detection of HPV in adenocarcinoma poses a technical troubleshoots due to low viral load in these lesions as glandular cells do not support productive HPV infection. Highly sensitive polymerase chain reaction technique proved HPV involvement in the pathogenesis of three most common histologic subtypes of adenocarcinoma, viz, endocervical, endometrioid, and intestinal variants.<sup>3-5</sup> Diffuse positivity with p16 in the cervix can be regarded as a surrogate marker for high-risk human papillomavirus (HPV) infection. In glandular lesions, p16 is useful, as part of a panel, in the distinction between adenocarcinoma in situ (diffusely positive) and benign mimics, including tubo-endometrial metaplasia and endometriosis, which are usually p16-negative or focally positive. In the past, p16 has been used in combination with other immunomarkers to distinguish between cervical adenocarcinoma (diffuse positivity) and an endometrioid-type of endometrial adenocarcinoma (negative or focally positive).<sup>6</sup>

HER-2/neu (c-erbB-2) protooncogene is a gene located on chromosome 17q21 that codes a transmembrane growth factor receptor protein with tyrosine kinase activity.<sup>7</sup> Its variable expression has been detected in cervical cancers ranging from 8% to 77% as evaluated by various techniques and is related to worse prognosis; its blockade could potentially have therapeutic significance. The present study was conducted with the aim to evaluate the expression of p16 and HER-2/neu in adenocarcinoma of uterine cervix and their correlation with histological type, grade of tumor and clinical stage.

## Material and Methods

A prospective assessment of 33 patients lying within the reproductive age group was performed from January 2019 to December 2019 in the Department of Obstetrics and Gynaecology, Hind Institute of Medical Sciences, Barabanki. All relevant clinical data including age, socioeconomic status, clinical presentation, staging, tumour grade, lymph-node status, parametrial extension, pelvic extension and lympho-vascular invasion was recorded from electronic medical record. Histopathological and Immunohistochemical evaluation including p16 and HER-2/neu was done in each case. Immunohistochemistry was performed on 3-4m-thick sections taken on poly-L-lysine-coated slides. Antigen retrieval was performed by heating the sections in citrate-buffer at pH 6.0 using microwave oven.

## Scoring of p16 staining

The p16 immunostaining was performed on 3 $\mu$ m sections from paraffin blocks by means of a commercially available kit (Dako Cytomation, Milan, Italy). Nuclear as well as cytoplasmic reactivity was considered positive. Staining intensity was graded as follows:

SCORE	STAINING
0	No staining
1	1-25 % of cells staining
2	26-50 % of cells staining
3	51-75 % of cells staining
4	76-100 % of cells staining

**Scoring of HER-2-neu staining**

Monoclonal antibody NCL-CB11 (Novocastra Laboratories) was used for HER-2/neu detection in 1:40 dilution by standard streptavidin-biotin peroxidase method. A positive reaction was taken as crisp golden brown membranous and cytoplasmic staining. Intensity of staining was graded as per the food and drug administration (FDA) scoring system:

Staining Pattern	Score	HER-2/neu
No staining or weak membrane staining in < 10% of tumor cells	0	Negative
Weak membrane staining in >10% of tumor cells	1	Negative
Moderate membrane staining in > 10% of tumor cells	2	Positive
Strong membrane staining in > 10% of tumor cells	3	Positive

**Statistical Analysis**

Statistical analysis was performed using SPSS version 17. Expression of p16, HER-2-neu and their correlation with various factors was calculated using Pearsons Chi-square test. P value <0.05 was taken as statistically significant.

The study was conducted after obtaining approval from the Institutional Ethical Committee.

**Results**

A total of 33 cases of adenocarcinoma of uterine cervix were observed in our study. Out of these cases, 15 (45%) were hysterectomy specimens and 18 (55%) were cervical biopsies. Amongst 33 cases, 18 (55%) were of Endocervical type, 5 cases (15%) were of Adenocarcinoma, NOS type (Fig-1(a)), 4 cases (12%) each of Papillary and Endometrioid type, and one case (03%) each of Signet ring type (Fig-1(b)) and Adenosquamous. (Fig-1(c))

Amongst 33 cases, 14 (42%) cases were in the age range of 40- 55 years of age, 14 (42%) cases in 56 -70 years of age, 4 (12%) cases were below 40 years of age and 1 (03%) case was 73 years of age. Mean age of presentation was 53 years. Majority of the cases (69%) were in the post menopausal group. Most common clinical

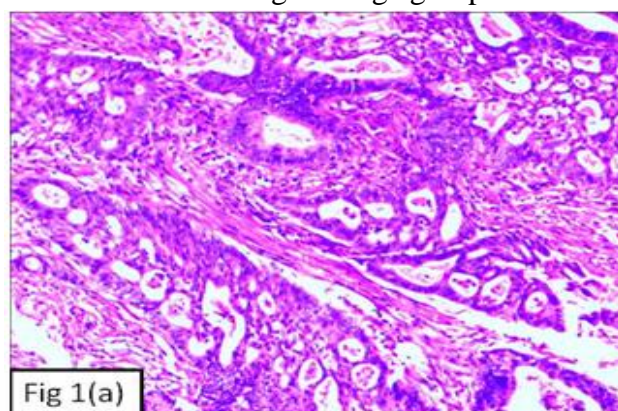
presentation was bleeding per vagina (99%) followed by white discharge (72%) and 2 cases (6%) additionally presented with the complaint of prolapsed uterus.

Out of 33 cases, p16 expression with a score of 4+ was seen in 29 cases (88%) (Fig-2(a)), score 3+ was observed in 2 cases (6%), score of 2+ and 1+ was seen in one case (3%) each. Expression of HER-2/neu with a score of 3 + was identified in one case (3%) (Fig-2(b)), score of 2+ was observed in 3 cases (9%) and negative score was noticed in 29 cases (88%). Thus, total cases with positive (score 2 and score 3) HER-2/neu expression was observed in 4 cases (12%) and all cases were of endocervical type adenocarcinoma. Nodal metastasis was seen in 8 cases (24%) and all these cases were strongly positive for p16 and only one case showed HER-2/neu positivity (P value >0.5).

Lympho-vascular invasion was seen in 6 cases (18%) with all cases showing strong p16 positivity and 4 cases (12%) showed positivity with HER-2/neu (P value <0.5).

Parametrial extension was seen in 11 cases (33%), out of which 3 cases (27%) showed a positive HER-2/neu expression (P value <0.5).

In the present study, 13 cases (39%) were in stage I, 11 cases (33%) were in stage II and 9 cases (27%) were in higher stage (Stage III + Stage IV) group. HER-2/neu positivity was seen in 15% of the cases in stage I, 9% of the cases in stage II and 12% of the cases in higher stage group.



**Figure-1(a):** Photomicrograph showing adenocarcinoma cervix, usual type with numerous variable sized glands (H&E, 10X)



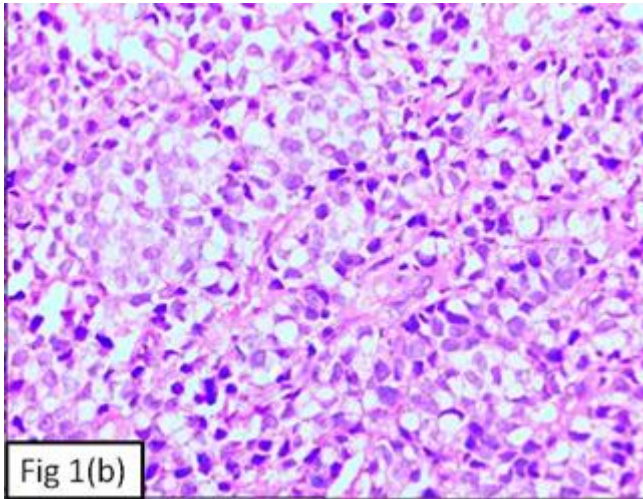


Fig 1(b)

**Figure-1(b):** Photomicrograph showing signet ring cell carcinoma of the cervix (H&E, 10X)

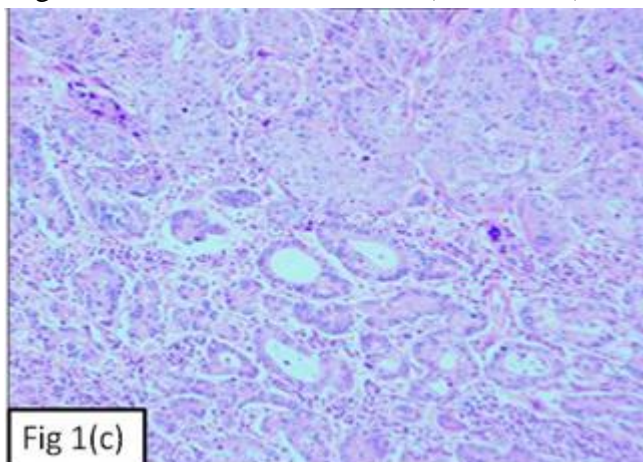


Fig 1(c)

**Figure-1(c):** Photomicrograph showing adenosquamous carcinoma of the cervix (H&E, 10X)

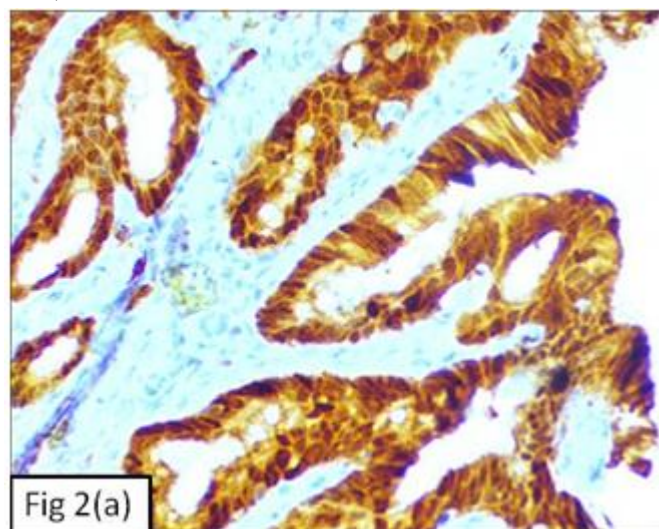


Fig 2(a)

**Figure-2(a):** Photomicrograph showing strong p16 positivity in the tumour cells (IHC, 20X)

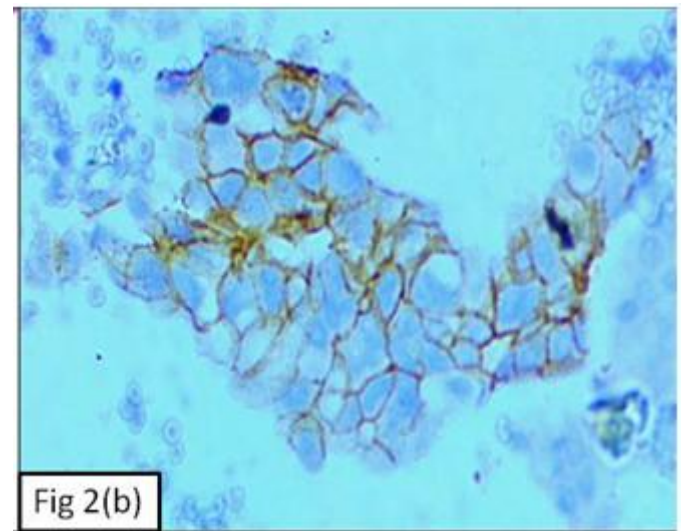


Fig 2(b)

**Figure-2(b):** Photomicrograph showing positive HER-2/neu expression of the tumour cells (IHC, 40X)

### Discussion

Carcinoma cervix is the second most common cancer in women aged between 15 to 44 years with an estimated incidence of 5,70,000 new cases as observed in 2018 (84% of the new cases worldwide).<sup>8</sup> In the present study, a total of 33 cases of adenocarcinoma cervix were reported in duration of one year. However, in a study by Bodner et al., a total of 39 patients with histologically proven adenocarcinoma of uterine cervix were observed over a period of 12 years (1994-2006).<sup>9</sup> In another study by Ueda et al., 53 cases of cervical adenocarcinoma were obtained by surgical resections during a period of 8 years from 2004 to 2012.<sup>10</sup> Thus, the incidence of adenocarcinoma observed in our study was slightly higher than the other studies. The rising incidence in our set-up may be attributed to early hospital visits by the patients due to increasing awareness programs that are regularly conducted in this area.

In the present study, mean age of presentation was 53 years, with minimum age being 35 years and maximum age being 73 years which was similar to the findings observed by Aziz et al., with mean age of presentation being 51 years.<sup>11</sup> Most common presenting complaint was bleeding per

vagina followed by white discharge as was observed in a study by Young et al.<sup>12</sup>

Most common histological variant observed in our study was endocervical type of adenocarcinoma. All cases of adenocarcinoma cervix expressed p16 positivity with variation in intensity. We observed a significant relationship between histological diagnosis and percentage positive cells and reaction intensity of p16 which is in concordance with the findings of Narges et al.,<sup>13</sup> No significant correlation between p16 expression and clinicopathological parameters, such as tumor size, stage, histologic subtype or histologic grade was observed. Previous studies revealed p16 expression ranging from 49% to 73% in adenocarcinoma of uterine cervix. So far, p16 expression has been extensively studied only in cervical squamous cell carcinoma. The literature on cervical adenocarcinoma is limited and its prognostic relevance is still unclear.

The present study did not find any impact of p16 expression on disease free and overall survival of the patient which was in concordance with the observations made by Lu et al.,<sup>14</sup> who also found no correlation between lympho-vascular space invasion and p16 positive tumours. However, Bodner et al.,<sup>9</sup> detected a trend towards increased lympho-vascular space invasion in p16 positive tumors.

In the present study, out of 33 cases, HER-2/neu expression was seen in only 4 cases (12%) Comparing with other studies, it was seen that Sarwade et al.,<sup>15</sup> found 2+ positivity in 2/10 cases (20%), Gupta et al.,<sup>7</sup> found 11/13 cases (84%) showing strong positivity, Joseph et al.,<sup>16</sup> found all (100%) cases to be HER-2/neu positive. On the contrary, in a study by Sharma et al.,<sup>17</sup> none of the cases showed positivity with HER-2/neu oncoprotein.

Gupta et al.,<sup>7</sup> analyzed 65 cases of cervical carcinomas and reported a significant correlation between HER-2/neu expression and higher clinical stage of cervical carcinoma. In contrast, the present study did not find any statistically

significant association between HER-2/neu expression and clinical stage of the patient.

In the present study, Mandai et al.,<sup>18</sup> and Young et al.,<sup>12</sup> analyzed HER-2/neu expression in 39 and 74 cases of cervical adenocarcinoma respectively and reported that a significant correlation existed between HER-2/neu expression and lymph node metastasis. However, in the present study no significant correlation was seen between lympho-vascular invasion as well as nodal metastasis and HER-2/neu expression. Similar finding were observed by Joseph et al.,<sup>16</sup>

In the present study, all cases with parametrial extension showed positive HER-2/neu expression. All these cases were of high grade on histopathology. On the contrary, Gupta et al.,<sup>7</sup> did not find any significant statistical correlation between parametrial extension, higher grade of the tumour and positive HER-2/neu expression. This confrontation may be due to the less number of cases analyzed in the present study.

It is, now evident through the present study that although p16 is frequently expressed in adenocarcinoma of uterine cervix, expression of HER-2/neu is variable in these carcinomas. Due to limited number of cases, definitive conclusion regarding expression of HER-2/neu cannot be established. Therefore, further studies with significant correlation between positive HER-2/neu expression and histopathological parameters are required to be undertaken to resolve these discrepancies.

### Conclusion

To conclude, the present study observed p16 positivity in all cases of adenocarcinoma cervix with statistically significant relationship between histological diagnosis and percentage positivity and reaction intensity but its role as a prognostic marker is still debatable. In the present study, overall expression of HER-2/neu was relatively low in adenocarcinoma. However, positivity was associated with parametrial extension and high grade of the tumour. Thus, a statistically

significant correlation between HER-2/neu expression, stage of tumor, presence of lympho-vascular invasion and nodal metastasis could not be established. More promising results with larger sample size in future studies can help establish its prognostic significance in cases of adenocarcinoma cervix.

**Source of support:** None

**Conflict of interest:** None

## References

1. Arbyn M, Weiderpass E, Bruni L, de Sanjosé S, Saraiya M, Ferlay J, et al. Estimates of incidence and mortality of cervical cancer in 2018: a worldwide analysis. *Lancet Glob Health*. 2020; 8(2):e191-e203.
2. Ueda A, Takasawa A, Akimoto T, Takasawa K, Aoyama T, Ino Y, et al. Prognostic significance of the co-expression of EGFR and HER2 in adenocarcinoma of the uterine cervix. *PLoS ONE* 2017;12(8): e0184123.
3. Pirog EC, Lloveras B, Molijn A, Tous S, Guimerà N, Alejo M, et al. HPV prevalence and genotypes in different histological subtypes of cervical adenocarcinoma, a worldwide analysis of 760 cases. *Mod Pathol*. 2014 Dec; 27(12):1559-67.
4. Holl K, Nowakowski AM, Powell N, et al. Human papillomavirus prevalence and type-distribution in cervical glandular neoplasias: results from a European multinational epidemiological study. *Int J Cancer*. 2015; 137(12):2858–2868.
5. Kleter B, van Doorn LJ, Schrauwen L, et al. Development and clinical evaluation of a highly sensitive PCR-reverse hybridization line probe assay for detection and identification of anogenital human papillomavirus. *J Clin Microbiol*. 1999; 37(8):2508–2517.
6. Tringler B, Gup CJ, Singh M, et al. Evaluation of p16INK4a and pRb expression in cervical squamous and glandular neoplasia. *Hum Pathol*. 2004; 35:689–696.
7. Gupta N, Singh S, Marwah N, Kumar S, Chabra S, Sen R. HER-2/neu expression in lesions of uterine cervix: is it reliable and consistent? *Indian J Pathol Microbiol*. 2009; 52(4):482-85.
8. Bruni L, Albero G, Serrano B, Mena M, Gómez D, Munoz J, et al. ICO/IARC Information Centre on HPV and Cancer (HPV Information Centre). Human Papillomavirus and Related Diseases in the World. Summary Report 17 June 2019.
9. Bodner K, Laubichler P, Kimberger O, Czerwenka K, Zeillinger R, Bodner-Adler B. Expression of p16 protein and epidermal growth factor receptor in patients with adenocarcinoma of the uterine cervix: an immunohistochemical analysis. *Arch Gynecol Obstet*. 2011;283: 611–616.
10. Ueda A, Takasawa A, Akimoto T, Takasawa K, Aoyama T, Ino Y, et al. Prognostic significance of the co-expression of EGFR and HER2 in adenocarcinoma of the uterine cervix. *PLoS ONE* 2017; 12(8): e0184123.
11. Aziz N, Yousfani S. Pattern of presentation of cervical carcinoma at Nuclear Institute of Medicine and Radiotherapy, Pakistan. *Pak J Med Sci* 2013; 29(3):814-817.
12. Young RH, Scully RE. Villoglandular papillary adenocarcinoma of the uterine cervix: a clinicopathologic analysis of 13 cases. *Cancer* 1989; 63(9):1773–1779.
13. Nargesh Izadi-Mood, Kourosch Asadi, Hadi Shojaei. Potential diagnostic value of p16 in premalignant and malignant cervical lesions. *J Res Med Sci*. 2012; 17(5):428-433.



14. Lu X, Toki T, Konishi I, Nikaido T, Fujii S. Expression of p21WAF1/CIP1 in adenocarcinoma of the uterine cervix. A possible marker of a favourable prognosis. *Cancer* 1988; 82(12):2409–2417.
15. Sarwade Pramod, PatilSunita, BinduRajan. Immunohistochemistry study for HER-2/neu expression in lesions of uterine cervix. *Int J Cur Res Rev* 2016; 8(13):50-57.
16. Joseph T and Raghuv eer CV. HER-2/neu expression in cervical intraepithelial neoplasia and cervical carcinoma. *International Journal of Biomedical and Advance Research* 2015; 6(01):47- 52
17. Sharma N, Kaushik A, Sumanashree, Sharma U. Evaluation of Her-2 neu Over Expression in Morphological Variants of Cervical Carcinoma, 2016;3(2):A207-A213.
18. Mandai M, Konishi I, Koshiyama M, Komatsu T, Yamamoto S, Nanbu K, et al. Altered expression of nm23-H1 and c-erb B-2 proteins have prognostic significance in adenocarcinoma but not in squamous cell carcinoma of the uterine cervix. *Cancer* 1995;75:2523-9.