



Prospective Study on role of Endoscopy in Thyroidectomies in Thyroid Nodules

Authors

Prof. Dr Arvind Ghanghoria, Dr Rajkumar Mathur, Dr Hiteshwari Baghel,

Dr Deepika Uike

Corresponding Author

Dr Deepika Uike

Email: drdeepika0901@gmail.com

Abstract

Introduction: Endoscopic thyroidectomy is in high demand as a newer surgical technique in today's era where dissection of the gland is totally performed with an endoscope. Thyroidectomies performed by open method are effective and safe, but it involves transverse incision on the neck measuring 9-10 cm in length. These thyroid disorders are quite common among women and the scars due to incision are cosmetically unacceptable. Also, it is a very invasive procedure, causing the serious traumas at times.

Aims & Objectives: 1) To assess the efficacy of endoscopic thyroidectomy in solitary and multiple thyroid nodules. 2) To assess the feasibility and difficulty in endoscopic thyroidectomy. 3) To assess the technical, cosmetic & safety benefits of this technique. 4) To assess the efficacy of trans axillary and Trans sternal approach. 5) To assess the complication of procedure.

Methodology: This study includes 30 cases of endoscopic thyroidectomy done for solitary thyroid nodules. All cases of thyroid nodules in dept. of surgery, M.G.M medical college and M.Y.H. Hospital, Indore were included.

Results: Endoscopic approach definitely scores well over open approach. It is Anatomically and biologically sound, Reproducible, Least complications, Short learning curve, Easy to teach, learn and practice, Cost effective, Best cosmetic and function results.

Conclusion: Endoscopic approach, due to its promising results, certainly scores well over open approach. Also, replicability is higher. This approach with its safe, effective and with excellent cosmetic results is certainly the field of interest of the upcoming surgical era.

Keywords: Endoscopic surgery, Thyroid, Cosmesis.

Introduction

Thyroidectomy is a passion for surgeons but a very high mortality rate after total thyroidectomy challenged 19th century surgeons. Endoscopic thyroidectomy is in high demand as a newer surgical technique in today's era where dissection of the gland is totally performed with an endoscope. Thyroidectomies performed by open method are effective and safe, but it involves transverse incision on the neck measuring 9-10 cm in length^[1]. Since Gagner first introduced endoscopic parathyroidectomy in 1996^[2],

endoscopic thyroidectomy has made much progress. These thyroid disorders are quite common among women and the scars due to incision are cosmetically unacceptable. Also, it is a very invasive procedure, causing the serious traumas at times. incision line sometimes may develop in to dark scars, hypertrophic scar or keloid and may lead to paresthesia and hyperesthesia. The minimally invasive thyroid procedures can be subdivided into three subgroups:

- (1) Endoscopic surgery by giving a small incision in the lateral side of neck
- (2) Video-assisted methods using a central incision
- (3) Range of endoscopic methods.^[3-5]

In this study we have reviewed our experience of endoscopic thyroidectomy through transaxillary approach. We have conducted this study to assess the safety, feasibility and complication of endoscopic thyroidectomy surgeries.

Aims & Objectives

- 1) To assess the efficacy of endoscopic thyroidectomy in solitary and multiple thyroid nodules.
- 2) To assess the feasibility and difficulty in endoscopic thyroidectomy.
- 3) To assess the technical, cosmetic & safety benefits of this technique.
- 4) To assess the efficacy of trans axillary and Trans sternal approach.
- 5) To assess the complication of procedure.

Materials & Methods

This study was approved by Ethical Committee and it was a part of post graduate dissertation in M.Y. Hospital, Indore. A total of 30 cases were studied.

Inclusion criteria

- size – thyroid nodule diameter < 50mm
- benign , cystic & solid lesions

Exclusion criteria

- size- thyroid nodule >50mm

- Thyroiditis
- Previous neck surgery
- Malignancy is relative contraindication

Duration of study: 2yrs

Type of study: observational study

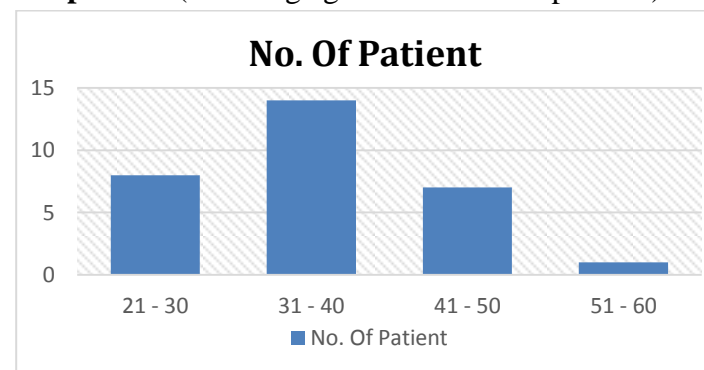
Methodology: Informed consent will be taken from all patients included in the study. All patients in study will undergo a detailed history taking including general examination. Records will be maintained. Record analysis will be done at the end of study period. Patient’s identity will be kept confidential. Lastly, the required procedure will be carried out.

Observations & Results

Table No. 01 Showing No. of Patient Age Wise

Age Group	No. Of patients(n=30)	%
21 – 30	08	26.66
31 – 40	14	46.66
41 – 50	07	23.33
51 – 60	01	3.33

Graph no 1 (Showing age distribution of patients)



2) Graph no 2 Showing distribution of chief complaints

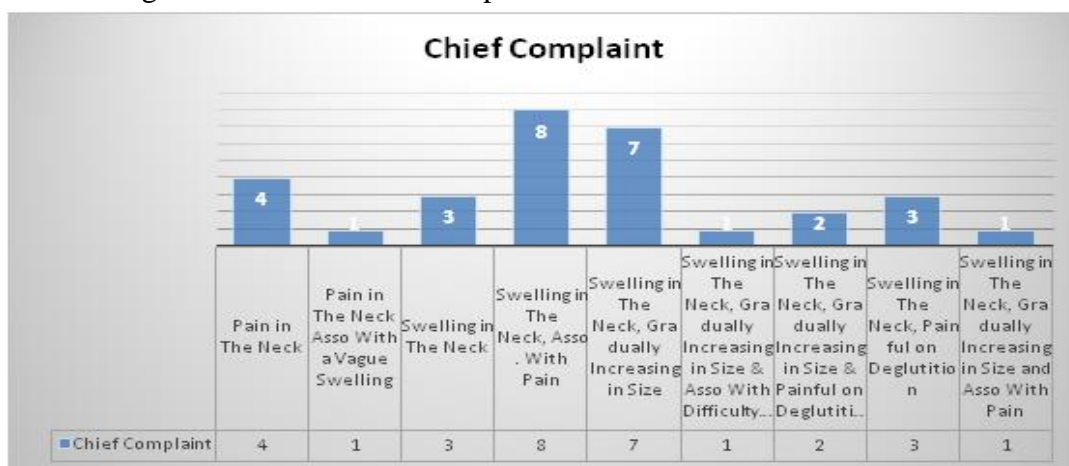

Table No. 02 (Showing Thyroid Profile in No of Patient)

S. NO.	THYROID PROFILE	NO. OF PATIENTS	%
1	EUTHYROID	26	86.66
2	INITIALLY SLIGHTLY HYPOTHYROID BUT CORRECTED BEFORE SURGERY	02	3.33
3	INITIALLY HYPERTHYROID BUT LATER CORRECTED BEFORE SURGERY	01	3.33
4	SLIGHTLY HYPOTHYROID	01	3.33

Pie chart (Showing USG Finding in No of Patient)

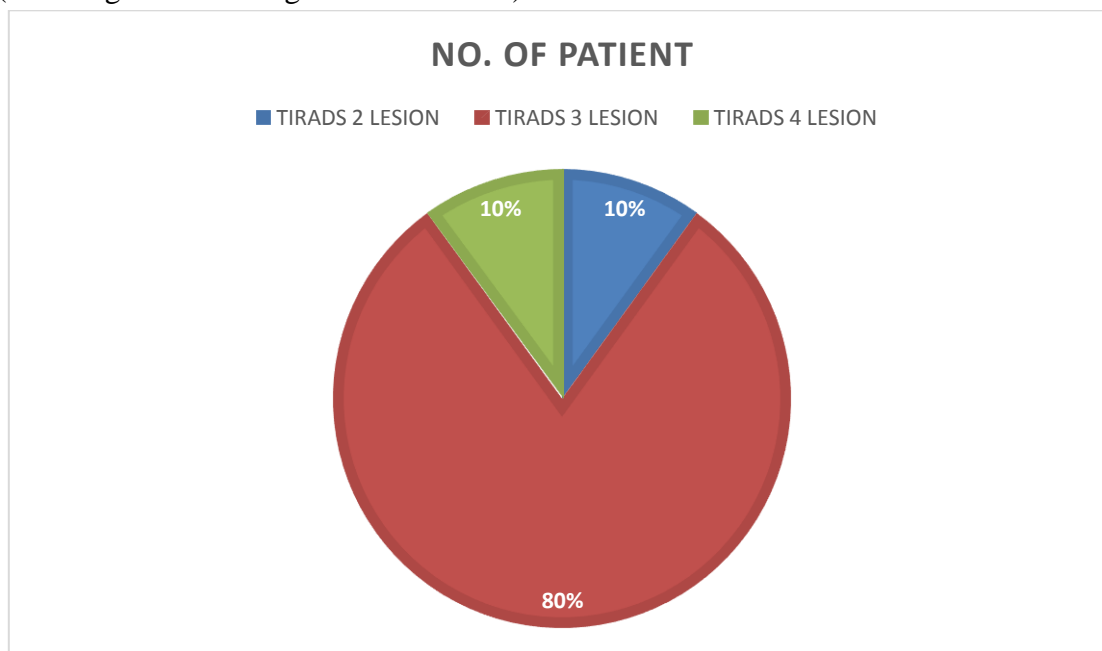


Table No. 03 (Showing FNAC Finding in No of Patient)

S. NO.	USG FINDING	NO. OF PATIENTS	%
1	Follicular Adenoma	19	63.33
2	Colloid Cyst	07	23.33
3	colloid adenoma	01	3.33
4	Atypical Hyperplasia	03	10
P-VALUE		0.000 (Insignificant)	

Table No.04: Distribution of patients according to type of surgery

Type of surgery	No. of patients
Transaxillary Thyroidectomy Converted to Open Due to Technical Errors	01
Transaxillary Thyroidectomy	25
Transaxillary Thyroidectomy But Intraop Converted to Open Thyroidectomy Due to Technical Errors	03
Transaxillary Thyroidectomy But Later Converted to Open Thyroidectomy Due to Technical Errors	01

Pie chart (Showing Nerve Identification in No of Patient)

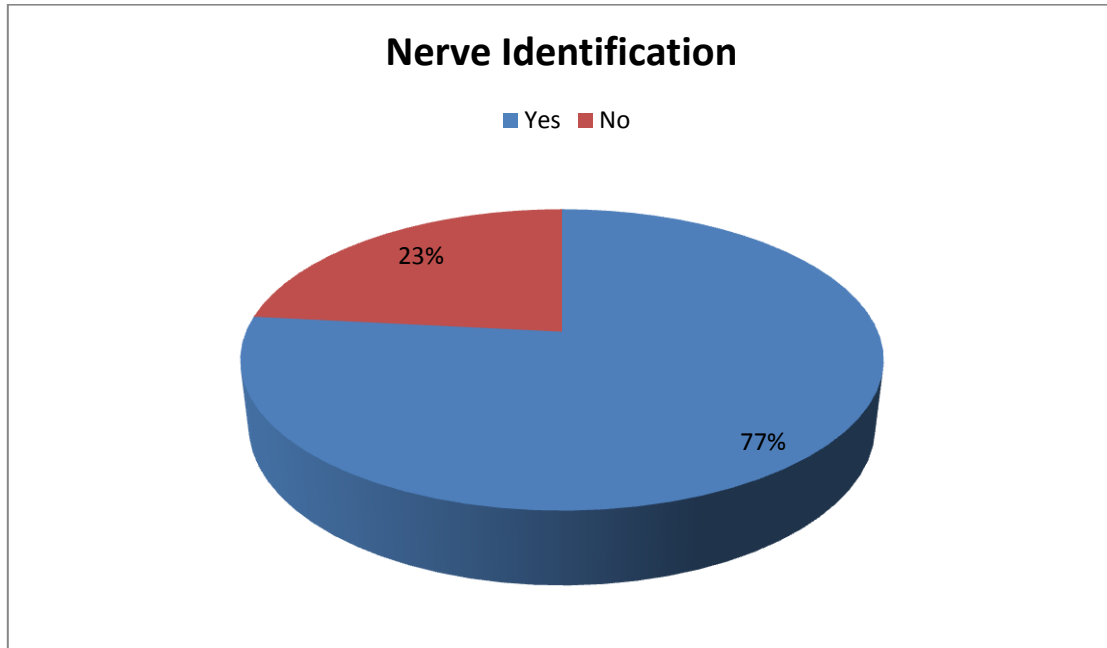


Table No. 05 (Showing Post OP Neck Swelling in No of Patient)

S. NO.	Post OP Neck Swelling	NO. OF PATIENTS	%
1	Present	16	53
2	Absent	14	47
P-VALUE		0.001 (Insignificant)	

Table No. 6 (Showing Hoarse Voice in No of Patient)

S. NO.	Hoarse Voice	NO. OF PATIENTS	%
1	Present	02	6.66
2	Absent	28	93.33
P-Value		0.000 (Insignificant)	

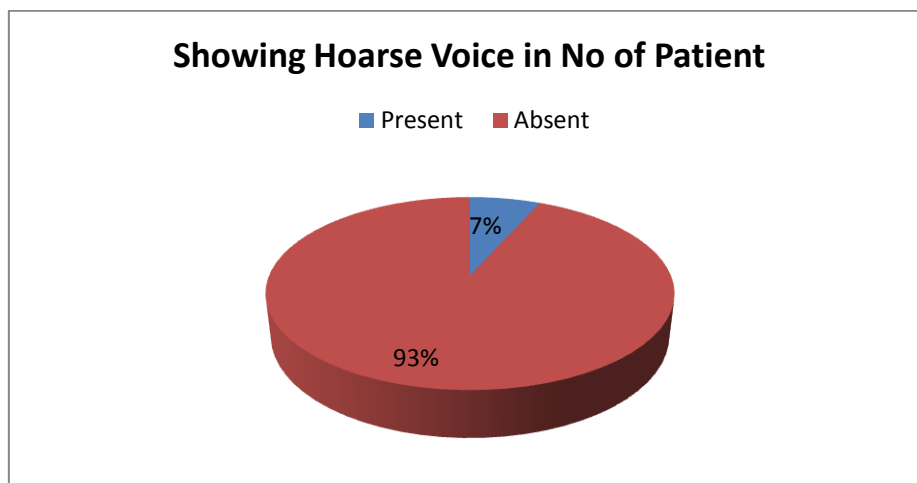
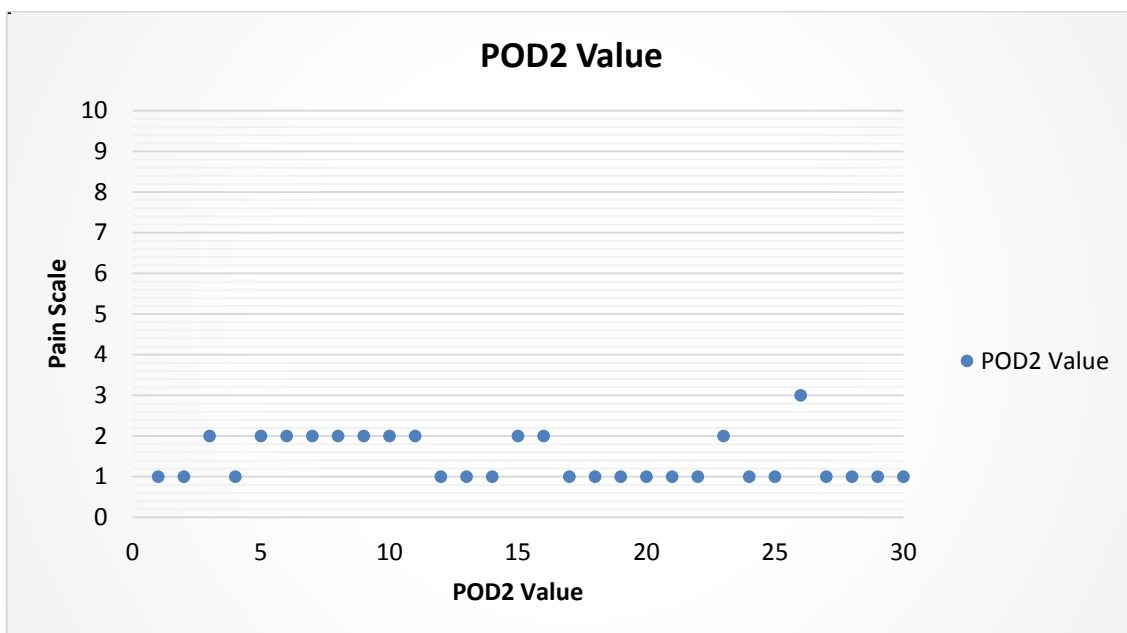
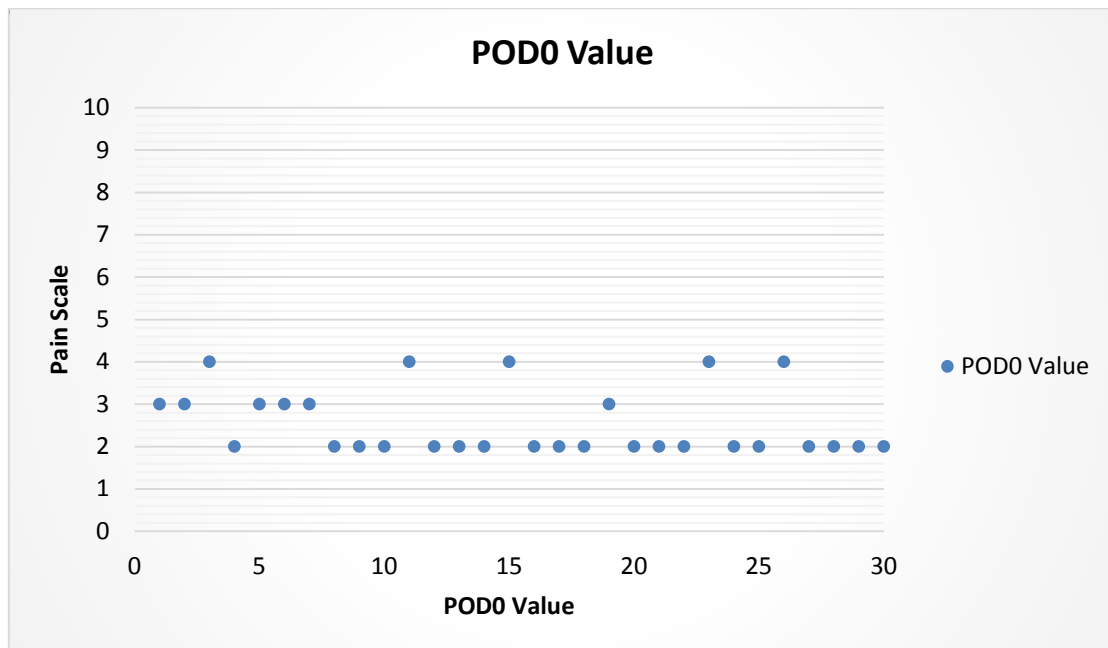


Table No. 7 (Showing Parathyroid Identification in No of Patient)

S. NO.	Parathyroid Identification	NO. OF PATIENTS	%
1	Yes	22	73.33
2	No	08	26.66
P-Value		0.011 (Insignificant)	

Table No. 8 showing Post OP Pain (on Pain Scale)

S. NO.	Mean Post OP Pain	Mean Value	P-Value
1	POD0	2.533	0.000 (Insignificant)
2	POD2	1.433	0.000 (Insignificant)
3	POD7	0.833	0.000 (Insignificant)



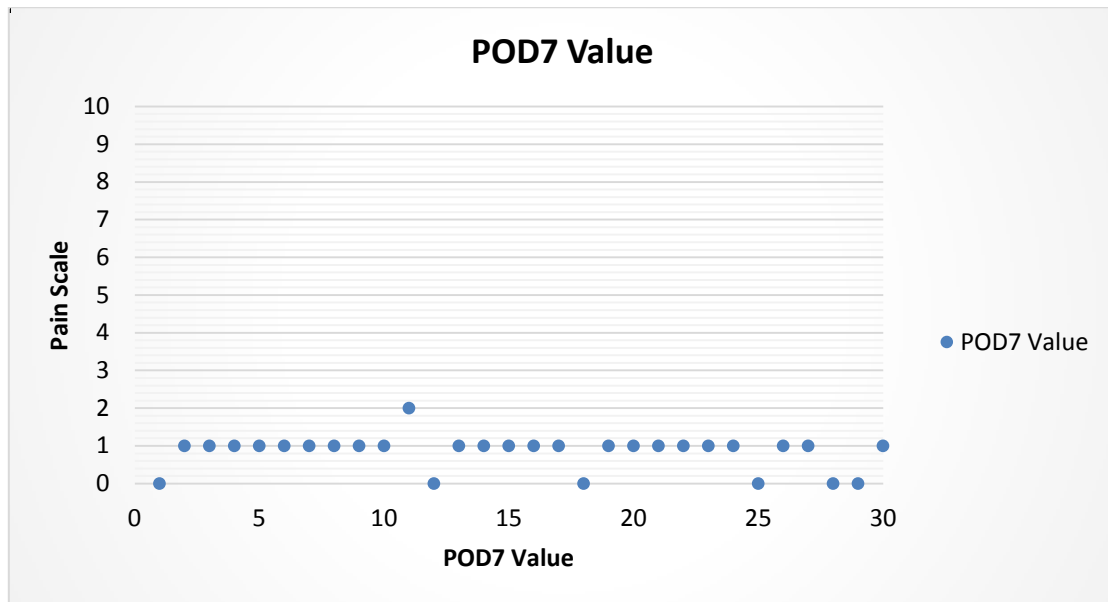


Table No. 9 (Showing Patient’s Satisfaction For Cosmesis in No of Patient)

S. NO.	Patient’s Satisfaction	NO. OF PATIENTS	%
1	Completely Satisfied	21	70
2	Satisfied	04	13.33
3	Slightly Dissatisfied	01	3.33
4	Dissatisfied	04	13.33
P-Value		0.000 (Insignificant)	

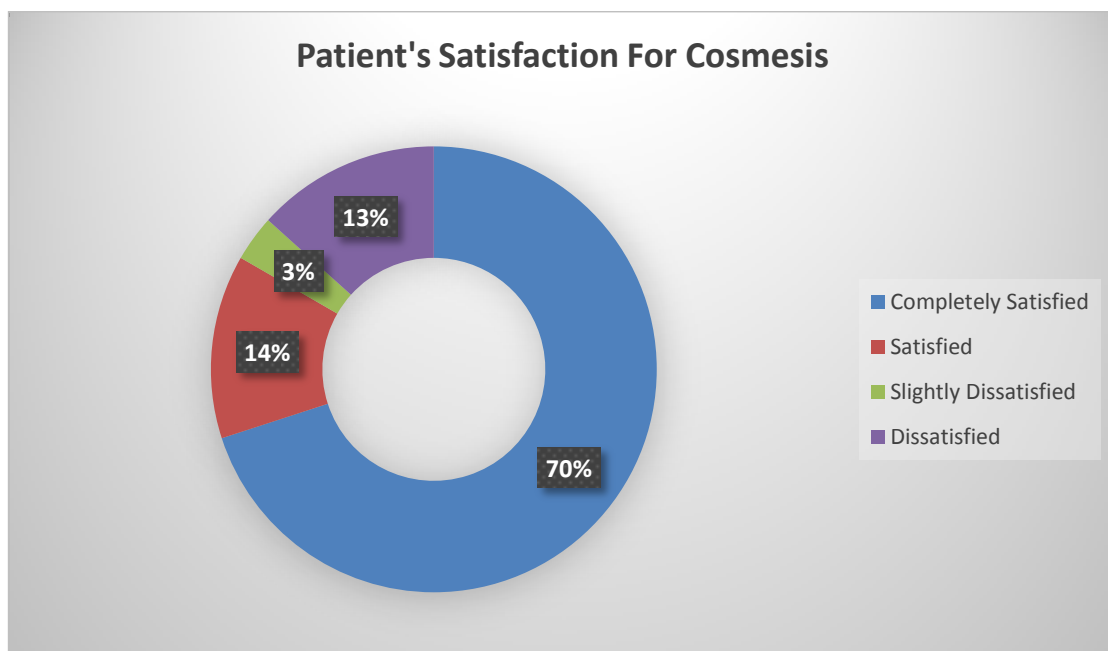


Table No. 10 (Showing Histopathology Report in No of Patient)

S. NO.	HISTOPATH REPORT	NO. OF PATIENTS	%
1	Colloid Adenoma	01	3.33
2	Colloid Cyst	07	23.33
3	Follicular Adenoma	19	63.33
4	Medullary Carcinoma	01	3.33
5	Papillary Carcinoma	02	6.66

Discussion

This study was conducted amongst patients with thyroid nodule visiting MYH OPD. It will include prospective cases from July 2016 to 2018. Sample size was 30.

This Study was performed to assess the efficacy & complication associated with endoscopic thyroidectomy.

The majority of patients belong to age group 31 - 40 (46.66%). 14 patients belonged to the age group 31-40 least no. of patients were from the age group (51-60).

The chief complaints of the patients in this study has been summarized in graph no. 02.

Majority of the patients presented with swelling in the neck associated with pain (26.66%) or swelling alone which was gradually increasing in size (23.33%). 49.99% patients (15 patients) presented with either of the two complaints.

As far as the thyroid profile is concerned most of the patients euthyroid before surgery.

80% of the patients were found to have TIRADS-3 lesion on USG. P-value is 0.00. This is a insignificant finding.

Pre-Operative imertigation also included FNAC of thyroid nodule 63.99% patients were found to have follicular adenoma as FNAC.

Out of the 30 patients, 25 patients underwent transaxillary thyroidectomy. While in remaining 05, due to certain technical errors, the procedure commented into an open procedure.

Intra-Operative nerve identification was possible in 23 patients (76%). P-value is 0.003. This is a insignificant finding this suggests the low rate of nerve injury is endoscopic thyroidectomies.

Hoarseness of voice was seen only in 02 patients. Even in those two patients, hoarseness voice was transient& subsided in few days.

Other complication that were observed in this study were post operative neck swelling, facial swelling & axillary numbness 53% developed post of neck swelling & 40 developed facial swelling following surgery.

Axillary numbness was seen only in 23.33% of patients.

In our study, post operative pain was measured on pain scale having reading from 0-10.

The mean reading of pain (on pain scale) on

POD0 - 2.53

POD2 - 1.43

POD7 - 0.83

The main variable that was observed in this study was patients satisfaction for cosmesis out of 30 patients, it were found to be completely satisfied after surgery (70%), 05 were satisfied

Conclusion

By means of this study, we have concluded that Endoscopic thyroidectomy is a highly efficacious novel technique of thyroid surgery for thyroid nodules. It is associated with less complications and lesser duration of hospital stay as compared to open approach. Also, the patient's satisfaction for cosmesis is the main achievement of this approach. There is no scar seen post operatively on front of neck. Cosmetic results have been excellent.

References

1. World J Surg (2008) 32:1325–1332 DOI 10.1007/s00268-008-9505-0
2. Clinical and Experimental Otorhinolaryngology Vol. 8, No. 2: 149-154, June 2015
3. Chalam CR, Rao KA, Praveen S. Minimally Invasive Thyroidectomy: A Review Article. Int J Sci Stud 2015;2(10):108-111.
4. Hegazy MA, Khater AA, Setit AE, Amin MA, Kotb SZ, El Shafei MA, et al. Minimally invasive video-assisted thyroidectomy for small follicular thyroid nodules. World J Surg 2007;31:1743-50.
5. Chung YS, Choe JH, Kang KH, Kim SW, Chung KW, Park KS, et al. Endoscopic thyroidectomy for thyroid malignancies: Comparison with conventional open thyroidectomy. World J Surg 2007;31:2302-6.