



A Study on Spinal Tuberculosis

Author

Dr Rahmat Ali*

Senior Consultant, Orthopedics Dept. combined District Hospital, Sant Kabir Nagar

Abstract

This paper is to depict the clinico-statistic and imaging example of STB and to survey the result of therapeutic treatment in the neighborhood setting. Spinal tuberculosis (Tubercular Spodylitis) is a typical extra pulmonary sign bookkeeping half of skeletal tuberculosis. We announced an instance of spinal tuberculosis in a 27 years of age man with neurological indication with surprising right paravertebral incessant releasing sinus in the lower back locale. He was given torment on the upper dorsal and swelling in the lower back with spastic paraparesis with muscle review 3/5, misrepresented twitch with no tactile contribution in bring down appendages for 2 months. He was unintentionally depleted in careful outpatient office and in this way created interminable releasing sinus. X-ray dorsal area uncovered a dissolving injury C7/D1 level with paravertebral canker. A careful decompression without obsession of dorsal pedicle. Biopsy and Gene Xpert was done and affirmed as mycobacterium. Instantly after careful mediation in the upper dorsal level, releasing sinus steadily decimated and neurological review moved forward. At last in our nation: any patient with dorsolumbar paravertebral swelling neurological assessment of entire spine must be done before cut will diminish dreariness and mortality.

Keywords: *Dorsal spine, Tuberculous spondylodiscitis, Paravertebral swelling.*

Introduction

Tuberculosis (TB) is one of the most seasoned illnesses influencing humanity and has been found in skeletal stays from the antiquated mummies of Egypt and Peru.¹ The malady is caused by the bacillus *Mycobacterium tuberculosis*, and periodically by *Mycobacterium bovis*, and *Mycobacterium africanum*. It is the most widely recognized irresistible illness causing passings in people. TB is directly a worldwide pandemic with more than two billion individuals, equivalent to 33% of the total populace at present evaluated to be contaminated, with 8.8 million new TB cases recognized worldwide and 1.4 million passings annually.

Spinal tuberculosis (Tuberculous spondylitis additionally called Pott's spine or Pott's sickness) is a typical additional pneumonic sign of tuberculosis (TB), representing half of skeletal TB^[1]. Albeit spinal TB has turned out to be generally unprecedented in the development western world, the rate has been expanding in the third world. Since the side effects and the highlights of individual TB change incredibly, spinal TB is frequently misdiagnosed. Typically at least two bordering vertebrae are engaged with spinal tuberculosis due to haematogenous spread through one vertebral course encouraging two nearby vertebrae^[3,4]. Noncontiguous, different, remote inclusion of tuberculosis is moderately

uncommon. Flow look into demonstrates the rate of numerous level noncontiguous vertebral tuberculosis is 1.1%^[7]. We present an instance of spinal tuberculosis in 27-year-old man with neurological sign with bizarre paravertebral unending releasing sinus in the lower back locale.

Tuberculosis Spine Disease

Contribution of the spine is the second most regular appearance of tuberculosis disease. Something like 3% to 5% patients have spine involvement,¹ and this rate was accounted for to be higher in creating countries. Tuberculous spine illness has a high potency of causing incapacity and mortality, and a late finding even make a higher rate or more serious complications. In the beginning period of the infection, the clinical appearance (signs and neurological shortfalls) of the patients aren't specific. The fundamental pharmacologic drugs for M. tuberculosis are rifampin and isoniazid for 6 months Standard treatment for tuberculosis comprises of: rifampicin, isoniazid, ethambutol, and pyrazinamide for two months, took after by rifampicin and isoniazid for four months. A few specialists once in a while utilize oral dexamethasone for treatment of skeletal tuberculosis. Tragically, the adherence rate of patients taking the antituberculous chemotherapy is as yet a concern. Laboratory profiles and interpretations in skeletal tuberculosis the standard lab examinations for exploring bone contribution are antacid phosphatase and serum CRP. Leukocyte check is typically ordinary. Paleness and hypoalbuminemia are generally present in patients with skeletal tuberculosis with ailing health.

Diagnosis of Skeletal Tuberculosis

Conclusion of skeletal tuberculosis is set up by getting an example by spine or paravertebral biopsy with help of radiological examination or ultrasonography. Determination of additional spinal tuberculosis is made by looking at AFB from sputum or pleural liquid. Epidemiology of TB infection As indicated by the WHO,

tuberculosis is a particular ailment that causes the most astounding mortality in the world. It is evaluated that 33% of the world populace, which is around 2 billion people, are tainted with tuberculosis. The occurrence of tuberculosis in Singapore is around 44 for every 100,000 population. In the USA, Australia, and Sweden, the frequency of tuberculosis disease is under 10 for each 100,000 populace. In Japan, the rate of tuberculosis is 33 for every 100,000. Over 40% of tuberculosis disease worldwide is situated in South East Asia.^[11] It is assessed that there are three million new instances of tuberculosis contamination consistently, and around 10.7 million individuals were tainted with tuberculosis and HIV. The differential analysis of tuberculous spine infection in the elderly is metastasis of harm from different destinations. Histopathology analysis is expected to preclude this probability. The most well-known destinations of tuberculous spine infection are the lower fragment of thoracic vertebrae and lumbar vertebrae. Tuberculous spine sickness can once in a while be seen at the thoracic and cervical vertebrae, however the introduction is generally more severe. The role of surgical treatment in tuberculous spine disease Mix of careful treatment together with tuberculosis medicines offer a more fast change of neurological deficiencies and better result to patients with dynamic neurological deficits.^[14,16] Conservative or non-careful treatment is the treatment of decision just in situations where no neurological shortfalls were found.^[15,17]

Surgical treatment performed in this patient is the foremost methodology for debridement and fusion.^[20,21] M. tuberculosis only from time to time frame biofilm encompassing the metal embed contrasted and other pyogenic microorganism,^[22] so that a few specialists likewise play out a blend of spine instrumentation, either back instrumentation or foremost instrumentation after curettage and bone graft use. A solid steadiness could likewise be acquired by utilizing titanium confine as a reproduction exertion to the vertebral body.

Objectives

The essential goal of the examination was to depict the clinico-statistic and imaging example of STB in a progression of patients in the investigation setting. The auxiliary goal was to survey the treatment result of the malady inside the constrained assets.

Methodology

We selected all patients determined to have unequivocal or plausible STB from September 2006 to March 2010 (n=32) at Respiratory illness center, Teaching Hospital, Kandy.

Diagnosis of STB

The finding of STB was made in view of a blend of clinico-radiological and biochemical variables. The criteria for determination (changed from Ching-Yun Weng, et al 6) were as per the following; (1) Symptoms more than multi month length; (2) particular highlights on MR/CT imaging; (3) avoidance of elective spinal infection; (4) raised provocative markers or positive Mantoux testing or both. In the event that patients had just the above criteria, they were arranged as plausible STB; if likewise indicated corroborative microscopical or histopathological proof on examination of paraspinal suction or tissue biopsy when performed, they were ordered as unequivocal STB (Table 1). Both likely and unmistakable STB classifications were incorporated into this investigation, while others with conceivable STB, however did not satisfy the above analytic criteria were avoided.

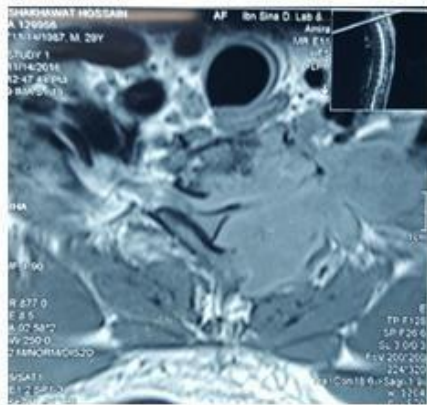
Data Acquisition

We evaluated the facility records and spinal pictures everything being equal. Quiet symptomatology, statistic points of interest, co-morbidities, past TB status, contact status and examination discoveries including weight, neurological intricacies and gibbus deformation at the season of conclusion were recorded. We likewise recorded the examination results including fiery markers, Mantoux perusing,

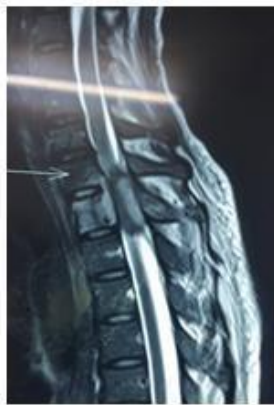sputum. status and imaging subtle elements. We reassessed all patients at a unique follow-up center.

Case Report

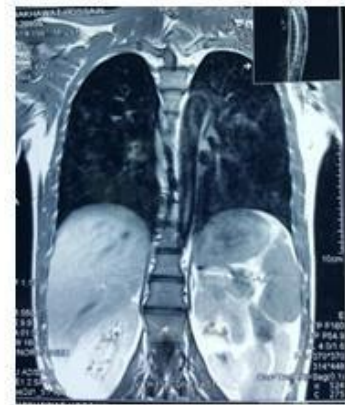
A multi year old man got conceded into DMCH in our neurosurgery office with protestations of dynamic shortcomings of both lower appendages for three weeks and a releasing sinus in the correct lower back. additionally griped of torment in the upper dorsal district for 15 days. He had lost some weight and furthermore had lost his craving for as long as two months. He didn't give any history of fever, night sweats, hack or haemoptysis. None of his relatives at any point experienced TB yet he once had a collaborator who was an analyzed instance of tuberculosis. On examination he was observed to be a young fellow of normal body manufactured. General examination uncovered that every one of the parameters were inside typical cutoff points. His lower appendages were spastic paraparesis with muscle control review of 3/5. Every one of the bastards were misrepresented in the lower appendages yet there was no clonus. Tangible assessment uncovered no anomalies. He had delicacy over the upper dorsal spine however no gibbus. There was an unhealthy injury over the correct lower dorsal locale which had swamp on top of it and serous release leaving it. He expresses that 2 (two) months back he had a privilege paravertebral swelling over the lower dorsal district and which was unduly depleted in the careful outpatient division with no earlier examinations. From that point forward he has been experiencing consistent dressing yet to no change. His ESR was 116 however chest X beam was negative for tuberculosis.



Pre operative MRI (Axial)

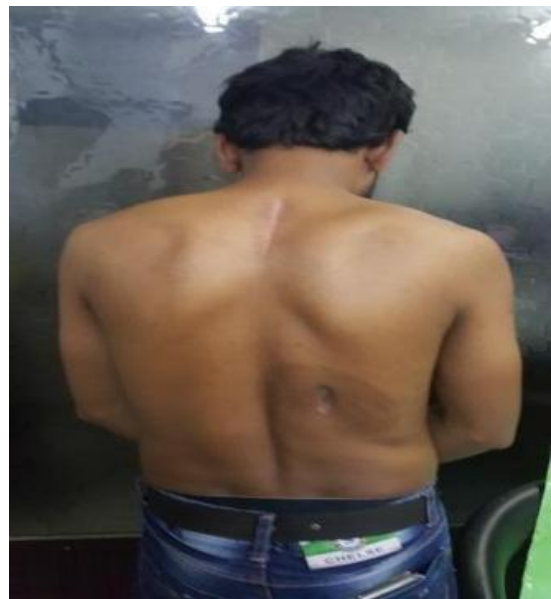

Pre operative MRI (Sagittal)



Pre operative MRI (Coronal)

X-ray of the spine uncovered an injury dissolving the D1 left hemilaminae at the C7-D1 level which was hypo extreme in T1 weighted picture and hyper exceptional in T2 recommending a ulcer. We investigated the sore by standard method and when we achieved the D1 lamina semisolid discharge like mushy material turned out. Laminectomy wasn't important as the injury had officially pulverized its greater part. Fluid discharge and garbage from ulcer depression were gathered and sent for both histopathology and geneXpert. Subsequent to emptying the hole we endeavored to expel the majority of the container in piecemeal mold. Enthusiastic saline water system was given and the injury was shut keeping up all haemostatic convention. Biopsy from the cavity divider uncovered granulomatous injury reliable with tubercular spondylitis. GeneXpert additionally identified mycobacterium tuberculosis which was not impervious to rifampicin in this way affirming our finding of spinal tuberculosis. Persistent was encouraged to begin hostile to koch treatment. Post operatively his Paraparesis enhanced and he began strolling with help. Presently following multi month post operatively the releasing sinus in the lower dorsal level has relatively mended and he is enhancing bit by bit with physiotherapy. Postoperative photograph of the patient



Analysis

Spinal tuberculosis is the consequence of hematogenous spread from an essential core interest. The discovery of essential concentration or instinctive tuberculosis is accounted for in the middle of 40% to half of cases^[5], while an Indian arrangement reports the recognition of essential concentration in just up to 12% of cases^[2]. In our patient, no essential center could be identified. The analysis of spinal TB has been founded on a mix of clinical and radiological discoveries. X-ray is thought to be the most exact as it takes into account distinguishing proof of bone pulverization as well as granulomatous tissue and tuberculomas, which might be not be clear on plain radiographs or CT. There are a few imaging discoveries suggestive of spinal TB. Diminished flag force of influenced bone and delicate tissues on T2-weighted pictures with a related thin edge

improvement of expanded power is a pathognomonic sign for caseating putrefaction or a chilly ulcer in TB^[6]. Despite imaging, affirmation of the infection requires biopsy showing corrosive quick bacilli on microscopy or disengaged culture of the life form. Interestingly with pneumonic TB, additional aspiratory TB injuries have a lower measure of bacilli, bringing about less precise outcomes from microscopy^[7]. GeneXpert PCR has been a viable indicative device for aspiratory TB and is presently thought to have high affectability and specificity for additional pneumonic TB too. Contrasted with culture, quality Xpert considers a more fast finding and more noteworthy affectability notwithstanding when little measures of bacilli are available, as it was For our situation.

Likewise with most different types of additional pneumonic TB, antitubercular chemotherapy is the backbone of treatment for spinal TB. Nonetheless, there is no institutionalized regimen or known ideal length of treatment. Treatment ought to at first incorporate isoniazid, rifampicin, pyrazinamide, and either etham butol or streptomycin and can be adjusted in view of consequences of weakness testing. Changing treatment lengths extending from 6 to year and a half have been accounted for^[7]. We exhorted our patient to finish the multi month administration. The preservationist approach with therapeutic treatment is favored for early ailment, however careful intercession might be expected to anticipate neurological outcomes. Neurosurgical mediations can consider remedy of distortions, canker debridement, spinal line decompression, or lasting spinal adjustment^[7].

Spinal TB has a fairly slippery course which frequently prompts more prominent analytic postponement. The nonattendance of fever, provocative changes, and established side effects additionally drives clinicians to rashly reject TB from their differential. Later finding of the infection has been related with a more terrible guess and a more noteworthy requirement for careful mediation. Despite the fact that advances

in MRI ought to expectedly enhance analysis time, the analytic postponement for spinal TB has remained stable. The course of treatment in our patient portrayed in this report demonstrates a few mix-ups which brought about that the determination of tuberculous spondylitis was made late. This can clearly occur in other created nations excessively^[4]. Since an event of tuberculosis is by and large not considered, the chest x- beam was thought little of, no cutting edge research facility tests were utilized before depleting the paravertebral ulcer, not in any case a solitary blood tally. Another genuine oversight was that the elements and indication of his illness which were average of TB passed unnoticed. Every one of these disappointments made pointless psychical pressure the patient and postponed the causal treatment. The case announced here demonstrated the unpredictability of analytic strategies important to uncover tuberculous spondylitis and the significance of clinical cautiousness against the expanding rate of spinal tuberculosis in our nation. In patients with a dorsolumbar paravertebral boil, tuberculous spondylitis ought to be suspected and exhaustive epidemiological, clinical and research facility examinations be done and proper treatment presented at the earliest opportunity.

Conclusion

Tuberculous spine malady remains a noteworthy issue of musculoskeletal tuberculosis contamination in South East Asia. Careful treatment is as yet the favored treatment joined with antituberculous chemotherapy for tuberculous spine ailment patients with myelopathy. In our foundation, the corpectomy debridement method together with combination with autologous (iliac) bone unite gives fulfilling results. In our nation, specialists tend to deplete abscesses without earlier examinations. Paravertebral ulcer ought to be depleted after appropriate whole spinal evaluation. This can in this manner keep the noteworthy neurological entanglements and great careful result can be

achieved. Considering the conclusion of TB and deliberately surveying hazard components can stay away from delays in its analysis and administration.

References

1. Donoghue HD, Spigelman M, Greenblatt CL, Lev-Maor G, Bar-Gal GK, Matheson C, et al. Tuberculosis: From ancient times to Robert Koch, as uncovered by old DNA. *Lancet Infect Dis* 2004; 4(9): 584-92.
2. Tuberculosis worldwide actualities 2011/2012. Geneva, World Health Organization 2012. (http://www.who.int/tb/productions/2011/factsheet_tb_2011.pdf. Gotten to 06.08.2012)
3. Watts HG, Lifeso RM. Current Concepts Review - Tuberculosis of Bones and Joints. *J Bone Joint Surg Am* 1996; 78(2): 288-99.
4. Pertuiset E, Beaudreuil J, Liote F, Horowitzky A, Kemiche F, Richette P, et al. Spinal tuberculosis in grown-ups. An investigation of 103 cases in a created nation, 1980– 1994. *Drug* (Baltimore) 1999; 78: 309-20.
5. National program for tuberculosis control and chest sicknesses. General manual for tuberculosis control. second ed. Service of Health, Sri Lanka: 2005.
6. Ching-Yun Weng, Chin-Yu Chi, Pai-Jun Shih, Cheng-Mao Ho, Po-Chang Lin, Chia-Hui Chouc, et al. Spinal tuberculosis in non-HIV contaminated patients: 10-year experience of a restorative focus in Central Taiwan. *J Microbiol Immunol Infect* 2010; 43(6): 464-9.
7. CDC—TB—Data and Statistics, Cdc.gov, 2016, <http://www.cdc.gov/tb/insights/default.htm>
8. C. Scott, H. L. Kirking, C. Jeffries, S. F. Cost, and R. Pratt, —Tuberculosis patterns—United States, 2014, *Morbidity and Mortality Weekly Report*, vol. 64, no. 10, pp. 265– 269, 2015
9. J. Bennett, R. Dolin, and B. M. Mandell, Douglas, and Bennett's Principles and Practice of Infectious Diseases, Elsevier Health Sciences, London, UK, 2014.
10. R. K. Garg and D. S. Somvanshi, —Spinal tuberculosis: a review, *The Journal of Spinal Cord Medicine*, vol. 34, no. 5, pp. 440– 454, 2011.
11. M. F. Ferrer, L. G. Torres, O. A. Ramírez, M. R. Zarzuelo, and N. Del Prado González, —Tuberculosis of the spine. A deliberate audit of case series, *International Orthopedics*, vol. 36, no. 2, pp. 221– 231, 2012.
12. M. R. Rasouli, M. Mirkoohi, A. R. Vaccaro, K. K. Yarandi, and V. Rahimi-Movaghar, —Spinal tuberculosis: conclusion and management, *Asian Spine Journal*, vol. 6, no. 4, pp. 294– 308, 2012J.
13. D. Colmenero, J. D. Ruiz-Mesa, R. Sanjuan-Jimenez, B. Sobrino, and P. Morata, —Establishing the finding of tuberculous vertebral osteomyelitis, *European Spine Journal*, vol. 22, no. S4, pp. S579– S586, 2013.
14. P. Merino, F. J. Candel, I. Gestoso, E. Baos, and J. Picazo, —Microbiological finding of spinal tuberculosis, *International Orthopedics*, vol. 36, no. 2, pp. 233– 238, 2012.
15. Medical Research Council. Therapeutic Research Council National Survey of Tuberculosis Notifications in England and Wales in 1983: qualities of ailment. *Tubercle* 1988;68: 19-32
16. Rezai A, Lee M, Cooper P, et al. Present day administration of spinal tuberculosis. *Neurosurgery* 1995;36:87-9
17. Jain A. Treatment of tuberculosis of the spine with neurologic inconveniences. *Clin Orthop* 2002;398:27-31

18. Fam A, Rubenstein J. Another take a gander at spinal tuberculosis. *J Rheumatol* 1993;20:1731-40
19. Pertuiset E, Beaudreui J, Liote F, et al. Spinal tuberculosis in grown-ups. An investigation of 103 cases in a created nation, 1980-1994. *Drug* 1999;78:309-20
20. Joint Tuberculosis Committee of The British Thoracic Society. Chemotherapy and administration of tuberculosis in the United Kingdom: suggestions 1998. *Thorax* 1988;53:536-48
21. American Thoracic Society. Communities for Disease Control and Prevention, Infectious Diseases Society of America. Treatment of tuberculosis. *Am J Respir Crit Care Med* 2003;167:603-62
22. Van Loenhout-Rooyackers J, Verbeek A, Jutte P. Chemotherapeutic treatment for spinal tuberculosis. *Int J Tuberc Lung Dis* 2002;6:29-65
23. Ahmadi J, Bajaj A, Destian S, Segall HD, Chi-Shing Z (1993) Spinal tuberculosis: atypical perceptions at MR imaging. *Radiology* 189(2):489-493
24. Griffith JF et al. (2002) Imaging of musculoskeletal tuberculosis: another take a gander at an old infection. *Clin Orthop Relat Res* (398): 32-39
25. Hasegawa K, Murata H, Naitoh K, Nagano A (2002) Spinal tuberculosis: report of an atypical introduction. *Clin Orthop Relat Res* (403): 100-103
26. Pande KC, Babhulkar SS (2002) Atypical spinal tuberculosis. *Clin Orthop Relat Res* (398):67-74
27. World Health Organization site: <http://www.who.int>
28. Chee CBE, James L. The Singapore tuberculosis end program: the initial five years. *Bull World Health Organ* 2003;81:217-21 Scientific Research Journal (SCIRJ), Volume I, Issue V, December 2011 ISSN 2201-2796
29. Dye C, Scheele S, Dolin P, Pathania V, Raviglione MC. Agreement articulation. Worldwide weight of tuberculosis: assessed occurrence, pervasiveness, and mortality by nation. WHO Global Surveillance and Monitoring Project. *JAMA* 199;282:677-86
30. Turgut M: Spinal tuberculosis (Pott's malady): its clinical introduction, careful administration, and result. An overview ponder on 694 patients. *Neurosurg Rev* 2001, 24:8-13
31. Kotil K, Alan MS, Bilge T: Medical administration of Pott sickness in the thoracic and lumbar spine: a review clinical examination. *J Neurosurg Spine* 2007, 6:222-228
32. Park DW, Sohn JW, Kim EH, Cho DI, Lee JH, Kim KT, et al. Result and administration of spinal tuberculosis as indicated by the disjoin ity of sickness: a review investigation of 137 grown-up patients at Korean instructing doctor's facilities. *Spine* 2007, 32:EI 30-135
33. Moore SL, Rafii M. Imaging of musculoskeletal and spinal contaminations in AIDS. *Radiol Clin North Am* 2001.