



## Diagnostic Utility of Bone Marrow Aspiration and Bone Marrow Biopsy in Hematological Practice

Authors

Dr Neema Ankur Rana<sup>1</sup>, Dr Neelam Shah<sup>2</sup>, Dr Meena Daveshvar<sup>3</sup>,  
Dr Hiral Shah<sup>4</sup>, Dr Hemali Tailor<sup>5</sup>, Dr Smita C. Patel<sup>6</sup>

<sup>1</sup>Assistant Professor, <sup>2,4</sup>Tutor, <sup>3,5</sup>Associate Professor, <sup>6</sup>Professor and Head of Department  
Department of Pathology, Medical College Baroda, India

\*Corresponding Author

Dr Neema Ankur Rana

A-5, Narayankrupa Society, Behind Pratham Complex, Iskon Temple Road, Vadodara-390015

### Abstract

**Introduction:** Bone marrow aspiration (BMA) and bone marrow biopsy (BMB) are important diagnostic procedures. We have found that when both the procedures are performed simultaneously they are complementary to each other. The study was conducted to determine and compare the diagnostic efficiency of bone marrow aspiration and trephine biopsy done simultaneously.

**Material and Methods:** A total no of 100 cases, where both BMA and BMB were done simultaneously on admitted patients, have been reviewed. The results have been compared with that of previously published literature.

**Results:** We have found that 76.0% cases showed positive correlation between bone marrow aspiration and biopsy findings. Out of 100 cases, bone marrow aspiration was diagnostic in 86.0% of cases while bone marrow biopsy was diagnostic in 87.0% of cases. Nutritional anemia, hematological malignancies and immune thrombocytopenic purpura can be easily diagnosed by bone marrow aspiration alone while bone marrow trephine biopsy is standard for diagnosis of granulomatous inflammation and hypoplastic /Aplastic anemia.

**Conclusion:** Our study suggests that bone marrow aspiration is easy to perform and important for morphological assessment. Bone marrow trephine biopsy is more reliable in assessing cellularity, bone marrow architectural pattern, distribution of cell and fibrosis. Overall both the procedures are complementary to each other and must be performed together for better evaluation of bone marrow.

**Keywords:** BMA-Bone marrow aspiration, BMB-Bone marrow biopsy.

### Introduction

Bone marrow examination is useful in the diagnosis of hematological and non hematological disorders<sup>1,2</sup>. Examination of bone marrow is one of the important diagnostic investigation. Bone marrow is widely distributed throughout the human body. The bone marrow is not only a

reservoir of stem cells but also provide a unique microenvironment in which the orderly proliferation and differentiation of precursor cells take place.

The bone marrow is examined by two separate but interrelated techniques such as bone marrow aspiration and bone marrow biopsy. When both

the procedures are performed simultaneously they are complementary to each other as BMA gives better morphology of the cells and BMB gives a good picture regarding the pattern of distribution of cells<sup>3,4,5</sup>. Without exception, the peripheral blood should be examined prior to aspiration and biopsy. It is relatively uncommon to find hematological disease in the bone marrow without evidence of it in peripheral blood. The study was conducted to determine and compare the diagnostic efficacy of bone marrow aspiration and trephine biopsy done simultaneously.

### Materials and Methods

This is a retrospective study. A total no. of 100 cases between March 2015 to January 2017 were included in this study where both BMA and BMB were done simultaneously on patients admitted as indoor patients.

In each case a detailed clinical history, general and local examination, routine hematological investigation like complete blood count (CBC), peripheral smear examination, basic coagulation study, reticulocyte count and other relevant clinical investigations have been performed.

Patients were informed about the procedure and written consent was taken from patient or patient's relative. The bone marrow samples were obtained from the posterior or anterior superior iliac spine with the help of Jamshedi needle. Approximately 0.3 ml of bone marrow was aspirated. Both BMA and BMB obtained at the same time and same site. The bone marrow aspirate smears were made immediately after aspiration. The bone marrow aspiration smears were stained for Leishman, Giemsa and Pearl iron stain for every case. Other special stains were applied as and when required. The length of biopsy was 1.5 to 2 cm. The biopsy was fixed for 24 hrs in 10% buffered formalin, decalcified in 6% EDTA solution for 72 hours and finally processed for paraffin section. BMB slides were stained with haematoxylin and eosin (H and E).

All bone marrow aspirate smears and trephine biopsy were examined for morphological details and compared for final diagnosis.

### Results

Commonest indication for a bone marrow examination in our study was pancytopenia and anemia followed by bicytopenia, thrombocytopenia and splenomegaly.

Out of the 100 cases, aspirate was diagnostic in 86 cases (86%) while biopsy was diagnostic in 87 cases (87.0%). The majority 76 (76.0%) of the cases showed positive correlation between the bone marrow aspirate and biopsy findings. Hypocellular and Megaloblastic anemia were the most common diagnosis followed by leukemia (CML, AML).

The highest correlation was noted in hematological malignancies such as CML (8/8) and AML (3/3) where there was 100% correlation in both BMA and BMB.

Other cases with a good positive correlation, MDS, Plasma cell Dyscrasia, CMPDs and maturation arrest, despite small no. of cases.

Immune thrombocytopenic purpura was diagnosed in 6 cases on aspirate and 9 cases on biopsy.

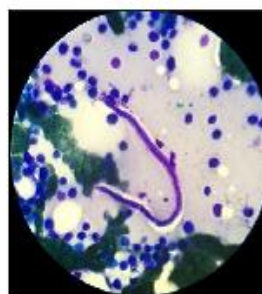

Figure 1 - BMA shows Filaria  
(Leishman stain 1000 x)

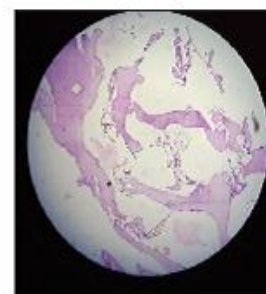
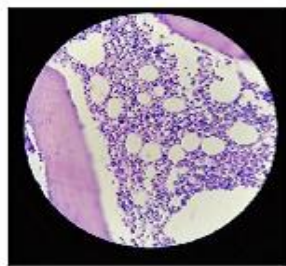
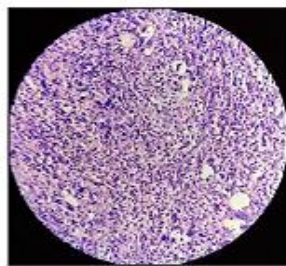


Figure 2 - BMB shows hypocellular  
marrow-Aplastic Anemia  
(H & E Stain 100x)



**Figure 3 - BMA shows Increased number of Megakaryocytes in ITP (H&E Stain 100x)**



**Figure 4 - BMB shows Chronic Myeloid Leukemia(H&E 400x)**

**Table 1** Cases diagnosed on bone marrow aspiration and bone marrow biopsy

Sr NO.	Diagnosis	BMA	BMB	Percentage of correlation
1	Iron deficiency anaemia	2	3	66.6
2	Nutritional Anaemia	3	3	100
3	Megaloblastic Anaemia	14	16	87.5
4	Hypoplastic/Aplastic	19	17	89.5
5	Chronic Myeloid Leukemia	8	8	100
6	Immune Thrombocytopenic Purpura	6	9	66.6
7	Normocellular	14	10	71.4
8	Acute Myeloid Leukemia	3	3	100
9	Myelodysplastic Syndrome	3	4	75
10	Plasma cell Dyscrasis	3	2	66.6
11	Chronic Myeloproliferative Disorder	3	2	66.6
12	Erythroid Hyperplasia	2	3	66.6
13	Maturation arrest	1	1	100
14	Hypercellular	4	4	100
15	Diluted/Dry tap	14	-	
16	Suboptimal Biopsy	-	13	
17	Microfilaria	01	00	
18	Granulomatous Inflammation	00	02	
	Total	100	100	

**Discussion**

The objective of our study was to examine the utility of simultaneous BMA and BMB in routine hematological practice. These procedures are also valuable for follow up of patients undergoing chemotherapy, bone marrow transplantation and other forms of medical treatment<sup>1,4</sup>.

All the cases included in the study underwent simultaneous BMA and BMB evaluation. They were primarily fresh (undiagnosed) cases.

The majority i.e 76 % of the cases showed positive correlation between bone marrow aspiration and biopsy. This is similar to study published by Chandra et al<sup>2</sup> where the correlation was 78% as well as study done by Majid el al<sup>6</sup> where the correlation was 76.2% and other study by Khan et al<sup>7</sup> where the correlation was 73.8%.The failure rate of BMA (14%) and BMB (13%) in our study and was mainly due to diluted marrow or dry tap.

In our study, we diagnosed 16 cases of megaloblastic anemia on BMB. There was a high sensitivity of BMA 87.5% in diagnosis of megaloblastic anemia<sup>5</sup>. Only two cases were not diagnosed on bone marrow aspiration due to dilution with blood.

We observed 89.5% positive correlation in cases of aplastic anemia<sup>2</sup>. Two cases of hypocellular bone marrow aspirate were not diagnosed on BMB due to suboptimal biopsy. One case of aplastic anemia diagnosed only on BMB which was dry tap on aspiration. BMB gives qualitative and quantitative assessment of cellularity and therefore confirms the diagnosis and overcomes the limitation of BMA<sup>1</sup>.

Immune thrombocytopenic purpura was diagnosed in 6 cases on aspirate and 9 cases on biopsy. There is 66.6% positive correlation in immune thrombocytopenic purpura. Three cases were not diagnosed on bone marrow aspiration due to dilution with blood<sup>8</sup>.

There was 100% positive correlation in cases of chronic myeloid leukemia. All cases of chronic myeloid leukemia presented with splenomegaly .Out of eight cases of Chronic Myeloid leukemia two cases were in accelerated phase and rest of six were in chronic phase.

Our finding were comparable to findings of other study<sup>9,10</sup>.

There were small no. of cases of AML, MDS, Plasma cell dyscrasia, CLL and maturation arrest. There is 75% positive correlation in MDS cases.

One case of MDS in our study diagnosed as megaloblastic anemia on aspiration. In MDS trephine biopsy provided additional information such as detection of abnormal localization of immature precursors (ALIP) and aggregates of myoblast<sup>10</sup>.

There is 66.6% positive correlation in plasma cell dyscrasia. One case of plasma cell dyscrasia was not diagnosed due to suboptimal biopsy. The same findings was observed by Khan et al<sup>7</sup>. BMB is more sensitive method for quantifying plasma cell burden, especially in patient with low percentage of plasma cell on aspirate. However, cytomorphological classification of myeloma is better done on aspirate or imprint (mature, intermediary, immature and plasmablastic type)<sup>10,11</sup>.

There were three cases of chronic lymphoid leukemia. There is 66.6% positive correlation in chronic lymphoid leukemia. One case of CLL was not diagnosed due to suboptimal biopsy. These two cases had diffuse involvement of marrow, which was seen on biopsy section while aspiration only shows that marrow is involved. Pattern of marrow involvement by leukemic cells could only be analysed by trephine biopsy. Not all patients with Chronic lymphoid leukemia required bone marrow examination because bone marrow aspiration gives very little information beyond that already available from examination of peripheral blood, whereas trephine biopsy permits an accurate assessment of extent of infiltration and gives information of prognostic importance<sup>12,13</sup>. A trephine biopsy is essential for follow up of intensive treatment because it may show residual focal disease when a marrow aspirate is normal<sup>14</sup>.

One case of microfilaria was diagnosed only on BMA while bone marrow biopsy was negative for microfilaria<sup>15</sup>.

Two cases of granulomatous inflammation were diagnosed on Bone marrow biopsy, one was positive for AFB stain. Both the cases of granulomatous inflammation were normocellular on aspiration and granuloma was not seen on

aspirated smears<sup>2,3</sup>. BMB is better procedure for detecting granuloma in marrow.

### Conclusion

The study suggests that aspiration is easy to perform and important for morphological assessment. While bone marrow trephine biopsy is slightly more painful and requires more skill to perform, it is more reliable in assessing cellularity, bone marrow architectural pattern, distribution of cell and fibrosis. Nutritional anemia, hematological malignancies and immune thrombocytopenic purpura can be easily diagnosed by bone marrow aspiration alone. Bone marrow trephine biopsy is standard for diagnosis of granulomatous inflammation and hypoplastic /Aplastic anemia.

Both BMA and BMB should be done simultaneously as they play important role in providing findings which are mandatory for final diagnosis. Both the procedures are complementary to each other. While performing the BMA and BMB simultaneously with proper technique yield the maximum material and reduce the discomfort to the patient by not repeating the procedure due to inadequate material.

### References

1. Manjit Kaur, Amrit Pal Singh Rana, Shivali Kapoor, Arun Puri- Diagnostic Value of Bone marrow Aspiration and Biopsy in routine Hematology Practice, Journal of Clinical and Diagnostic Research, 2014 Aug, Vol-8(8):FC13-FC16.
2. Chandra S, Chandra H. -Comparison of bone marrow aspirates cytology, touch imprints cytology and trephine biopsy for bone marrow evaluation. Hematol Rep 2011;3 e22
3. Pampa Ch Toi, Renu G'Boy Varghese, Ramji Rai- Comparative Evaluation of simultaneous Bone marrow Aspiration and Bone marrow biopsy :An Institutional

- Experience, Indian Journal Of Hematology Blood Transfuse 2010 Jun 26(2):41-44
4. Riley RS, Hogan TF, Pavot DR, Forysthe R, Massey D ,Smith E, Wright L Jr, Ben-Ezra JM-A Pathologist's perspective on bone marrow aspiration and biopsy ,performing bone marrow examination. Clin Lab Anal 2004;18(2):70
  5. Nirnjan Mainali, Neha Homagai, Pratap Sagar Tiwari, Arun Giri-A comparative study of bone marrow aspiration and bone marrow biopsy in hematological diseases ,Journal of Nobel Medical College Vol.4, No1 Issue
  6. Majdi H.A, Sanna D.S ,Nazmi Kamal, Mohammad B.O, Ayman S.A, Ali M.S, Ahmad Telfah-Comparative Evaluation between Bone marrow Aspirate and Biopsy Morphologic Findings, Experince at King Hussein Medical Center, Journal of Royal Medical services, Vol 22 No2 June 2015.
  7. Taj Ali Khan, Irfan Ali Khan, Khalid Mahmood, J Postgrad Med Inst 2014 vol. 28 No 2,217-21, Diagnostic Role of Bone Marrow Aspiration And Trepine Biopsy In Hematological Practice
  8. Steven J.Jubelier and Robert Harpold-The Role of the bone marrow examination in the diagnosis of Immune Thrombocytopenic Purpura:case series and and literature review.
  9. Manju, Vanita Kumar, Neetu Gupta, Akhil Kapoor, Harvindra Singh Kumar-Role of Bone marrow Biopsy in Diagnosis of Hematological Disorders: A prospective Study Journal Pharm Biomed Sci/Vol.06 No.03/150-154
  10. Surbhi Goyal, Usha Rani Singh and Usha Rusia-Mediterranean Journal of Hematology and Infectious Diseases 2014;6.
  11. Sabharwal BD ,Malhotra V, Aruna S, Grewal R-Comparative evaluation of bone marrow particle smears, imprints and biopsy section. J Postgrad Med 1990;194-8.
  12. Amrish Pandya ,Tejas Patel, Neelam Shah-Comparative Utility of bone marrow and aspiration and bone marrow biopsy ,Journal of Evolution of Medical and Dental Science /volume 1 / Issue 6/December-2012.
  13. B.J Bain, Bone marrow aspiration, Journal of Clinical Pathology, Volume 54, Issue 9
  14. B.J Bain, Bone marrow trephine biopsy. Journal of Clinical Pathology,
  15. Tummididi et al-microfilaria in a bone marrow aspirate, BMC Res notes(2016) 9-256.