



## Profile of Patients Undergoing Pterygium Excision with Suture Free Glue Free Conjunctival Autograft in a Hilly North Indian District

Authors

Dr Arti Sareen<sup>1\*</sup>, Dr Kusum Bhanoo<sup>2</sup>, Dr Mudita Gupta<sup>3</sup>, Dr Mukta Sharma<sup>4</sup>

<sup>1</sup>Medical Officer, DDUZH, Shimla

<sup>2</sup>Bhanoo Hospital, Near College Gate, Dhalpur, Kullu

<sup>3</sup>Assistant Professor, Department of Dermatology, IGMC, Shimla

<sup>4</sup>Medical Officer, DDUZH, Shimla

\*Corresponding Author

Dr Arti Sareen

### Abstract

**Introduction:** Pterygium a vascularized encroachment of bulbar conjunctiva over the cornea. It is cosmetically undesirable. There are multiple surgical techniques described for its treatment but none is universally accepted.

**Aim:** To evaluate the technique of pterygium excision with conjunctival autograft sealing with autologous blood from the pterygium bed in terms of efficacy, outcome and complication rate.

**Material and Methods:** A retrospective study was undertaken in 41 patients who underwent pterygium excision with conjunctival autograft with sealing from autologous blood from the pterygium bed after local anesthesia.

**Results:** There were 41 patients with a mean age of  $45.32 \pm 9.48$  years. There were 10 males and 31 females. The chief indication for surgery was cosmetic blemish. There were 4 patients who had complications in the form of graft loss 1 patient, foreign body granuloma in 1 and recurrence was seen in 2 patients.

**Conclusion:** The recurrence rate and complication rate was found to be comparable with other techniques without the hassle of suturing or using expensive fibrin glue. Hence it is an easy, quick and cheap alternative to other techniques.

**Keywords:** pterygium, suture less, glue less autograft, complications, recurrence.

### Introduction

Pterygium (meaning a 'wing') is a triangular encroachment of the vascularized granulation tissue covered by conjunctiva in the interpalpebral area. It is a degenerative condition of the subconjunctival tissues which proliferates as avascularized granulation tissue encroaching upon the cornea destroying the superficial layers of the stroma and Bowman's membrane.<sup>1</sup>

The prevalence rate of primary pterygium has been found to be 0.7% to 31% in various populations around the world.<sup>2</sup> Risk factors include genetic predisposition, chronic environmental irritants such as dust, dryness, heat and ultraviolet rays.<sup>3</sup> Pterygium is generally managed conservatively. Cosmetic disfigurement, recurrent inflammation, visual impairment, diplopia from motility restriction and difficult to wear contact lens are the

main indications of pterygium excision.<sup>4</sup> The various surgical procedures described these days are conjunctival flap, conjunctival autograft, amniotic membrane graft or free conjunctival autograft or limbal conjunctival autograft with sutures, fibrin glue, autologous blood or mitomycin C 0.02%.<sup>5</sup>

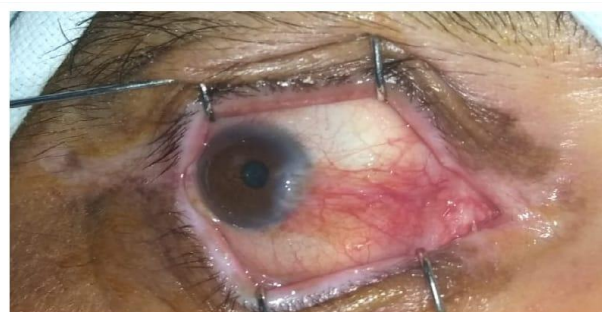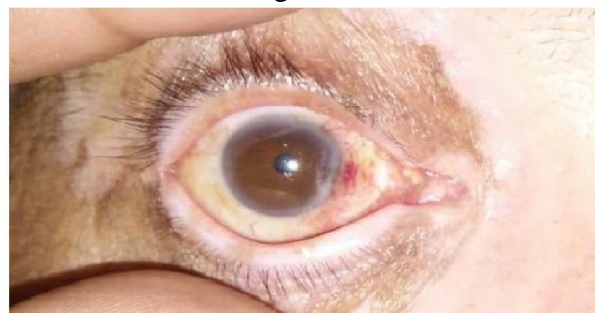Pterygium excision with conjunctival autograft using blood from the bed for adherence has been studied by Dasgupta S, Bhatia Jand Kumar Spreviously who have found it to be an easy an effective alternative.<sup>6-8</sup>

The purpose of our study was to study the outcome of patients undergoing pterygium excision followed by conjunctival autograft using autologous blood from the bed for adherence in our set up in terms of outcome and complication rate.

### Material and Methods

A retrospective study was undertaken in which 41 patients undergoing pterygium excision followed by suture free glue free conjunctival autograft were studied in detail. There were a total of 41 patients who ranged in age from 17-68 years with a mean age of  $45.32 \pm 9.48$  years. Eyes with any other ocular or systemic disease were excluded from the study. In the preoperative check up included visual acuity, refraction, best corrected visual acuity, slit lamp examination, intraocular pressure, fundus examination and photographic record of the patient. Under all asptic conditions 35 patients were given local infiltration (subconjunctival as well as subpterygial) with 2% lignocaine while 6 patients were given peribulbar anesthesia due to their unco-operative nature. After inserting the universal eye speculum, the neck of the pterygium was lifted with a toothed forceps and the head of the pterygium was excised both superiorly and inferiorly using Vannas scissors. The body of the pterygium was excised gently and excess bleeding was controlled with cotton tipped applicator. The bare sclera was then measured with Castroveijo calipers. The inferotemporal graft was then taken which was about 0.5mm oversize and care being taken not to include the underlying Tenon's capsule

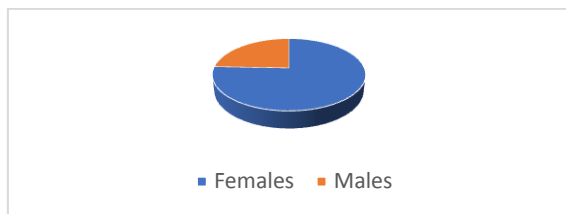
with a fine tipped Vannas scissors. The graft was placed limbus to limbus carefully and waited for about 10 minutes for hemostasis to occur. The eye was then patched for about 6 hours after instilling 0.5% moxifloxacin. Any intraoperative complication was noted. On the first post operative day we assessed the graft adherence, any symptoms or complications. Topical antibiotic-steroid combination (0.5% moxifloxacin+prednisolone) four times a day which was tapered after 2 weeks and topical carboxymethylcellulose 0.5% eye drops were prescribed 4 times a day. Follow up was done 2 weeks and 2 months after surgery to note and complication, graft adherence and recurrence. Pre-operative and post operative eye after pterygium excision is shown in Figure 1 and 2.



**Figure 1 and 2:** Showing pre operative eye and post operative 2 weeks after pterygium excision

### Results

A total of 41 patients who underwent pterygium excision followed by autologous conjunctival autograft without any sutures or glue were included in our study. The age of the patients ranged from 17-68 years (as shown in Figure 1) with mean age of the patients was  $45.32 \pm 9.48$  years. There were 10 males and 31 females. 37 patients had primary pterygium and 4 patients had recurrent pterygium. (Figure 3)



**Figure 3:** Showing sex distribution in patients of pterygium.

The main indication for surgery was cosmetic blemish seen in 25 patients (60.9%) followed by recurrent irritation and inflammation in 7 patients (17.1%).

The patients were followed up next day, 2 weeks and 2 months after surgery. On the first post operative day the patients main complaints were pain (2 patients) and foreign body sensation(1 patient) which had settled down at the 2 week follow up.

The main complications seen were lost graft in 1 patient (2.4%), foreign body granuloma in 1 patient (2.4%) and recurrence in 2 patients (4.9%).

Patients reported a marked cosmetic satisfaction. A total of 38 patients(92.7%) were cosmetically satisfied with the results.

### Discussion

Pterygium is a fairly common condition occurring especially in hot dry and dusty areas. The primary management is conservative till it encroaches on the pupillary axis or the patient demands an early surgery because of the cosmetic blemish.

Various surgical options include pterygium excision which may be left bare, use of mitomycin C 0.02% to prevent recurrence (though associated with complications like scleral necrosis, cataract and iritis) or covered with a conjunctival flap, conjunctival autograft (with a piece of limbal conjunctival tissue) or amniotic membrane with sutures, fibrin glue or autologous blood. Surgical excision with lamellar keratectomy or keratoplasty has also been tried.<sup>9</sup>

Use of conjunctival graft to cover the bare sclera after excision of the pterygium has been shown to be the most effective method of lowering recurrence rate and complications.<sup>10,11</sup> A recent

study by Kaufmann et al has shown the superiority of conjunctival autograft and limbal conjunctival autograft over amniotic membrane grafts well as associated risk of vision threatening complications with mitomycin C.<sup>12</sup>

Suturing is time consuming, leading to higher post operative discomfort, higher recurrence and complications than others such as prolonged healing, fibrosis and granuloma formation.<sup>13,14</sup>

Fibrin glue although avoids suture related complications but is not easily available and is also costly. Further it carries risk of transmission of prions and parvovirus B.<sup>5,14</sup>

The use of autologous blood for attaching conjunctival autograft is a relatively new technique. It has shown excellent results in addition to shortened surgical time and cost effectiveness in various studies.<sup>6-8</sup> In the present study we saw that this technique had low patient discomfort, excellent results and a low complication rate.

### Conclusion

From the present study we can conclude that pterygium excision with autologous blood sealing from the pterygium bed is an easy, quick and cheap alternative to other techniques. The recurrence rate and complication rate was found to be comparable with the technique using expensive fibrin glue and much better than using sutures.

### References

1. Sihota R, Tandon R, editors. Diseases of conjunctiva. Parson's Diseases of the Eye. 22nd edition India: Butterworth-Heinemann; 2015.p.184-5.
2. Detels R, Dhir SP. Pterygium: A geographical study. Arch Ophthalmol 1967;78: 485-91.
3. Nemesure B, Wu SY, Hennis A, Leske MC; Barbados Eye Studies Group. Nine year incidence and risk factors for pterygium in the Barbados ey studies. Ophthalmology 2008;115:2153-8.
4. Kheirkhah A, Adelpour M, Nkdel M, Ghaffari R, Ghassemi H, Hashemi H.

- Evaluation of conjunctival graft thickness after pterygium surgery by anterior segment optical coherence tomography. *Curr Eye Res* 2011; 36:782-6.
5. de Wit D, Athanasiadis I, Sharma A, Moore J. Sutureless and glue free conjunctival autograft in pterygium surgery: A case series. *Eye* 2010;24:1474-7.
  6. Dasgupta S. Pterygium excision with suture free, glue free conjunctival autograft(SFGF-CAG): Experience of a tertiary care hospital in Northern India. *Journal of Clinical Ophthalmology and Research* 2016;4:143-8.
  7. Bhatia J, Varghese M, Narayanadas B, Bhatia A. Cut and place technique of pterygium excision with autograft without using sutures or glue: Our experience. *Oman J Ophthalmol* 2017; 10:81-6.
  8. Kumar S, Singh R. Pterygium excision and conjunctival autograft: A comparative study of techniques. *Oman J Ophthalmol* 2018;11:124-8.
  9. Khurana AK, Khurana AK, Khurana BP. Diseases of Conjunctiva. *Comprehensive Ophthalmology*. 7th edition;2019.p.89-91.
  10. Tan DT, Chee SP, Lim AS. Effect of pterygium morphology on pterygium recurrence in a controlled trial comparing conjunctival autografting with bare sclera excision. *Arch Ophthalmol* 1997;115: 1235-40.
  11. Lewallen S. A randomized trial of conjunctival autografting for pterygium in the tropics. *Ophthalmology* 1989;96: 1612-4.
  12. Kaufman SC, Jacobs JL, Lee WB, Deng SX, Rosenblatt MI, Shtein RM. Options and adjuvants in surgery for pterygium: A report by the American Academy of Ophthalmology. *Ophthalmology* 2013;120: 201-8.
  13. Hall RC, Logan AJ, Wells AP. Comparison of fibrin glue with sutures for pterygium excision surgery with conjunctival autografts. *Clin Experiment Ophthalmol* 2009;37:584-9.
  14. Koranyi G, Seregard S, Kopp ED. Cut and paste: A no suture, small incision approach to pterygium surgery. *Br J Ophthalmol* 2004;88:911-4.