



Study of Etiological Factors in Unilateral Chronic Maxillary Sinusitis

Authors

Dr Sonam Oberoi¹, Dr Beni Prasad^{2*}, Dr Navneta Gangwar³

Dr Sunil Kumar Sharma⁴, Dr Jerin Thomas⁵

¹Resident, Department of Otorhinolaryngology, National Institute of Medical Sciences and Research & Hospital, Jaipur

²Professor & Head, Department of Otorhinolaryngology, National Institute of Medical Sciences and Research & Hospital, Jaipur

³Professor, Department of Otorhinolaryngology, National Institute of Medical Sciences and Research & Hospital, Jaipur

⁴Assistant Professor, Department of Otorhinolaryngology, National Institute of Medical Sciences and Research & Hospital, Jaipur

⁵Senior Resident, Department of Otorhinolaryngology, National Institute of Medical Sciences and Research & Hospital, Jaipur

*Corresponding Author

Dr Beni Prasad

Professor & Head, Department of Otorhinolaryngology, National Institute of Medical Sciences and Research & Hospital, Jaipur, India

Abstract

Background: *Unilateral maxillary sinusitis is a multifactorial disease. Any anatomical, physiological or pathological features which in a way obstruct free drainage from sinuses permits stasis of secretion and predisposes to infection. In this study every attempt is made to find out possible etiology contributing to unilateral maxillary sinusitis so that correction of etiology will help in correcting the disease and also results in successful outcome of treatment.*

Material & Methods: *This is a cross sectional study was done in 100 patients presenting with symptoms and signs suggestive of unilateral maxillary chronic sinusitis duration of more than 12 weeks. Intra oral peri apical radiographs were taken of maxillary teeth. Imaging of nose and PNS was done with sinus computed tomography, maxillary teeth on CT were examined for periapical lucencies.*

Results: *The present study showed that maximum number of patients were above 25 years of age. The mean age of patients was 48.82±20.47 years in our study (table 1). Male to female ratio was 3.16:1 & rural was more common (80%) as compared to urban (20%). The most common symptoms were headache/ facial pain (80%). The majority of cases had treated with Septoplasty with MMA in 35% cases followed by conservative treatment was done in 24% cases, FESS was done in 19% cases, Turbinoplasty with MMA in 12% cases and endoscopic remodeling of paradoxical turbinate was done in 10% of cases.*

Conclusion: *We concluded that certain anatomical variations are thought to be predisposing factors for the development of sinus disease it is necessary, for the surgeon to be aware of these variations.*

Keywords: *Unilateral maxillary sinusitis, Deviated nasal septum, Septoplasty, Turbinoplasty.*

Introduction

Chronic sinusitis is extremely prevalent disorder that has significant impact on quality of life of affected individual. It is one of the most common problems encountered in ENT practice. Chronic rhinosinusitis (CRS) refers to disease that persists beyond 12 weeks. Any anatomical, physiological or pathological features which in a way obstruct free drainage from sinuses permits stasis of secretion and predisposes to infection. There is considerable range of anatomical variations in ostiomeatal complex which has been implicated in etiology of sinus infection.¹ Maxillary sinuses are fully dependent on anterior ethmoid region because their ventilation and drainage pass through complicated fissures and narrow compartments.²

Unilateral maxillary sinusitis is a multifactorial disease, possible causes are gross deviated nasal septum (DNS), ostiomeatal complex abnormalities like prominent bulla, paradoxically turned middle turbinate, medialised uncinate, prominent agger nasi cells, antrochoanal polyp, and less well recognized odontogenic factor which if not recognized preoperatively will result in endoscopic sinus surgery failure. Foreign body in sinus like tooth root, dental prosthesis are also contributory factors. Messerklinger showed that in most cases infections spread from anterior ethmoidal area and middle meatal region to secondarily affect maxillary and frontal sinuses.³

The presence of unilateral symptoms or pathology is regarded with caution as sinonasal neoplasms may also present during their early stages with subtle symptoms that mimic an inflammatory pathology.⁴ It is always the otolaryngologists endeavor to identify a neoplastic pathology early to prevent complications.⁵⁻⁷ Polyps are a common cause of nasal obstruction in adults with a prevalence of about 4% in the general population. In this study every attempt is made to find out possible etiology contributing to unilateral maxillary sinusitis so that correction of etiology will help in correcting the disease and also results in successful outcome of treatment.

Material & Methods:

This is a cross sectional study was done in Department of Otorhinolaryngology, at National Institute of Medical Sciences and Research & Hospital, Jaipur, from January 2017 to June 2018. All patients presenting with symptoms and signs suggestive of unilateral maxillary chronic sinusitis duration of more than 12 weeks.

Inclusion Criteria

- Patients presenting with symptoms of unilateral chronic maxillary sinusitis.

Exclusion Criteria

- Acute Sinusitis.
- Patient suffering from chronic granulomatous diseases of nose.
- Allergic Rhinosinusitis.
- Bilateral chronic maxillary sinusitis.

Method

Patients were selected by the convenience sampling method. After informed consent, a detailed history were taken, ENT examination including complete orodental examination was done.

Investigations

All 100 patients were subjected to complete hemogram, absolute eosinophil count, RBS, urine routine. Antral wash was taken and was sent to department of microbiology

Imaging

Intra oral peri apical radiographs were taken of maxillary teeth. Imaging of nose and PNS was done with sinus computed tomography, maxillary teeth on CT were examined for periapical lucencies.

Results

The present study showed that maximum number of patients were above 25 years of age. The mean age of patients was 48.82 ± 20.47 years in our study (table 1). Male to female ratio was 3.16:1 & rural was more common (80%) as compared to urban (20%) (table 2).

The most common symptoms were headache/ facial pain (80%), followed by nasal obstruction

(53%), nasal discharge (38%), sneezing (36%) and epistaxis (5%) in our study (graph 1).

Our study showed that the external nose deformity was found in 12% of cases and sinus tenderness positive in 25% of cases. In anterior rhinoscopy, right deviated nasal septum was found most commonly (39%) followed by B/L inferior turbinate hypertrophy occurred in 22% of patients, left deviated nasal septum in 20% of cases and mass positive in 19% of patients. In posterior rhinoscopy, positive mass present in 19% of cases (table 3).

In nasal endoscopy, right deviated nasal septum was found most commonly 39% followed by left deviated nasal septum in 20% of cases, pale colored mass arising from middle meatus 19%, B/L inferior turbinate hypertrophy with middle turbinate hypertrophy 12% and B/L inferior turbinate hypertrophy with paradoxical middle turbinate hypertrophy in 10% patients (graph 2).

In our study showed that the mostly patients occurred with right deviated nasal septum (39%) followed by left DNS (20%), antrochoanal polyp (19%), concha bullosa (12%) and paradoxical

turned middle turbinate present in 10% cases (table 4). The majority of cases had treated with Septoplasty with MMA in 35% cases followed by conservative treatment was done in 24% cases, FESS was done in 19% cases, Turbinoplasty with MMA in 12% cases and endoscopic remodeling of paradoxical turbinate was done in 10% of cases (table 5).

Table 1: Age wise distribution of cases

Age (yrs)	No. of patients	Percentage
15-25 yrs	13	13%
26-35 yrs	17	17%
36-45 yrs	17	17%
46-55 yrs	14	14%
56-65 yrs	16	16%
66-75 yrs	13	13%
>75 yrs	10	10%
Total	100	100%
Mean±SD	48.82±20.47	

Table 2: Demographic profile of patients

Demographic profile	No. of patients	Percentage
Sex		
Male	76	76%
Female	24	24%
Region		
Rural	80	80%
Urban	20	20%

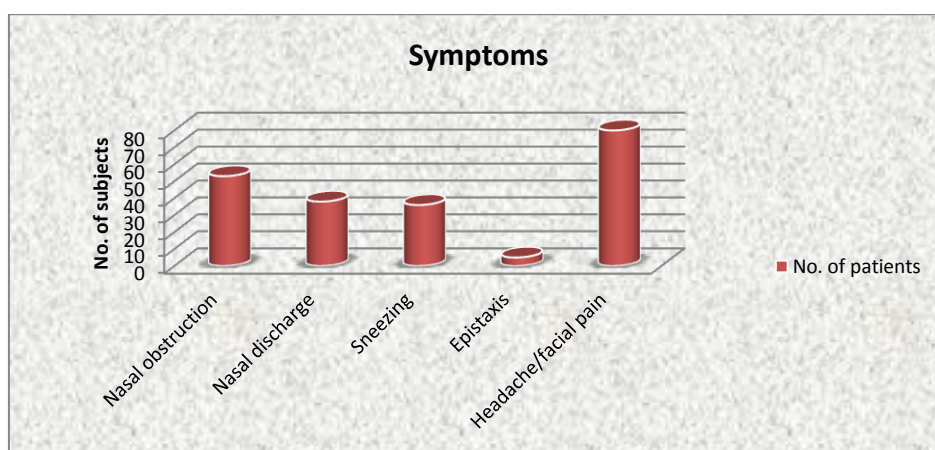
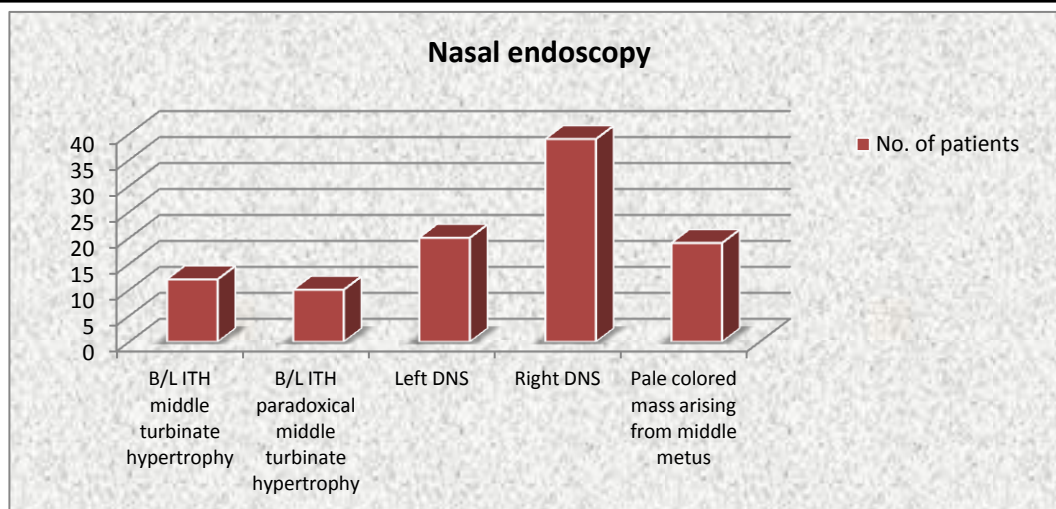


Table 3: Examination of cases

		No. of patients	Percentage
External nose	Deformity	12	12%
	Normal	88	88%
Sinus tenderness	Positive	25	25%
	Negative	73	73%
Anterior rhinoscopy	B/L ITH	22	22%
	Left DNS	20	20%
	Right DNS	39	39%
	Mass Positive	19	19%
Posterior rhinoscopy	Mass Positive	19	19%



Graph 2: Nasal endoscopy

Table 4: Diagnosis of patients

Diagnosis	No. of patients	Percentage
Right DNS	39	39%
Left DNS	20	20%
Antrochoanal polyp	19	19%
Concha bullosa	12	12%
Paradoxical turned middle turbinate	10	10%
Total	100	100%

Table 5: Treatment of patients

Treatment	No. of patients	Percentage
Conservative treatment	24	24%
Septoplasty+MMA	35	35%
FESS	19	19%
Turbinoplasty+MMA	12	12%
Endoscopic remodeling of paradoxical turbinate	10	10%
Total	100	100%

Discussion

Unilateral maxillary sinusitis is a multifactorial disease, possible causes are gross deviated nasal septum (DNS), ostiomeatal complex abnormalities like prominent bulla, paradoxically turned middle turbinate, medialised uncinata, prominent agger nasi cells, antrochoanal polyp, and less well recognized odontogenic factor which if not recognized preoperatively will result in endoscopic sinus surgery failure. In this study every attempt is made to find out possible etiology contributing to unilateral maxillary sinusitis so that correction of etiology will help in correcting the disease and also results in successful outcome of treatment.

Our study showed that the mean age of patients was 48.82±20.47 years. D. Chandrika et al (2017)⁸ found youngest patient was 7 years and oldest patient was 67 years.

Paulius Ugincius et al (2006)⁹ found mean age of the female was 46.6±15.0, the mean age of the men was 42.1±14.4. Statistically significant difference in the age difference of the women and the men was found (p=0.0024).

In present study, male to female ratio was 3.16:1. Rural was more common (80%) as compared to urban (20%). D. Chandrika et al (2017)⁸ found male to female ratio was 1.08:1. Another study conducted by Lee and Lee,¹⁰ in which the male to female ratio was 15:12 with a higher incidence in men.

The most common symptoms was present with headache/facial pain (95%), followed by nasal obstruction (53%), nasal discharge (38%), sneezing (36%) and epistaxis (5%) in our study. Which was consisted with Prakash and Biyyapu et al (2016)¹¹, Longhini and Ferguson¹² & Andric *et al.*¹³

R. H. Kamel (1989)¹⁴ found that all cases of chronic maxillary sinusitis were associated with anatomical variations and/or pathological abnormalities of ‘the ostiomeatal area’. Dua K, et al (2005)¹⁵ found deviated nasal septum was present in 44% of patients, which was consisted with our results.

In nasal endoscopy, right deviated nasal septum was found most commonly (39%) followed by left deviated nasal septum in 20% of cases, pale colored mass arising from middle meatus (19%), B/L inferior turbinate hypertrophy with middle turbinate hypertrophy (12%) and B/L inferior turbinate hypertrophy with paradoxical middle turbinate hypertrophy in 10 patients. Our study consisted with Pandey A et al (2014)¹⁶ & Chandrika D, Anantharaju GS (2017)⁸.

In our study showed that the, in x-ray PNS the opacification of maxillary sinus present most commonly in 19% of cases and haziness of maxillary sinus present in 12% of cases and in CT scan, the soft tissue attenuation in maxillary sinus present most commonly in 18% of cases followed by middle turbinate pneumatization in 12% cases, paradoxical curvature of middle turbinate in 10% cases and only 1% cases had seen mass occupying maxillary sinus. Which was consisted with Pandey A et al (2014)¹⁶ & Chandrika D, Anantharaju GS (2017)⁸.

Our study observed that the mostly patients occurred with right deviated nasal septum (39%) followed by left DNS (20%), antrochonal polyp (19%), concha bullosa (12%) and paradoxical turned middle turbinate present in 10% cases. Diagnostic nasal endoscopy with CT improves the diagnostic accuracy. Varied symptomology, varied etiology and uncommon presentation of unilateral maxillary sinusitis requires comprehensive approach by otorhinolaryngologist. Dua K, et al (2005)¹⁵ found deviated nasal septum was found in 44% of patients Wani AA et al (2009)¹⁷ found Concha bullosa was the commonest anatomic variation and was seen in 45 (30%) patients.

In present study found that the majority of cases had treated with septoplasty with MMA (35%) followed by conservative treatment was done in 24% cases, FESS was 19% cases, turbinoplasty with MMA in 12% cases and endoscopic remodeling of paradoxical turbinate was done in 10% of cases. Wani AA et al (2009)¹⁷ revealed that thorough preoperative CT evaluation of the

patients undergoing FESS is necessary to detect various anatomical variations in the ostiomeatal complex & Functional endoscopic sinus surgery (FESS) has revolutionized the approach and treatment of chronic rhinosinusitis.

Concluded

We concluded that certain anatomical variations are thought to be predisposing factors for the development of sinus disease it is necessary, for the surgeon to be aware of these variations. Nasal endoscopy and CT scan PNS assists the surgeon as a “road-map guide” during medical and surgical management of unilateral chronic maxillary sinusitis.

References

1. Xinreich SJ, Kennedy DW, Gayler BW. CT of nasal cavity, paranasal sinuses: an evaluation of anatomy in endoscopic sinus surgery. *Clear images*. 1988;2:2-10.
2. Kamel RH. Nasal endoscopy in chronic maxillary sinusitis. *The J Laryngol Otol*. 1989;103:275-8.
3. Messerklinger W. Drainage of normal frontal sinus of man. *Acta Otolaryngol*. 1967;63(2):176-81.
4. Karthikeya P, Mahima VG, Bhavna G. Sinonasal verrucous carcinoma with oral invasion. *Indian J Dent Res*. 2006; 1:82–86.
5. Tritt S, McMains KC, Kountakis SE. Unilateral nasal polyposis: clinical presentation and pathology. *Am J Otolaryngol Head Neck Med Surg*. 2008; 29:230–232.
6. Iqbal SM, Hussain SI. Unilateral nasal obstruction caused by sino-nasal neoplastic lesions. *JLUMHS JAN–APR*. 2006 Jan:18-23.
7. Chung HK, Tai CJ, Wang PC, Lin CD, Tsai MH. Analysis of disease patterns in patients with unilateral sinonasal diseases. *Mid Taiwan J Med*. 2008;13:82–88.

8. D. Chandrika, Anantharaju G. S. Study of etiological factors in unilateral maxillary chronic sinusitis. *Int J Otorhinolaryngol Head Neck Surg.* 2017 Jan;3(1):88-90.
9. Paulius Ugincius, Ricardas Kubilius, Albinas Gervickas, Saulius Vaitkus. Chronic odontogenic maxillary sinusitis. *Stomatologija, Baltic Dental and Maxillofacial Journal*, 2006; 8:44-8.
10. Lee KC, Lee SJ. Clinical features and treatments of odontogenic sinusitis. *Yonsei Med J* 2010;51:932-7.
11. B G Prakash, Suhasini Biyyapu. Incidence of Odontogenic Sinusitis – Experience in a Tertiary Care Centre. *International Journal of Scientific Study*, March 2016; Vol 3 (12):105-109.
12. Longhini AB, Branstetter BF, Ferguson BJ. Unrecognized maxillary sinusitis: a cause of sinus surgery failure. *Am J Rhinol allergy.* 2010;24(4):296-300.
13. Andric M, Saranovic V, Drazic R, Brkovic B, Todorovic L. Functional endoscopic sinus surgery as an adjunctive treatment for closure of oroantral fistulae: A retrospective analysis. *Oral Surg Oral Med Oral Pathol Oral Radiol Endod* 2010;109:510-6.
14. R. H. Kamel study of Nasal Endoscopy in Chronic Sinusitis. *The Journal of Laryngology and otology* Volume 103, Issue 3 March 1998 pp. 275-278
15. Dua K, Chopra H, Khurana A S, Munjal M. CT scan variations in chronic sinusitis. *Indian J Radiol Imaging* 2005;15:315-2.
16. Pandey A, Nigam R, Jain A.K. A comparative study of radiological and endoscopic finding in paranasal sinuses disease. *Scholars Journal of Applied Medical Sciences (SJAMS)* 2014; 2(3C):1053-1058
17. Wani AA, Kanotra S, Lateef M, Ahmad R, Qazi SM, Ahmad S. CT scan evaluation of the osteomeatal complex. *Indian J Otolaryngol Head Neck Surg.* 2009;61: 163–68.