

**Research Article**

## A prospective study of ultra-sonographic and radiological profile of patients with liver abscess

Authors

**Dr Maneesh Jain, Dr Abhay S. Tirkey**

Corresponding Author

**Dr Abhay S. Tirkey**

GRMC &amp; JAH, Gwalior, MP, India

Email: [drabhaytirkey@gmail.com](mailto:drabhaytirkey@gmail.com), Mobile: 9981351280**Abstract**

**Background:** Liver abscess is fairly common in developing countries like India due to inadequate sanitation, overcrowding and poor nutrition. Yet, there is limited data on ultra-sonographic and radiological profile at the medical wards.

**Aims and Objective:** To evaluate patient with liver abscess for radiological abnormality, its treatment and outcome.

**Materials and Methods:** Hundred and four liver abscess patients diagnosed on the basis of ultrasonography were studied in the Department of Medicine, GR Medical College and J A Group of Hospital, Gwalior from November 2009 to October 2011. All patients were examined clinically along with radiological assessment and assessed for optimal management and outcome. Ultrasonography was done for site, size, number, echogenicity and any other abnormality. On the basis of microbiological study, three groups were formed; Amoebic Liver Abscess (ALA) group (n=39), Pyogenic Liver Abscess (PLA) (n=28) group and Not Aspirated (NA) Group (n=37).

**Results:** ALA was more prevalent (58.2%) with male preponderance (90.1% in ALA and 60.7% in PLA group) ( $p=0.0038$ ). Most of the patients had age <40 years (92.3% in ALA group vs. 17.8% in PLA group;  $p=0.003$ ). Single abscess was seen in majority of ALA group (84.6%) whereas multiple abscesses were seen in PLA group (75%). Right lobe of liver (76.7%) was mostly involved in ALA, whereas in PLA left or both lobes were involved. ALA was mostly >10cm (56.1%) in size while PLA were between 5-10cm (71.4%) in size. Chest X-ray abnormality was more in PLA (50%) compared to ALA group (35.8%). Most common micro organism found in PLA was E coli (39%) whereas, PLA patient showed a mixed bacterial growth (32.1%). In ALA group 35.9% patient required percutaneous aspiration whereas, in PLA 46.4% patient required percutaneous aspiration. Two patients died in PLA group.

**Conclusion:** In patients with PLA multiple abscess, left lobe involvement and with pulmonary finding were mostly common whereas ALA occurs with solitary and right lobe abscess. ALA can be managed without aspiration compared to PLA.

**Keywords:** Mixed infection, liver abscess, aspiration, ultrasound-guided percutaneous needle aspiration.

**Introduction**

Liver abscess (LA) is defined as collection of purulent material in liver parenchyma which can be due to bacterial, parasitic, fungal, or mixed infection. Liver abscess is one of the common

conditions in India with second highest incidence in the world.<sup>1</sup>

In tropical country like India, both amoebic and pyogenic liver abscess (PLA) continues to be an important cause of morbidity and mortality.<sup>1</sup> Out

of total incidence of LA, approximately two-thirds of cases in developing countries are of amoebic (ALA) etiology and three-fourths of cases in developed countries are pyogenic.<sup>1</sup>

For the past two decades, advances in the imaging field coupled with ultrasound-guided percutaneous needle aspiration and drainage brought dramatic changes in the pattern of treatment for liver abscess.<sup>2</sup> With the advent of non invasive diagnostic measures like ultrasonography, and CT scan, early diagnosis and effective management of liver abscess has become possible. The main aim of management of liver abscess should be to reduce the hospital stay and its complications, thereby reducing the morbidity and mortality.<sup>3</sup> Hence present study was done to evaluate patients with liver abscess for ultrasonography profile, radiological abnormality, treatment and outcome.

### Materials and Methods

Present prospective study included 104 liver abscess patients at the Department of Medicine, GR Medical College and J A Group of Hospital, Gwalior, Madhya Pradesh between November 2009 to October 2011.

All 104 patient's of liver abscess included in present study were diagnosed on the basis of ultrasonography, and were subjected to detailed demography, radiological assessment; and assessed for optimal management and outcome.

Out of 104 patients 67 gave consent for aspiration, hence microbiological diagnosis was confirmed in

these patients. On the basis of microbiological study, three groups were formed; Amoebic Liver Abscess (ALA) group (n=39), Pyogenic Liver Abscess (PLA) (n=28) group and Not Aspirated (NA) Group (n=37).

Radiological examination including CXR to note any pulmonary complication in term of position of diaphragm and any effusion in pleural cavity was done. Ultrasonography was done for site, size, number, echogenicity and any other abnormality. CT scan was done as needed. Effect of antibiotic and surgical intervention (USG guided aspiration/pigtail insertion) was also studied.

All liver abscess patient (on USG) >14 year of age were included in present study. Patients with hydatidcyst and metastatic or primary malignant neoplasm of liver were excluded from the present study.

Data was analyzed using the software IBM SPSS Ver. 20. Frequency distribution and cross tabulation was used to prepare table. Quantitative data was analyzed using student t test and categorical data was analyzed using Pearson's chi square test. Two tailed P value <0.05 was considered significant.

### Results

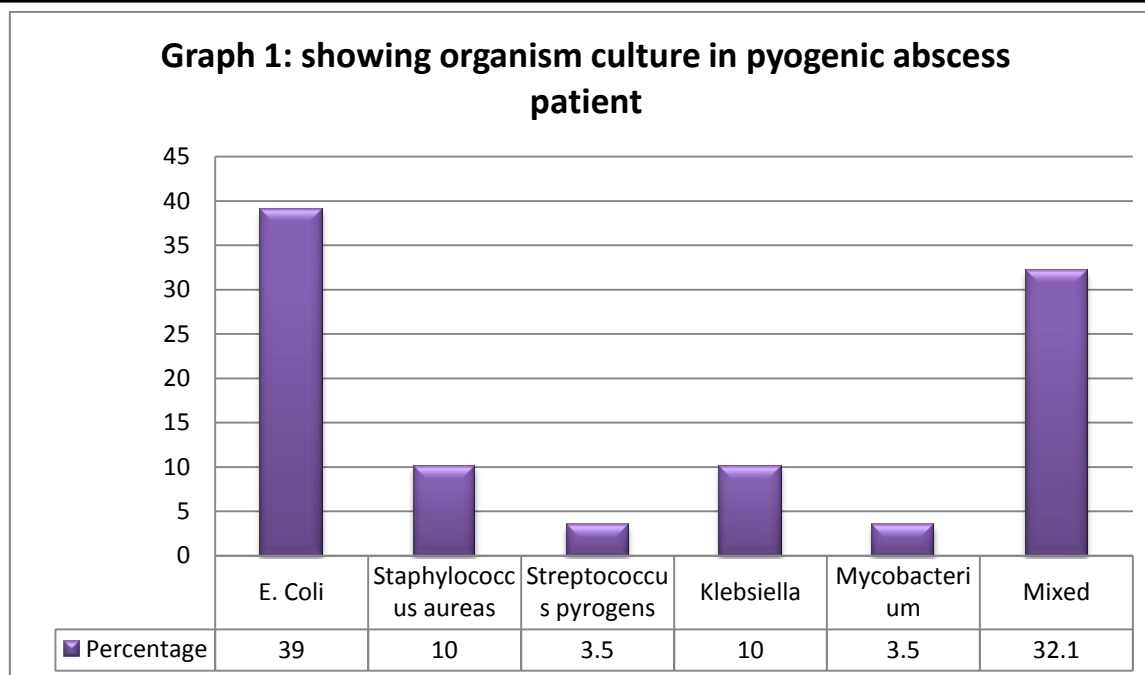
In present study, 39 (58.2%) cases were of ALA and 28 (41.8%) cases were of PLA. Males predominated over females in both group (90.1% in ALA and 60.7% in PLA group) (p= 0.0038). Most of the patients has age <40 years (92.3% in ALA group vs. 17.8% in PLA group; p= 0.003).

**Table 1:** Showing findings of ultrasonography between groups

Parameters		ALA (n=39)		PLA(n=28)		Total (n=67)	P value
		M (n=34)	F (n=5)	M (n=34)	F (n=5)		
Number of abscess	Single	29 (85.29)	4 (80)	4 (23.52)	3 (27.27)	40 (59.70)	0.018
	Multiple	5 (14.70)	1 (20)	13 (76.48)	8 (73.73)	27 (30.3)	
Lobe involved	Right	26 (76.47)	4 (80)	8 (47.05)	6 (54.54)	44 (65.67)	NA
	Left	4 (11.76)	0 (0)	5 (29.41)	3 (27.27)	12 (17.91)	
	Both	4 (11.76)	1 (20)	4 (23.5)	2 (18.18)	11 (16.41)	
Size (cm)	<5	2 (5.88)	0 (0)	1 (5.88)	0 (0)	3 (4.47)	NA
	5-10	13 (38.23)	2 (40)	12 (70.58)	8 (72.72)	35 (52.23)	
	>10	19 (55.88)	3 (60)	4 (23.52)	3 (27.27)	29 (43.28)	

Data is expressed as no of patients (percentage), M; male, F; female, NA; p value not available

In present study chest X-ray abnormality (atelectasis, effusion, and raised right hemidiaphragm) were more in pyogenic abscess group (50%) compared to amoebic liver abscess group (35.8%).



In present study 64.1% of ALA were managed conservatively (IV metronidazole 400mg 8hrly for 10 day) and rest of the patients required percutaneous aspiration; whereas, 53.57% patient of PLA were managed conservatively (IV ceftriaxone 1gm 12hrly and IV clindamycin 600mg 8hrly for 10 days) and rest of the patients required percutaneous aspiration. Patient treated with aspiration along with antibiotic stayed for a shorter duration in hospital (11 days in ALA, 10.5 Day in PLA) compared to patient treated only with antibiotic (14 days in ALA, 16.5 days in PLA). Two (11.6%) patients belonging to PLA group died in present study.

Not aspirated group had single abscess in 67% of patient and multiple abscesses in 33% of cases. Those with single abscess resembled ALA group while those with multiple abscesses resembled PLA group. All 37 patients (not aspirated group) were managed empirically. The single abscess patient were given antiprotozoal drug (IV Metronidazole 400mg 8hrly) while multiple abscess patient were given antibiotics (IV ceftriaxone 1gm 12hrly and IV clindamycin 600mg 8hrly). In present study empirical management was effective in 80.9 % cases of single liver abscess and 81.2% cases of multiple liver abscesses.

### Discussion

Liver abscess has been described and treated since Hippocrates (400BC) and Ochsner (1936) and during those days, mortality rate was very high i.e. upto 70-90%.<sup>4</sup> With the development of new radiologic techniques, improvement in microbiologic identification, advancement of drainage techniques and operative procedures, the mortality rate has come down to 5-30%. Yet the incidence has relatively remained unchanged and with the treatment, the mortality has come down to normal in those patients attending to hospitals.<sup>4</sup> Most of the patients in present study with liver abscess were in middle age with patients in second to fourth decade accounting for 55.2% of the cases which is comparable to other study done by Gorgia et al.<sup>5</sup> Siddiqui et al reported that in case of ALA most common age group was 31-40 and in group of PLA 41-50 age group was more affected.<sup>6</sup>

In our study there was high incidence of liver abscess in males (77.61%), as seen in a study by Huang et al (96%). A similar study done by Choudhary et al also reported similar age group (30-60 years) in liver abscess patients with male preponderance (72%).<sup>8</sup> Siddiqui et al studied 50 liver abscess cases and reported male preponderance (88%).<sup>6</sup>

USG is simple, inexpensive and quick to perform technique which has a diagnostic accuracy of 90%.<sup>9</sup> USG also helps in finding number, size and location of the abscess and can be used for percutaneous aspiration. USG in present study has revealed that single abscess was mostly seen in ALA Group (84.6%) whereas multiple abscesses were mostly seen in PLA group (75%). Right lobe was involved in 76.7% in ALA whereas in PLA left or both lobes were mostly involved. ALA was mostly >10cm (56.1%) in size while PLA was mostly between 5-10cm (71.4%) in size. Similar to present study Choudhary et al also reported solitary abscess in 78.0% and multiple abscesses were seen in 22.0% of cases.<sup>8</sup> Siddiqui et al reported that according to USG report 70% patients were having single abscess and the rest 30% had multiple abscesses.<sup>6</sup> This pattern of involvement has also been reported in previous series on ALA by Sharma et al, Mukhopadhyay et al and Ghosh et al.<sup>10-12</sup>

In present study, chest X-ray abnormality was more in PLA (50%) compared to ALA group (35.8%). Reports of Choudhary et al reported that chest X-ray finding were abnormal in 39% of cases and was comparable to present study findings.<sup>8</sup> Similar results were depicted in a study done by Rustam Khan.<sup>13</sup>

In a study done by Moore et al<sup>14</sup> *Streptococcus milleri* Lancefield group F was the commonest organism isolated (81.25%). Ascending infection via biliary system is considered to be leading cause of hepatic abscess. Another study by Sabbaj et al reported that 45% of pus cultures obtained from hepatic abscess were found to be anaerobic.<sup>15</sup> Wang et al<sup>16</sup> reported that 160 out of 182 (87.91%) pus cultures obtained from pyogenic liver abscesses were caused by single microorganism *Klebsiella pneumonia* and 22 (13.75%) were polymicrobial. Bacterial seedling may occur in context of deficiencies of host defenses.<sup>17</sup> Most common micro organism found in present study in PLA group was E coli (39%) whereas, PLA patient showed a mixed bacterial growth (32.1%). Rubin et al analyzed culture

aspirates in 50 patients with pyogenic liver abscess and reported similar findings.<sup>18</sup> In present study in ALA group 35.9% patient required percutaneous aspiration whereas, in PLA 46.4% patient required percutaneous aspiration.

In present study 7.14% patients died in PLA group. Dori et al studied 39 patients with pyogenic hepatic abscess and reported that mortality was 17% in surgical group and 13% in percutaneously drained group.<sup>19</sup> Seeto described 21 patients with pyogenic liver abscess treated by percutaneous drainage; this was successful in 85% of patients with mortality less than 10%.<sup>20</sup> Present study has few limitation of being small in sample size; a large randomized clinical trial is needed to strengthen the present study findings.

### Conclusion

Left lobe involvement and with pulmonary finding were mostly common observed in patients with PLA whereas ALA occurs with solitary and right lobe abscess. ALA can be managed without aspiration compared to PLA. Early detection can prevent the complication due to liver abscesses.

### References

1. Kumar N, Deka RK, Choudhury A. Clinicopathological study and management strategies of liver abscess in a tertiary care centre. J Evolution Med Dent Sci 2017; 6(19):1501-4.
2. Mangukiya DO, Darshan JR, Kanani VK, Gupta ST. A Prospective Series Case Study of Pyogenic Liver Abscess: Recent Trends in Etiology and Management. Indian J Surg 2012; 74(5): 385-90.
3. Bugti QA, Baloch MA, Wadood AU, Mulghani AH, Azeem B, Ahmed J. Pyogenic liver abscess: demographic, clinical, radiological and bacteriological characteristics and management strategies. GJMS 2005;3:1.
4. Sharmila SK, Kanha MM. Clinical Profile of Liver Abscess. IOSR Journal of Dental

- and Medical Sciences (IOSR-JDMS) 2015; 14 (2 Ver. IV): 25-38.
5. Giorgio A, Torantrno L, Maemiello N. Pyogenic liver abscess: 13 years of experience inpercutaneous needle aspiration with USG guidance. *Journal of Radiology* 1995;122-4.
  6. Siddiqui MNA, Ahad MA, Ekram ARMS, Islam QT, Hoque MA, Masum QAAI. Clinico-Pathological Profile of Liver Abscess in a Teaching Hospital. *TAJ* 2008; 21(1): 44-9.
  7. Huang CJ, Pitt HA, Lipsett PA et al. Pyogenic hepatic abscess: Changing trends over 42 years. *Ann Surg* 1996;223:600–609.
  8. Choudhary V, Choudhary A. Clinico-pathological profile of liver abscess: a prospective study of 100 cases. *IntSurg J* 2016;3:266- 70.
  9. Sepulvada, Manzo, NTG. Clinical Manifestations and diagnosis of Amoebiasis. 1986;169-88.
  10. Sharma N, Sharma A, Varma S, Lal A, Singh V. Amoebic liver abscess in the medical emergency of a North Indian hospital. *BMC research notes* 2010;3(1): 21.
  11. Mukhopadhyay M, Saha AK, Sarkar A, Mukherjee S. Amoebic liver abscess: presentation and complications. *Indian J Surg* 2010;72(1):37-41.
  12. Ghosh S, Sharma S, Gadpayle AK, Gupta HK, Mahajan RK, Sahoo R, et al. Clinical, Laboratory, and Management Profile in Patients of Liver Abscess from Northern India. *J Trop Med* 2014;2014:1423-82.
  13. Khan R, Hamid S, Abid S, Jafri W, Abbas W. Predictive factors for early aspiration in liver abscess. *World Journal Gastroenterol* 2008;14(13):2089-93.
  14. Moore-Gillen JC, Ekykyn SI, Phillips. Microbiology of pyogenic liver abscess. *BritishMedical Journal* 1981;283:819-20.
  15. Gurrent RL. The global problem of Amoebiasis: Current status reviews of *Infectious Diseases* 1986;8:218-27.
  16. Wang J, Liu YC, Lec SS. Primary liver abscess due to Kleibsiella pneumonia in Taiwan. *ClinicalInfectious Disease* 1998;26:1434-8.
  17. Branum GD, Tyson GS. Hepatic abscess: Changes in etiology, diagnosis and management. *Annals of Surgery* 1990;212:655-62.
  18. Rubin RH, Swalts MN, Malt R. Hepatic abscess. *American Journal of Medicine* 1974;57:601-10.
  19. Dori F, Zaleznik, Dennis L, Kasper. Liver abscess. In: Braunwald E, Fauci AS, Kasper DL, Hauser SL, Longo DL, Jameson JL, eds. *Harrison's Principles of Internal Medicine*. 15th ed. McGraw- Hill Inc: New York 2001; 1:832-3.
  20. Seeto RK, Rockey DC. Pyogenic liver abscess. Changes in etiology, management and outcomemedicine. *Jounal of Medicine* 1996;75:99-113.