



Original Research Article

Refinements in the surgical technique to harvest distally based posterior interosseous artery flap

Authors

Dr Maksud Devale, Dr Rohit Munot, Dr Amarnath Munoli

Dept of Plastic Surgery, LTMG Hospital, Sion, Mumbai-22, India

Corresponding Author

Dr Rohit Munot

Assistant Professor, Dept of Plastic Surgery, LTMG Hospital Sion, Mumbai-22, India

Ph No: +919860122763/ 02224043141, Email: rohithmunot@gmail.com

Abstract

Distally based posterior interosseous artery (PIA) flap is a very useful flap for defects on hand. Dissection of flap is not easy unless certain anatomical landmarks are identified and preserved throughout the dissection. We suggest here few refinements which not only improve reliability of flap but also may reduce operative time.

We start with an incision in the distal forearm on ulnar border of the flap. This ensures rapid and accurate identification of the septum. Similarly, we describe other modifications such as design of skin paddle, identification of communicating branch, transfer of flap among others.

Keywords: *Hand defects, distally based posterior interosseous artery flap, refinements.*

Introduction

The distally based posterior interosseous artery (PIA) flap is a very useful flap for defects on the hand. It provides soft, thin, and pliable tissue for reconstruction of soft tissue defects of hand without sacrificing any major arteries of the hand. The posterior interosseous artery flap is a type B fasciocutaneous flap according to the Cormack and Lamberty classification.¹ Arterial supply to the flap comes from the posterior interosseous artery, which gives off several cutaneous branches. This flap is most often used with its distal pedicle as its artery presents anastomoses with the anterior interosseous artery and the dorsal arterial carpal network. However, its dissection is often difficult because of anatomical variants and

is not reliable in case of traumatic history at the distal forearm.² Also some of its other major limitations include risk of venous congestion, scarring over distal forearm and reach of flap.

Over the years, refinements in the technique of harvesting this flap have evolved to prevent venous congestion and flap necrosis.³ This study highlights refinements in the operative technique to avoid complications, reduce operative time, improve reach of the flap and raise a successful flap.

Material and Methods

We present our study of 9 posterior interosseous flaps performed between January 2007 and December 2012. The distally-based island

posterior interosseous flap was used to cover soft tissue defects in nine patients (1 female, 8 males; mean age 30 years; range 9 to 51 years). Of these, eight patients had crush injuries and remaining one had wrist extension contracture due to burns. The defects were in the radial aspect of the wrist and base of thumb in two patients, in the dorsum of the hand in four patients, and in the dorsum of the proximal phalanges in two patients, one on ulnar aspect of dorsum of hand. The mean follow-up period was 3 months (range 2 to 7 months). Written Informed written consent was obtained from all the patients.

Vascular Anatomy

The posterior interosseous artery arises from the common interosseous artery or the ulnar artery. It passes backwards over the free upper edge of the interosseous membrane to appear on the back of the forearm between supinator and abductor pollicis longus. Here it gives off the interosseous recurrent branch. The main stem of the posterior interosseous descends between the superficial and deep layers of muscles lying on abductor pollicis longus accompanied by the deep branch of the radial nerve. As the posterior interosseous artery runs down to the wrist, it gives off muscular branches and two groups of fasciocutaneous perforators. On average, the posterior interosseous artery extends six cutaneous perforators through the intermuscular septum of the extensor carpi ulnaris and the extensor digitorum communis. Of these six arteries, two are clinically significant perforators (0.5 mm or more in diameter) and are located 6 ± 2 cm proximal to the head of the ulna and 10 ± 1 cm distal to the lateral epicondyle of the humerus.⁴

The distal anastomoses of the posterior interosseous artery are classically described as being with the anterior interosseous artery (AIA) and the dorsal carpal network. The anastomosis between the two interosseous arteries is by a connecting vessel that lies beneath the tendon of extensor indicis proprius at the level of the head of the ulna.¹

Discussion

We suggest few modifications in the surgical steps while harvesting the PIA flap. Couple of these modifications have already been described in the literature.

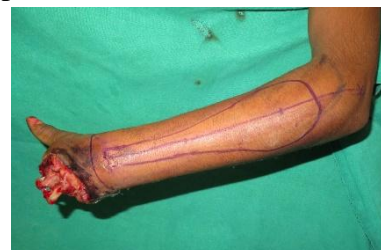1. Preoperative Doppler examination-

In our series, preoperative assessment of the communicating branch between AIA and PIA, presence of the PIA over entire forearm and the location of perforators was done by hand held Doppler study in all patients. We observed that Doppler is very useful in pre-operative planning to save time intraoperatively.

2. Design of the skin paddle-

An islanded, distally based flap with large skin paddle is more likely to be prone to venous congestion. The incidence of venous congestion in the reversed flow PIA flap followed by partial or total flap loss in the literature ranged from 3% to 37%.⁵

We follow the design of the skin paddle as described by G. Balakrishnan et. al.⁶ to avoid tunnelling of the flap and to add more superficial veins. We mark the skin paddle in tear drop fashion as shown below.

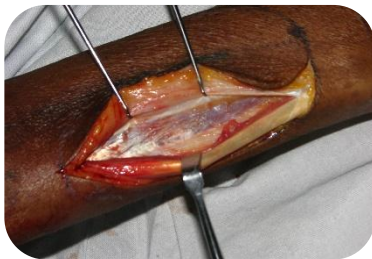


Skin preserved over the bridge segment provides additional pathway for venous drainage by incorporating subdermal venous plexus in addition to venous drainage through venoadipofascial pedicle. It helps reduce venous congestion.

3. Identification of the septum between extensor carpi ulnaris (ECU) and extensor digiti minimi (EDM)-

This is critical step in harvesting this flap. There are thin, multiple septae between muscle groups in the extensor compartment of the forearm. If dissection starts on

proximal and radial margin of the flap as described in the original paper⁷, these septae are encountered. The surgeon unfamiliar with anatomy of these septa may take time to reach the proper septum which is between ECU and EDM. These septa may be confused with the septum between ECU and EDM in the initial dissection. Also, in the proximal forearm, the septum between ECU and EDM is flimsy. One may transgress the septum though inadvertently, very easily thus damaging the perforators supplying the flap. We commence elevation of the flap by taking incision on ulnar border of flap over dorsum of head of ulna. Fascia is incised and dissection proceeds towards radial side till septum is reached.



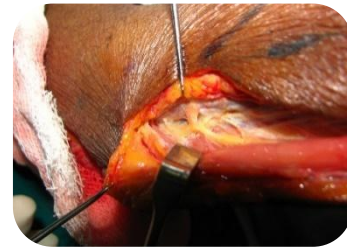
Incision on ulnar border of flap in distal forearm

Our modification allows accurate identification of the septum, thereby improving the safety and reliability of the flap. Also as the extent of dissection required to reach the septum is straightforward and minimal, significant amount of time is saved. It also allows rapid and simple dissection for location of nerve to ECU.

4. Identification of the nerve to ECU-

The posterior interosseous artery runs in close proximity to the posterior interosseous nerve. To avoid nerve and pedicle injury, direct visualization of the posterior interosseous nerve and the pedicle is crucial. Such a demanding dissection prolongs the operation time.⁸ After identifying the septum, we incise the ulnar border of the flap and follow the avascular plane towards proximal forearm by staying on ulnar side of the septum close to

ECU muscle till we reach the nerve to ECU. This approach allows us to identify and safeguard the nerve easily. Again its fairly easy and rapid dissection.



Identification of nerve to ECU

We consider identification of the nerve to ECU as a limiting step in harvesting this flap. Further proximal dissection of the pedicle is not required. Limiting the dissection at the level of nerve to ECU saves time.

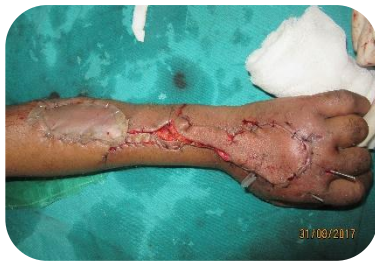After identification of nerve to ECU, 1st and 2nd perforators of posterior interosseous artery, we routinely sacrifice the 1st perforator. We have not encountered necrosis of skin cranial to ligated 1st perforator in our series. We believe there is longitudinal/axial anastomosis between perforators of the vessel. According to Sun et al the vessel chains formed by adjacent perforators are parallel to the intermuscular septum of the extensor carpi ulnaris and the extensor digitorum communis.⁴

This completes the dissection on ulnar side. Then we take incision on distal and radial borders of flap on proximal forearm till we reach the bridge segment.

5. Venoadipofascial sleeve on either side of septum-

Including a generous sleeve of fibro fatty tissue on each side of pedicle reduces flap congestion which is fairly common mentioned event in post-operative period.⁹ As the design of the skin paddle is tear drop shaped, we automatically include a sleeve of venoadipofascial tissue on each side of septum which reduces flap congestion in the postoperative period. We suggest at least 1

cm of venoadipofascial tissue should be included on each side of septum.



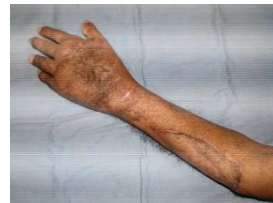Preservation of venoadipofascial sleeve and exteriorization of pedicle

6. Dissection of communicating branch till its entry into extensor compartment-
The anastomosis between the AIA and the PIA was found consistent within 1 cm from the wrist joint.¹⁰ Hence we performed dissection of the flap distally safely till the entry of the communicating branch from the anterior interosseous artery into the extensor compartment is seen. The vessel, though small is quite consistent. Confirmation of the vessel ensures the perfusion of the flap. This dissection also improves distal reach of the flap.
7. Clamping of the PIA before ligation-
Disappearance of the PIA in the middle of the forearm has been described. To detect such abnormality, we clamp the artery prior to ligation and watch for the perfusion of the flap. If there is no perfusion in the flap after clamping of the vessel, clamp is released and suitable alternative flap is chosen.
8. Exteriorization of the pedicle-
We transpose the flap to the defect by exteriorizing the pedicle as described by Puri V, et al.¹¹ This prevents compression of the pedicle. Also this leaves skin over the wrist and distal dorsal forearm unscarred facilitating secondary reconstruction if required. Additionally, exteriorization allows bowstringing of pedicle which improves

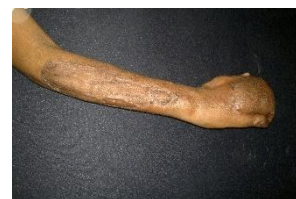reach of the flap. The pedicle is divided at 3 weeks as an OPD procedure.

Clinical photos of few representative cases wherein abovementioned modifications were employed.

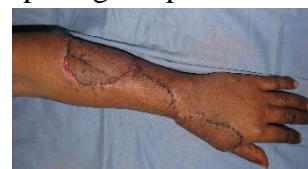Case 1- Defect on ulnar side of dorsum of hand covered with PIA flap



Case 2- Well settled donor site and PIA flap for defect over dorsum of proximal phalanges



Case 3- Defect on radial side of wrist and base of thumb. One of the initial cases where tunnel was opened up for passage of pedicle



Results

Eight out of nine flaps survived completely. In 1 patient, there was partial necrosis of the distal part of the flap, which did not require additional surgical procedure. We were able to cover the hand defects on volar and dorsal wrist, thumb, first web space and fingers up to the level of proximal interphalangeal joints (PIP joints). None of our cases showed any evidence of venous congestion. Posterior interosseous nerve palsy did not occur in any of the patients in our series. Skin grafts over the donor sites survived completely without complications. The texture, color, and thickness of the skin paddle matched the surrounding skin. The functional recovery of the hand and fingers was dependent on the original injuries to the tendons, bones and nerves.

Conclusion

Though dissection of distally based posterior interosseous artery (PIA) flap is difficult, it is a very useful flap for defects on the hand. Refinements in the original technique of harvesting the flap like rapid and accurate identification of the septum, design of the skin paddle, identification of the nerve to ECU improve the reliability of the flap.

If manuscript presented as part at a meeting:

Presented as **Poster** in IFSSH (International Federation of Societies for Surgery of Hand), New Delhi 2013

Conflict of interest- None

References

1. Lamberty BG, Cormack GC. Fasciocutaneous flaps. *Clin Plast Surg* 1990; 17:713-26.
2. Pauchot J1, Lepage D, Leclerc G, Flamans B, Obert L, Tropet Y. Posterior interosseous free flap because of absence of posterior interosseous pedicle. A report of an individualised salvage procedure and of an exceptional anatomical variation. Review of the literature. *Ann Chir Plast Esthet*. 2010 Feb; 55(1):56-60.
3. Acharya AM, Bhat AK, Bhaskaran K, The Reverse Posterior Interosseous Flap Technical considerations in raising an easier and more reliable flap. *J Hand Surg Am* 2012; 37:575–82.
4. Sun C, Wang YL, Ding ZH, Liu P, Qin XZ, Lee HL, Jin AM. Anatomical basis of a proximal fasciocutaneous extension of the distal-based posterior interosseous flap that allows exclusion of the proximal posterior interosseous artery. *J Plast Reconstr Aesthet Surg*. 2015 Jan;68(1):17-25
5. Penteado CV, Masquelet AC, Chevrel JP. The anatomic basis of the fascio-cutaneous flap of the posterior interosseous artery. *Surg Radiol Anat*. 1986; 8:209–215.
6. Balakrishnan G, Kumar BS, Hussain SA. Reverse-flow posterior interosseous artery flap revisited. *Plast Reconstr Surg* 2003; 111(7):2364–9.
7. Zancolli EA, Angrigiani C. Posterior Interosseous island forearm flap. *J Hand Surg Br* 1988; 13: 130-5.
8. Akdağ O, Yıldırım G, Sütçü M, Karameşe M. Posterior interosseous flap versus reverse adipofascial radial forearm flap for soft tissue reconstruction of dorsal hand defects. *Ulus Travma Acil Cerrahi Derg* 2018;24:43-8
9. Muhammad Naveed Shahzad, Naheed Ahmed, Khalid Hussain Qureshi. Reverse flow posterior interosseous flap: Experience with 53 flaps at Nishtar Hospital, Multan. *Journal of Pakistan Medical Association* 2012; 62(9):950-4
10. Reyad KA, Shaker AA, Elbarbary AS, Sayed MA, Elghareeb MA. The Number of Perforators Included in Reversed Flow Posterior Interosseous Artery Flap: Does It Affect the Incidence of Venous Congestion? *Plast Reconstr Surg Glob Open* 2016;22;4(12):e1162
11. Puri V, Mahendru S, Rana R. Posterior interosseous artery flap, fasciosubcutaneous pedicle technique: a study of 25 cases. *J Plast Reconstr Aesth Surg* 2007; 60: 1331-7.