



Familial Tuberous Sclerosis with Unilateral Renal Angiomyolipoma: A Case Report from Eastern India

Authors

Ankur Ghosh, ShyamSundar Chaudhary, Soumya P. Tirkey

Department of Dermatology, Venereology & Leprosy, RIMS, Ranchi, India

Abstract

Tuberous sclerosis complex (TSC) is an autosomal dominant neurocutaneous genodermatosis. Sporadic cases have been reported. We report two cases of TSC in a family with unilateral renal angiomyolipoma. A 25 year male farmer and his offspring, 6 year old girl, born of non consanguineous marriage, presented with facial angiofibroma, hypomelanotic macules and unilateral renal angiomyolipoma. Computerised tomography revealed subependymal calcification on lateral ventricles in both the patients.

Keywords: *Tuberous sclerosis complex, angiofibroma, angiomyolipoma, subependymal nodule.*

Introduction

Tuberous Sclerosis is an autosomal dominant neurocutaneous genodermatosis that affects the skin and internal organs. It has an estimated frequency of 1/6000.^[1] It was first described by Desiree-Magloire Bourneville in 1880, hence it is also known as Bourneville Disease. Neurologist Vogt in 1908 established a diagnostic triad of epilepsy, idiocy, and adenoma sebaceum (an obsolete term for facial angiofibroma). The full classic triad occurs in only 29% of the patients and 6% lack all three of the characteristics.^[2,3,4] As the manifestations of the disease are variegated in nature, the term Tuberous Sclerosis Complex (TSC) is now widely used. Here, we present two cases of TSC with multiple organ involvement (cutaneous, neurological, and renal) in a family.

Case Report

Case 1

A 25-year-old, previously healthy male, presented in the emergency department in a tertiary care

centre in Eastern India with abdominal pain, nausea and vomiting. He had a history of intermittent right flank pain for 3-4 years. He had no history of trauma. On palpation, a deep seated abdominal lump was detected. It was slightly tender, soft to firm in consistency. Her blood pressure and pulse was 140/80 mm Hg and 92/minute respectively, and body temperature was 37.5°C. Laboratory investigations were: hemoglobin 7.1 g/dL, hematocrit 19.9%, white blood cell count $8.8 \times 10^3/\text{mm}^3$ and creatinine 1.2 mg/dl. Urinalysis revealed 2-3 red blood cells, 10-12 white blood cell in the high power field. Abdominal Computerised Tomography (CT) showed a large predominantly fat-containing mass arising from the lateral aspect of the right kidney with compression of the liver, enlarged vessels within the mass, intra-tumoral and perinephric hematoma. Partial nephrectomy was performed and the specimen was sent to Department of Pathology for Histopathological Examination [Figure 1]. It was diagnosed as Angiomyolipoma

[Figure 2]. The patient also had multiple lesions on face and was referred to Dermatology Out Patients Department. On cutaneous examination, multiple yellowish discrete waxy papules of size 1-3mm were found, distributed symmetrically over the cheeks, nose and forehead [Figure 3]. The lesions started appearing in childhood and the patient had them for last 16 years. His daughter also had similar lesions on face. Clinically the lesions were diagnosed as Angiofibromas. He also had hypopigmented macules over the chest, abdomen, and extremities; and molluscum pendulum around the neck [Figure 4]. The patient was suspected a case of Tuberous Sclerosis Complex (TSC) and relevant investigations were advised. Ophthalmologic examination didn't reveal any abnormality. Chest X-ray and Echocardiography were normal. CT scan Brain revealed multiple small subependymal calcified nodules seen in the body and frontal horns of both lateral ventricles [Figure 5]. The association of renal angiomyolipoma, Subependymal nodules and skin lesions led to the clinical diagnosis of TSC.

Case 2

6 years old girl child, who was daughter of Case 1, born to non consanguineous marriage presented with skin lesions over the face and seizures since 3years. There was no history of delayed developmental milestones and mental deficiency. On cutaneous examination, multiple facial angiofibromas were noticed [Figure 6]. Complete hemogram, routine urine examination, liver and renal function tests, electrocardiogram, chest radiograph, ophthalmological examinations, were within normal limits. Ultrasound of abdomen revealed hyper-echoic SOL in right kidney suggestive of angiomyolipoma [Figure 7]. USG guided FNAC was done and it confirmed the diagnosis of angiomyolipoma [Figure 8,9]. CT scan Brain of the child showed subependymal nodules in right lateral ventricle and right parieto-occipital tubers [Figure 10].



Figure 1: Gross appearance of dissected specimen (Case 1)

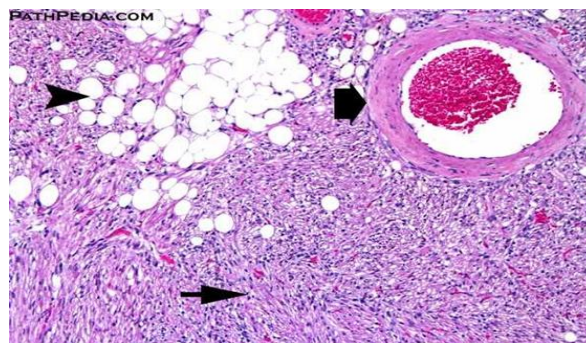


Figure 2- Histopathological examination showing Angiomyolipoma (Case 1)

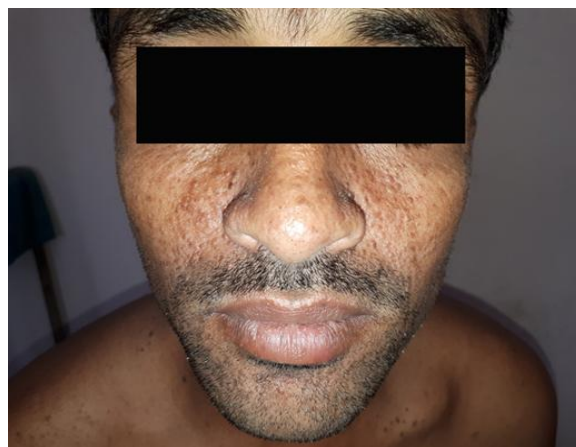

Figure 3- Facial Angiofibroma (Case 1)

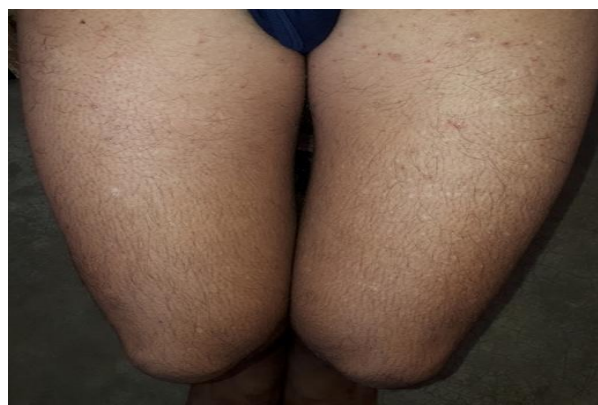

Figure 4- Multiple hypopigmented macules in lower extremity (Case 1)

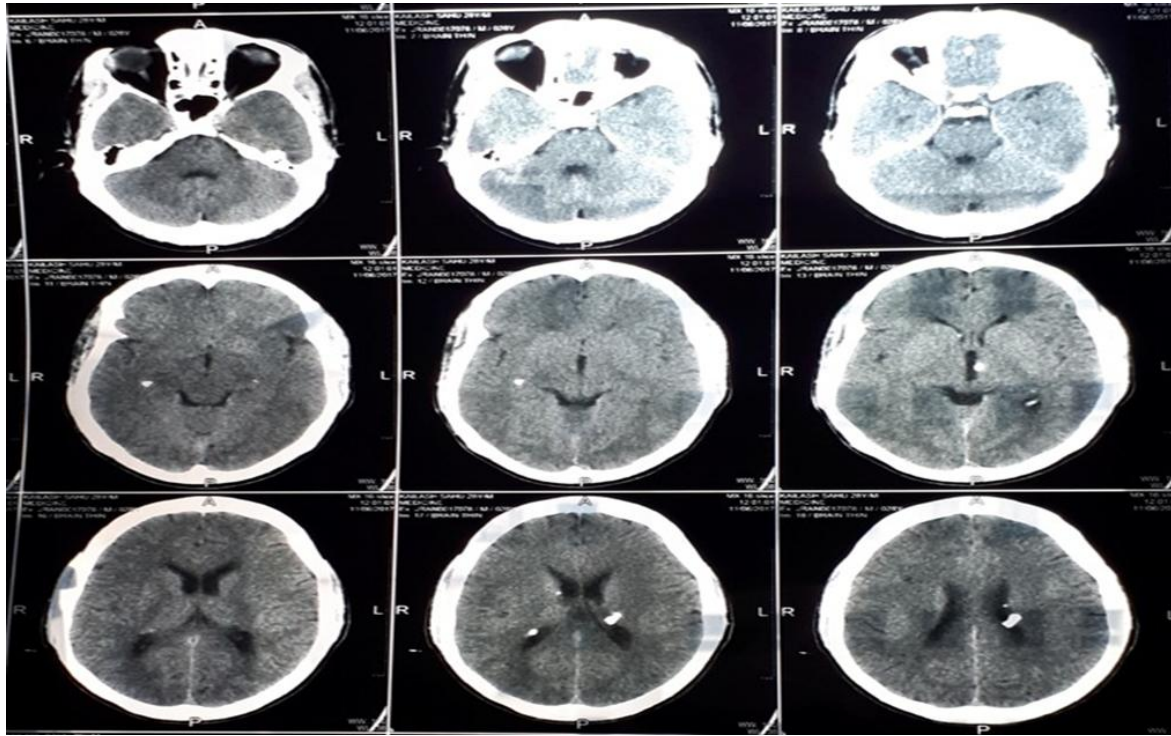


Figure 5 CT Brain showing subependymal nodules (Case 1)

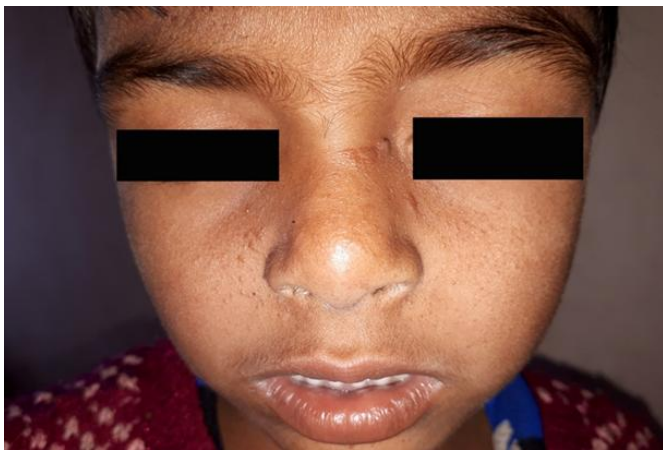

Figure 6- Facial Angiofibroma (Case 2)

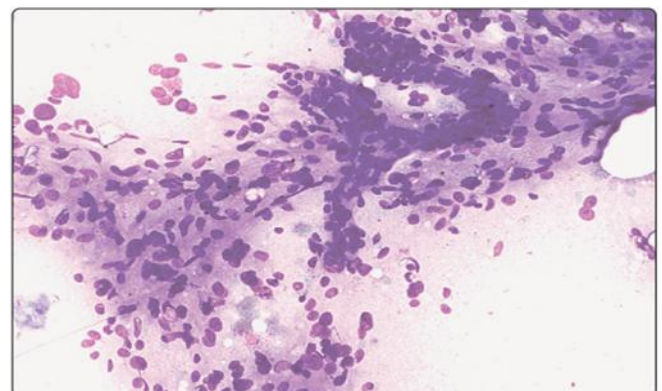


Figure 8: Tissue fragment of spindle cells with abundant cytoplasm and indistinct cell borders; a small branching blood vessel (Case 2)

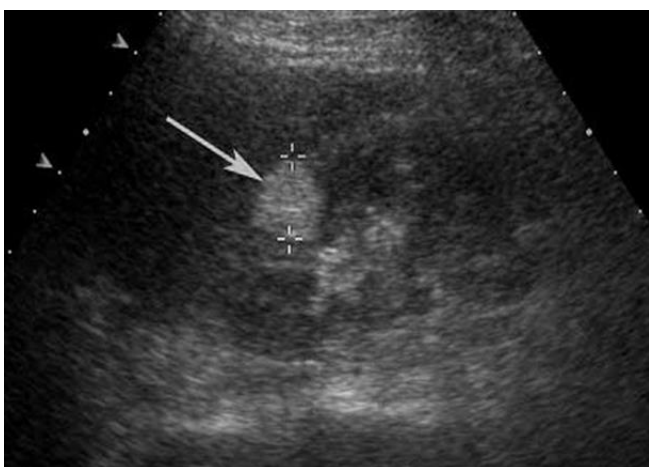

Figure 7 USG abdomen showing SOL suggestive of renal angiomyolipoma

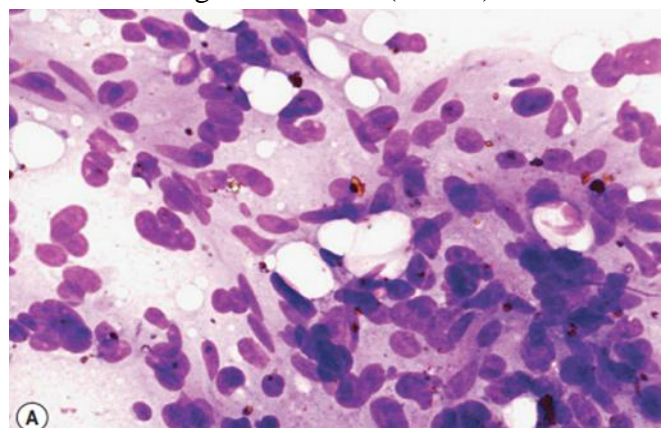


Figure 4: Loosely clustered spindle cells with abundant cytoplasm and indistinct cell borders; plump spindled or rounded nuclei; many fat droplets (Case 2)

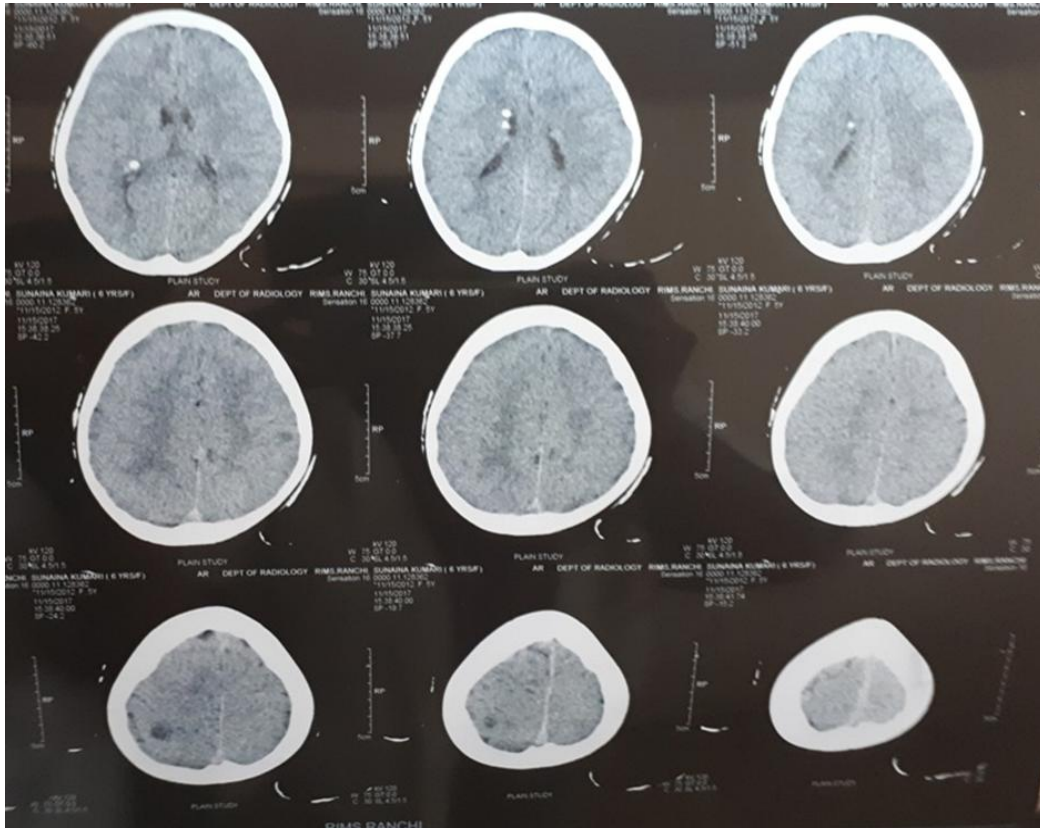


Figure 10- CT Brain showing Subependymal nodules in right lateral ventricle and right parieto-occipital tubers (Case 2)

Discussion

Tuberous sclerosis complex (TSC) is an autosomal dominant neurocutaneous syndrome with a high incidence of sporadic cases and variable clinical expression.^[5,6,7] It has an estimated frequency of 1/6000. TSC is a disorder of cellular differentiation and proliferation that can affect the brain, skin, kidneys, heart, and other organs. Abnormal neuronal migration plays a major additional role in neurological dysfunction.^[5] Two genes responsible for TSC are TSC1 at chromosome 9q34 (hamartin) and TSC2 on 16p13.3 (tuberin).^[4,8] These gene products form a tumor suppressor complex which drives Rheb (Ras homolog enriched in brain) a member of Ras super family into the inactive guanosine diphosphate-bound state. When Rheb is in the guanosine triphosphate-bound active state, it stimulates the mammalian target of rapamycin (mTOR), an evolutionarily conserved protein kinase and a major effect or of cell growth. The mutations in these genes result in constitutive

mTOR activation leading to the formation of various growths and hamartomas in various organs of the body.^[9]

TSC is a multisystem disorder with variable clinical manifestations. Diagnosis of TSC is established when two major features or one major plus two minor features can be demonstrated (TSC Consensus Conference, 1998).^[5,6,8]

Diagnostic Criteria of Tuberous Sclerosis Complex

Major Features	Minor Features
1. Facial angiofibromas or forehead plaque 2. Non-traumatic ungula or periungual fibroma 3. Hypomelanotic macules (three or more) 4. Shagreen patch (connective tissue nevus) 5. Multiple retinal nodular hamartomas 6. Cortical tuber 7. Subependymal nodule 8. Subependymal giant cell astrocytoma 9. Cardiac rhabdomyoma, single or multiple 10. Lymphangiomyomatosis 11. Renal angiomyolipomas	1. Multiple, randomly distributed pits in dental enamel 2. Hamartomatous rectal polyps 3. Bone cysts 4. Cerebral white matter radial migration lines 5. Gingival fibromas 6. Nonrenal hamartoma 7. Retinal achromic patch 8. Confetti' skin lesions 9. Multiple renal cysts

The wide spectrum of clinical features of TSC results from the formation of hamartomas in various organs like skin, brain, kidneys, and heart and less frequently in lungs, retina, gingiva, bones, and gastrointestinal tract.^[10]

Patients with Tuberous sclerosis complex (TSC) range from intellectually normal to severely mentally retarded. In addition to mental retardation, multiple behavioural problems including sleep disorder, hyperactivity, attention deficit, aggressiveness, and autism are also found in children with TSC.^[11] Seizures are the most common neurologic symptom of TSC occurring in 92% of patients.^[12] The prevalence of learning disabilities varies from 38% to 80%, and when it does exist it tends to be moderate or severe in degree. In our case, none of the patients had mental retardation or any behavioural problem. Though the child had history of seizures.

Cutaneous manifestations in TSC are common and are usually the first clue to diagnosis. The most prevalent skin manifestations are “ash-leaf patches” occurring in 90%–98% of cases. Skin hypopigmentation is also frequently noted in the “confetti lesions” seen on the anterior surface of the arms. Facial angiofibromas (adenoma sebaceum) are pathognomonic for TSC and are seen in over 70% of patients. Another common dermatological feature of TSC is the Shagreen patch which approximately occurs in 54% of patients. Ungual fibromas, also called Koenen tumors, are generally more common on toes than on fingers.^[13] Both patients had classical cutaneous findings including hypomelanotic macules and facial angiofibroma, but none of them had shagreen patch and unguinal fibroma.

Renal manifestations are the second most common findings associated with TSC. The main manifestations are angiomyolipomas (80%) and cysts (17–47%). The most common symptoms are abdominal pain, palpable abdominal mass and hematuria. Both renal cystic disease and AMLs cause chronic renal disease, affecting approximately 1 million patients with TSC worldwide.^[14] In TSC, usually bilateral

angiomyolipoma occurs. However, both of our cases had unilateral angiomyolipoma.

TSC is associated with both nonretinal and retinal findings. Nonretinal abnormalities such as eyelid angiofibromas, strabismus, cataracts, colobomas, and iris depigmentation have been reported. Hamartomas are the most common retinal manifestation present in about 40–50% of patients.^[15] None of our patients had any ocular complications.

There is no cure as such for TSC, although supportive treatment is available for a number of symptoms. Antiepileptic drugs for seizures, laser microsurgery, dermabrasion for skin condition or removal of kidney tumor, are symptomatic therapies but they can't stop disease progression. Longevity depends on the severity or multiplicity of organ involvement.^[16]

The above case study gives us an indication that the manifestations of TSC can be multiple and clinical features may appear at various times during the subject's life. There may be variability in the expression of patients even within the same family. Hence, a thorough family history becomes essential. It is therefore important that the clinician maintains a high degree of suspicion for the possibility of a hidden TSC even if few phenotypic features are observed so that the patient is managed in a holistic manner. Also, a thorough history taking and examination of family members should be done to detect any familial TSC.

The case study is rare in the context that Familial TSC is generally associated with bilateral angiomyolipoma of kidney, but in this case both the patients had unilateral angiomyolipoma.

References

1. Maria BL, Menkes JH, Sarnat HB. Child Neurology. 7th ed. Vol. 12. Lippincott Williams and Wilkins Publishers; 2000. Neurocutaneous syndromes; pp. 810–5.
2. Cassetty CT. Tuberous sclerosis complex (Bourneville disease). Dermatol Online J 2004;10:17.

3. Alshaiji JM, Spock CR, Connelly EA, Schachner LA. Facial angiofibromas in a mosaic pattern tuberous sclerosis: A case report. *Dermatol Online J* 2012;18:8.
4. Schwartz RA, Fernández G, Kotulska K, Jóźwiak S. Tuberous sclerosis complex: Advances in diagnosis, genetics, and management.
5. Islam MP, Roach ES. Neurocutaneous syndromes. In: Bradley WG, Daroff RB, Fenichel GM, Jankovic J, editors. *Neurology in Clinical Practice*. 5th ed. Vol. 69. Elsevier health sciences Publishers; 2010. pp. 1822–7.
6. Gold AP, Patterson MC. Tuberous sclerosis complex. In: Rowland LP, Pedley TA, editors. *Merritt's Neurology*. 12th ed. Vol. 109. Lippincott Williams and Wilkins Publishers; 2010. pp. 698–704.
7. Kandt RS. Tuberous sclerosis complex and neurofibromatosis type 1: The two most common neurocutaneous diseases. *NeurolClin*. 2002;20:941–64. [PubMed]
8. Sahin M. Neurocutaneous syndromes. In: Kliegman RM, Stanton BMD, Geme SJ, Schor N, Behrman RE, editors. *Nelson Textbook of Paediatrics*. 19th ed. Vol. 589.2. Elsevier Publishers; 2011. pp. 2049–51.
9. Cheng TS. Tuberous sclerosis complex: An update. *Hong Kong J Dermatol Venereol* 2012;20:61-7.
10. Kwiatkowski DJ. Tuberous sclerosis: From tubers to mTOR. *Ann Hum Genet* 2003;67(Pt 1):87-96.
11. Schwartz RA, Fernández G, Kotulska K, Jóźwiak S. Tuberous sclerosis complex: advances in diagnosis, genetics, and management. *J Am Acad Dermatol*. 2007;57:189-202.
12. Gupta S, Bhowate R, Degwekar SS. Clinical and radiological findings related to tuberous sclerosis complex: a case report. *J Contemp Dent Pract*. 2008;9:85-91.
13. Curatolo P, Bombardieri R, Jozwiak S. Tuberous sclerosis. *Lancet* 2008;372:657-68.
14. Radhakrishnan R, Verma S. Clinically relevant imaging in tuberous sclerosis. *J Clin Imaging Sci* 2011;1:39.
15. Rodrigues DA, Gomes CM, Costa IM. Tuberous sclerosis complex. *An Bras Dermatol* 2012;87:184-96.
16. O'Callaghan TJ, Edwards JA, Tobin M, Mookerjee BK. Tuberous sclerosis with striking renal involvement in a family. *Arch Intern Med* 1975;135:1082-7.