

Original Research Article

Comparison of total image quality in Tissue Harmonic Imaging as compared to conventional ultrasound technique in abdominal and pelvic ultrasonography

Authors

Dr Rajat Kumar Sharma MD (Radiodiagnosis)¹,

Dr Vikas Rastogi MD (Radiodiagnosis)²

¹Associate Professor, Department of Radiodiagnosis, Base Hospital Delhi Cantt

Email: rajatsharma247@yahoo.co.in

²Associate Professor Department of Radiodiagnosis, Army Hospital Delhi Cantt

Corresponding Author

Dr Vikas Rastogi MD (Radiodiagnosis)

Email: drvrastogi@gmail.com

Abstract

The study was conducted at the Department of Radiodiagnosis and Imaging, Army Hospital (Research & Referral), Delhi Cantt on 200 patients (114 females, 86 males) with varying age and BMI (Body Mass Index) from year 2005 to 2009.

Abdominal and pelvic sonography was done on grey scale using HDI 5000 (Philips/ATL) system. This equipment awarded a U.S. patent for Tissue Harmonic Imaging (THI).

The study was done using broadband curvilinear 2 to 5 MHz (C 5-2) transducer. This transducer can be used for both conventional B-mode and tissue harmonic imaging.

The equipment does not allow to manual selection of the frequencies. (12).The patients were 6 hours fasting prior to all examinations. These were performed by the same operator in order to achieve standardized results. Before the study was embarked standardization of the images was done with 10 normal subjects.

Correlation was done for BMI of the study population and was found that grater percentage of lesions were seen better THI in patients having BMI >25.The p value was < 0.05 (significant).

Out of the 258 positive findings assessed for total image quality in THI in comparison to CUSS the p value was <0.001 (significant). Hence the study concludes that THI is significantly better in demonstrating, defining, characterizing and eliminating the various image artifacts THI is hence recommended for routine screening and study for abdominal and pelvic organs in both males and females of varying BMI and body habitus.

Keywords-*Tissue harmonic imaging, B mode ultrasound, Total Image Quality, Artifacts,*

Introduction

Diagnostic medical ultrasound has evolved from technology used in mapping waves through liquid

(the sonar), through air (the radar) and through solids (the metal-flaw detector). In 1929 and 1935, Sokolov studied the use of ultrasonic waves in

detecting metal objects. Mulhauser, in 1931, obtained a patent for using ultrasonic waves, using two transducers to detect flaws in solids. Firestone (1940) and Simons (1945) developed pulsed ultrasonic testing using a pulse-echo technique. The B-scan modality would not have advanced to become a respectable diagnostic tool as it is now, without the development of the scan-converter and grey-scaling.

Medical ultrasound, also called sonography, is a mode of medical imaging that has a wide array of clinical applications, both as a primary modality and as an adjunct to other diagnostic procedures. The basis of its operation is the transmission of high frequency sound into the body followed by the reception, processing, and parametric display of echoes returning from structures and tissues within the body. Ultrasound is primarily a tomographic modality, meaning that it presents an image that is typically a cross-section of the tissue volume under investigation. It is also a soft-tissue modality, given that current ultrasound methodology does not provide useful images of or through bone or bodies of gas, such as found in the lung and bowel.

Tissue harmonic imaging (THI) is a new ultrasonographic technique allowing improved image quality, particularly in patients that are difficult to examine. These patients have been called 'technically difficult patients'^(1,2). The images obtained in these patients show large amounts of acoustic noise, which obscures the delineation of anatomical structures.

Approximately 20-30% of the adult patient population belongs to this difficult to scan category⁽²⁾. The main cause of the noise and clutter in these patients is due to ultrasound beam distortions that occur predominantly in the body wall and subcutaneous tissues⁽²⁾. Majority of these technically difficult patients are obese with large body habitus but some slim and small patients also may be difficult to image⁽²⁾.

Harmonic Imaging was first developed to further enhance the blood flow detection sensitivity in Color and Power Doppler applications using echo

enhancing contrast agents. Based on research results using Contrast Harmonic Imaging (CHI) the possibility was investigated that Harmonic Imaging could also improve B-mode imaging without the use of a contrast agent, particularly in difficult-to-image patients.

Harmonic waves are generated from non-linear distortion of an acoustic signal as ultrasound wave insonates tissues in the body. These are integral multiples of a fundamental transmitted frequency. The transmitted ultrasound frequency consists of a series of oscillations in the form of a sine wave that causes alternate cycles of tissue compression and relaxation. Sound velocity in compressed tissue is greater than in relaxed tissue. These variations in sound propagation are responsible for the production of tissue harmonics⁽⁵⁾. In comparison, conventional ultrasound waves are generated at the surface of the transducer and progressively decrease in intensity as they traverse the body. The processed image is formed with use of the harmonic-frequency bandwidth in the received signal after the transmitted frequency spectrum is filtered out.

Since the introduction of Tissue harmonic Imaging (THI) it has become apparent that this new technology can increase spatial and contrast resolution over conventional B-mode imaging, not only on obese patients but also in many other applications. Because the harmonic beam is formed in the body, it suffers less from reverberation artifacts generated in overlying fat and muscle. In this prospective study, comparison of tissue harmonic imaging with conventional sonography for detection, characterization and clinical utility of the displayed anatomical details in abdominal and pelvic sonography has been subjectively evaluated.

Case Study

To evaluate the total image quality in Tissue harmonic imaging as compared to conventional ultrasound technique in abdominal and pelvic ultrasonography.

The patients were fasting 6 hours prior to all examinations. They were performed by the same operator in order to achieve standardized results using a Philips (HDI / ATL) 5000 machine with a multiple-frequency broadband curved array C 5-2 transducer.

Image Quality

Diagnostic yield in ultrasound imaging depends upon the image quality and the operator skill.

Materials and Methods

The study was conducted at the Department of Radiodiagnosis and Imaging, Army Hospital (Research & Referral), Delhi Cantt on 200 patients (114 females, 86 males) with varying age and BMI (Body Mass Index) from year 2005 to 2009.

Abdominal and pelvic sonography was done on grey scale using HDI 5000 (Philips/ATL) system. This equipment awarded a U.S. patent for Tissue Harmonic Imaging (THI).

The study was done using broadband curvilinear 2 to 5 MHz (C 5-2) transducer. This transducer can be used for both conventional B-mode and tissue harmonic imaging.

The equipment does not allow to manual selection of the frequencies. The patients were 6 hours fasting prior to all examinations. These were performed by the same operator in order to achieve standardized results. Before the study was embarked standardization of the images was done with 10 normal subjects.

All examinations were done in supine, right and left lateral positions depending upon the location of the lesion and from the position, the lesion is best visualised. The organs were interrogated in transverse and longitudinal axes. To obtain the best quality and most informative image in both the modalities 'I-Scan' switch was used. This 'I-scan' switch functions by way of optimizing the transmitted pulse and the received signals for images. The TGC gains and brightness were not manually manipulated.

In all the patients, paired images of positive findings in conventional and harmonic modes were obtained at the same scan plane.^[5]

The images obtained were evaluated and subjectively compared according to the following parameters assess their total image quality in both Conventional Ultrasound (CUSS) and Tissue harmonic Imaging (THI) by the same observer. i) Resolution ii) Detail iii) Penetration iv) Cystic Clearing v) Reverberation

These positive findings were placed in three categories depending on their image qualities in Conventional Ultrasound and Tissue harmonic imaging as follows:

- Category I - **THI Better than CUSS**
- Category II- **THI similar to CUSS**
- Category III - **CUSS better than THI**

Harmonic and conventional ultrasound image qualities of the positive findings were also compared to assess their associations with age, sex and body habitus/BMI of the patients

Harmonic and conventional ultrasound images were compared on the basis of lesion visibility and lesion characteristics.

Appropriate univariate /multivariate statistical analysis of the data was done in respect with total image qualities in CUSS and THI in abdominal and pelvic ultrasonography.

Observations and Results

The study was conducted on 200 consecutive patients who were referred for abdominal and pelvic ultrasound examinations with various indications, to the Department of Radiodiagnosis, Army Hospital (Research & Referral), Delhi Cantt., a Super-speciality referral hospital between July 2004 to April 2011.

All these patients were scanned using Philips HDI (ATL) 5000, first by using conventional ultrasound mode (CUSS) and then by tissue harmonic (THI) mode technique.

These 200 patients were divided in different subgroups depending on the age, sex and Body mass index (BMI).

1. Age Distribution

Of the 200 patients studied, the youngest patient was aged 14 months and the eldest was 80 years of age. Majority of the patients (51.0%) were in the age group of 41-60 years.

2. Sex Distribution

In our study, there were 114 (57%) females and 86 (43%) males.

3. Body Mass Index (BMI) Distribution

The patients were divided in the following categories based on BMI.

- Underweight = less than 18.5
- Normal weight = 18.5 - 24.9
- Overweight = 25.0 - 29.9
- Obese = 30 or greater

4. Organ wise Distribution of Lesions

In the 200 consecutive patients that were referred in various stages of investigation, treatment and follow up that were subjected to abdominal and pelvic ultrasound examinations a total of 258

abnormal findings were detected during the examinations.

Categorisation of the lesions was done on the basis of organ distribution and lesion characteristics. Paired images obtained by the conventional and Tissue harmonic techniques were compared. Before the study was embarked standardization was done using 10 normal patients.

The images of the above lesions obtained were evaluated and placed in three categories s

1. Tissue harmonic Imaging better the Conventional USS.
2. Tissue harmonic Imaging similar to conventional USS.
3. Conventional USS. Better than Tissue harmonic Imaging.

The maximum patients are seen in the age group 51-60- 64 (24.8%) and the least in the age group below 20. (Data are the number of cases. Numbers in parentheses are percentages).

Table 1: Total Image Quality in the 258 lesions, with organwise distribution categorization

S No.	Finding/Lesion	Number of findings	THI Better than CUSS	THI similar to CUSS	CUSS better than THI
1	Liver	84	55(66.70)	24 (28.6)	04 (4.8)
2	Pancreas	14	09(64.53)	04 (28.5)	01 (7.15)
3	Biliary System	42	33(78.6)	07 (16.7)	02 (4.8)
4	Spleen	10	07(70)	02 (20)	01 (10)
5	Renal	43	34(79.1)	07 (16.3)	02 (4.65)
6	Adrenal	04	02(50.0)	02 (50.0)	0
7	Retroperitoneum	13	02(19.4)	09(63.23)	02 (19.4)
8	Uterine	13	08 (61.53)	04 (30.76)	01(7.7)
9	Ovarian	12	07 (58.34)	04 (33.34)	01(8.33)
10	Prostate	13	06 (48.15)	06 (48.15)	01(7.7)
11	Urinary bladder	10	06(60.0)	04 (40.0)	0
	Total	258	170 (65.9)	73 (28.3)	15 (5.8)

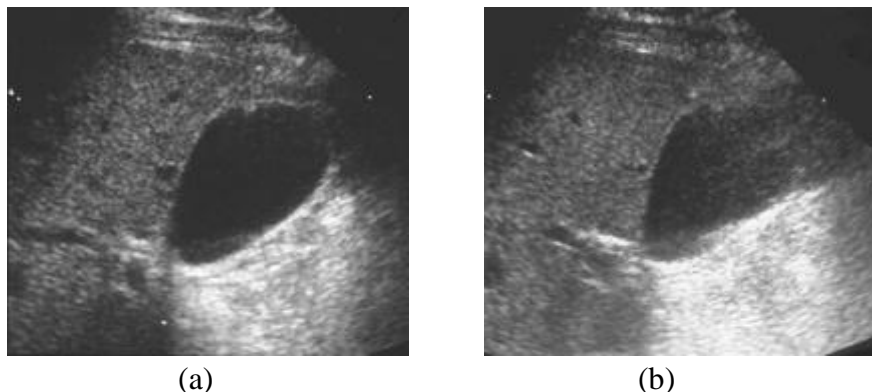


Fig 1 a) THI reveals better quality gall bladder image as compared to CUSS image b)

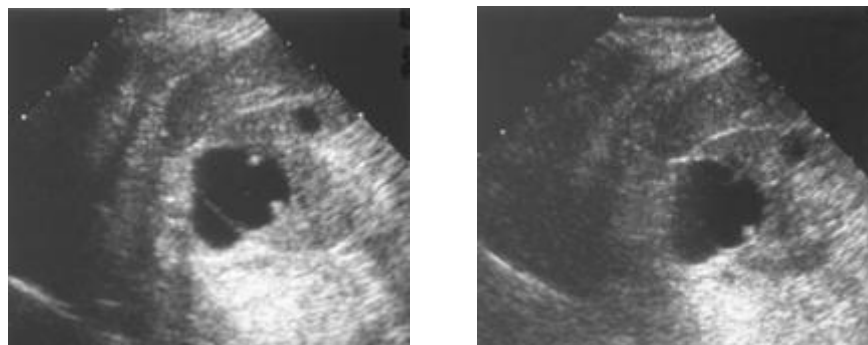


Fig 2 a) THI reveals better quality renal cyst image as compared to CUSS image b) with better demonstration of wall and septae of the cyst

The data shows the categorization of 107 selected lesions having solid-cystic areas on the basis of cystic clearing in harmonic imaging and conventional Ultrasound modes. Out of 107 lesions studied, cystic clearance was seen better on THI in 82 (76.6%) lesions and similar in both THI and CUSS in 25 (23.3%) lesions. None of the findings demonstrated better cystic clearance in CUSS in comparison to THI.

As evident from the data table above, that out of the 258 lesions detected and evaluated, 170 (65.9%) lesions show better Total image quality on THI than on CUSS. This is concurrence with majority of studies done on this subject as available in literature.

Summary and Conclusion

1) Abdominal and pelvic organs of consecutive two hundred patients were scanned using Philips HDI / ATL5000 system. The patients were between the age 40 months and 18 years.

- 2) The patients in the BMI group <24.9 and >25 , were 112 and 98 respectively. There were 14 females and 86 males in the study population.
- 3) They were subjected to conventional ultrasonography followed by tissue harmonic imaging.
- 4) A total of 258 positive findings / lesions were detected in these patients involving the abdominal and pelvic organs.
- 5) The total image quality was subjectively evaluated using various parameters like contrast and spatial resolution, elimination of artifacts, haze and noise.
- 6) The positive findings were evaluated and categorized into three categories depending upon the total image quality in THI and CUSS.
- 7) The 107 selected solid cystic lesion that was evaluated THI was found to be useful and elimination noise, haze and various image degrading artifacts.
- 8) The p value was <0.001 (highly significant).

- 9) Limitation of THI was count to be the inability to demonstrate positive findings better than CUSS in solid organ like labour and deep retroperitoneum.
- 10) Out of the 258 positive findings assessed for total image quality in THI in comparison to CUSS the p value was < 0.001 (significant).
- 11) Correlation of total image quality in THI and CUSS could not be assessed statistically due to the small sample size of patients < 30 years.
- 12) Hence our study concludes that THI is significantly better in demonstrating, defining, characterizing and eliminating the various image artifacts THI is hence recommended for routine screening and study for abdominal and pelvic organs in both males and females of varying BMI and body habitus.

References

1. *Tissue Harmonic Imaging Is It a Benefit for Bile Duct Sonography?* Dulia Ortega, Peter N. Burns, David Hope Simpson and Stephanie R. Wilson
2. Ultrasonographic evaluation of the gallbladder: comparison of fundamental, tissue harmonic, and pulse inversion harmonic imaging. Hong HS, Han JK, Kim TK, Kim YH, Kim JS, Cha JH, Choi BI
3. The value of ultrasound harmonic imaging in the diagnostics of gall bladder cholesterol polyps. Paslawski M, Krupski W, Zlomaniec J
4. Tissue harmonic imaging: is it useful in hepatobiliary and pancreatic ultrasonography? Sparchez Z
5. Tissue harmonic imaging sonography. Is the image quality in routine abdominal ultrasound improved? Stiskal M, Steinbach R, Obholzer G, Frank W, Fischer H, Czembirek H.