



Tracheobronchial Foreign Body Aspiration: Save My Child

Authors

Dr Priyanka Bansal¹, Dr Jyoti Sharma², Dr Nidhi³, Dr Soumya Saxena⁴

^{1,2}Assistant Professor, ^{3,4}Senior Resident

Dept of Anaesthesiology and Critical Care, PGIMS, Rohtak, Haryana

Corresponding Author

Dr Jyoti Sharma

Address For Correspondence- Dr Priyanka Bansal, 495 Omaxe City, Rohtak

Email: dr.priyankabansal1986@gmail.com

Introduction

Tracheobronchial aspiration of foreign body has always been a challenging task both for the surgeon as well as the anesthetist. Considering its consequences of asphyxiation, it is an emergency situation that needs close communication, cooperation as well as expertise of the anesthetist and surgeon.

More common among children younger than three years, it becomes more audacious to manage the airway, with simultaneous sharing of the surgical field with surgeon. A clinical trial of wheezing coughing and unilateral breath sounds usually confirms the diagnosis for presence of foreign body. We present a case of one and a half year old child, with history of ingestion of an unknown object. Similarly a few cases of other foreign body aspiration like peanut, battery cell and even wrapper of candy have come to our emergency OT, which were managed successfully.

Case Report

A one and a half year old male child was admitted with chief complaint of sudden respiratory distress, coughing and harsh sounds since three

hours. Upon taking history, parents admitted to having given the child melon to eat. A spot diagnosis of seed inhalation was made. The child was conscious, and had a saturation of 90% on room air, with RR 45/min, HR 138/min. chest x ray was done which couldn't locate anything significant. On examination, patient had coughing, wheezing, but no cyanosis or dysnea. Auscultation revealed decreased air entry on right side, bilateral rhonchi and crepts more on right side of the chest. Considering the emergency and gravity of situation, patient was immediately posted for foreign body removal using rigid fibroptic bronchoscope. Considering fasting of three hours, ryles tube was kept ready. In the operating room, patient was preoxygenated and induced using sevoflurane and propofol (20 mg), 30 microgram fentanyl and scoline 10 mg intravenous given. Patients airway handed over to the surgeon, with saturation of 96%, for rigid bronchoscopy. Oxygen port was attached to the rigid bronchoscope for simultaneous oxygenation. After a careful observation a melon seed of approx. 0.7 mm was located in the right bronchus which was retrieved with a grasper via bronchoscope. After a thorough

examination of both the right and left bronchus along with oral cavity for any remaining foreign body or any trauma, the bronchoscope was retrieved and ventilation with 100% oxygenation started. Patient was on spontaneous ventilation. Anaesthesia was maintained with sevoflurane along with propofol intravenous. Patient recovered well with no complications. Postoperative chest radiograph was taken to rule out any further complications

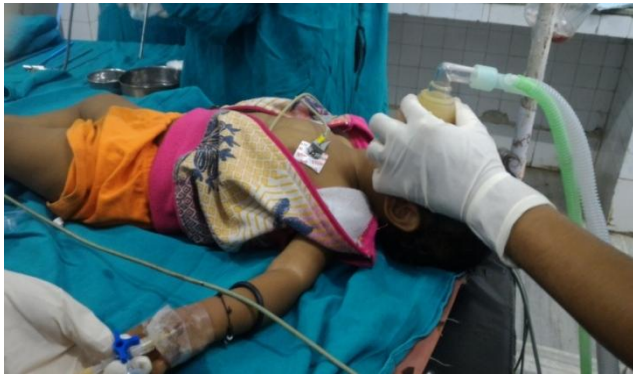

Fig 1: Pre oxygenation

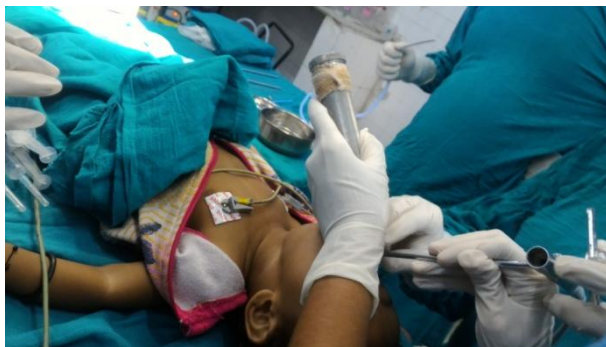

Fig 2: Intubation

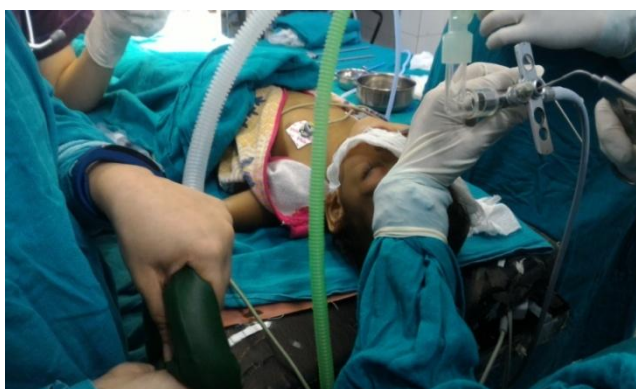

Fig 3- Assembly for Simultaneous Ventilation and Removal of Foreign Body

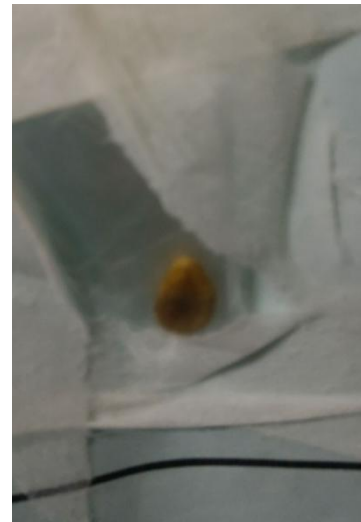


Fig 4: Watermelon Seed Found at Cricoid Level

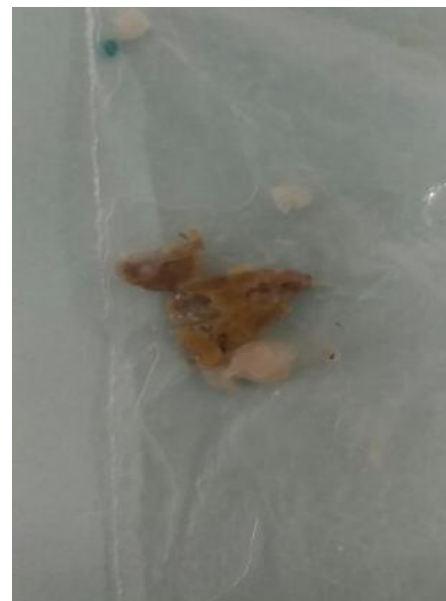

Fig 5 Peanut Shell Removed From RT Trachea

Discussion

Evidently ventilation through rigid bronchoscope proved to be a boon in our case. Although fibroptic bronchoscope is gaining much more importance as the years unfold, as the method of choice for diagnostic bronchoscopy but in case of paediatric emergency situation such as ours, rigid fibroptic bronchoscope has proved to be a rescue device unforeseen dismal complications. Tracheobronchial foreign body aspiration presents with symptoms of cough, dyspnea, wheezing along with stridor or may be cyanosis. Considering the urgency of the situation and age group of our patient, we recommend rigid fibroptic bronchoscopy as method of choice.

Close intercommunication and cooperation between the anesthetist and the surgeon along with eagle eyes on vitals, prove to be a key to success.

References

1. Shubha AM, Das K. Tracheobronchial foreign bodies in infants. *Int J Pediatr Otorhinolaryngol* 2009;73:1385-9
2. Skoulakis CE, Doxas PG, Papadakis CE, Proimos E, Christodoulou P, Bizakis JG, Velegarakis GA, Mamoulakis D, Helidonis ES. Bronchoscopy for foreign body removal in children. A review and analysis of 210 cases. *Int J Pediatr Otorhinolaryngol* 2000;53:143-8
3. Mellin Olsen J, Staender S, Whitaker DK, Smith AF. The Helsinki declaration on patient safety in anaesthesiology. *Eur J Anaesthesiol* 2010;27:592-7.
4. Biarent D, Bingham R, Richmond S, Maconochie I, Wyllie J, Simpson S, Rodriguez Nunez A, Zideman D. European Resuscitation Council Guidelines for Resuscitation 2005. Section 6 Paediatric Life Support. *Resuscitation* 2005; 67S1: S97-S133.