



## Evaluation of Socio-demographic features along with Clinical and laboratory findings in patients with Hydatid disease: A study in tertiary care hospital in Central India

Authors

Aksharaditya Shukla<sup>1</sup>, Ashok Panchonia, Khusbu Likhar, Aseem Rangnekar\*

\*Corresponding Author

Aseem Rangnekar\*

### Abstract

**Introduction:** *The hydatid cyst is a zoonosis caused by adult or larval stages of tape worms belonging to the genus Echinococcus. Hydatid disease has wide geographic distribution and is considered a public health problem. Diagnosis and treatment of Hydatid disease mandates thorough clinical and diagnostic work-up.*

**Material and Methods:** *A retrospective study undertaken at the department of Pathology in a Tertiary care Government hospital and Medical College in Central India. Socio-demographic data from a total 34 cases of hydatid disease were collected. Detailed clinical history, laboratory findings and histopathological evaluation by H & E stained slides was done for confirming the diagnosis. The data was entered in Microsoft Excel and proportions were calculated*

**Results:** *Out of 34 cases, liver was involved in 30 cases. After liver, lung is most commonly affected site showing involvement in 4 cases. Most of the patients were of 41-50 years of age. Average cyst size is 13.5 cm. Incidence of hydatid disease is more in male as compared to female with ratio of about 2.5:1. Most of the cases were found having animals at home or live in close association with animals. We found that 57.6% of symptomatic and 62.5% of asymptomatic patients had elevated Eosinophil counts.*

**Conclusion:** *Hydatid cyst can involve any part of the body and patients are may be asymptomatic or present with nonspecific symptoms. Complete diagnostic work-up including detailed clinical history, specific information about animal contact, radiological examination and complete blood counts to look for Eosinophilia and confirmatory histopathology is of utmost importance.*

### Introduction

A Cestode, *Echinococcus* is causative parasite of cyclozoonotic infection called hydatid disease. This organism requires two mammalian hosts for completion of its life cycle. Dog is the primary host, while sheep, cattle, horses and occasionally man are intermediate hosts. The sheep and cattle raising areas of the southern South America, the Mediterranean region, the

Middle East, parts of Africa, southern and central Russia, Central Asia and many regions of China are the endemic regions of hydatid disease<sup>[1,2]</sup>. In India most of the cases are reported from Andhra Pradesh, Tamil Nadu and Rajasthan.<sup>[3]</sup>

A definitive host of *E. granulosus* harbors the adult worm in its intestinal tract, whereas intermediate host carries the larval stage in its internal organs. Humans get infected by ingesting

eggs of *E. granulosus* in contaminated food as a result of close contact with dogs and sheep. The eggs hatch and the larvae penetrate the mucosa in the intestine, from where it reaches liver through portal vein. The larvae get trapped in the liver sinusoids, where they start developing into one or many unilocular cysts. The most frequently involved organs are the liver (70%) and lung (20%). Besides systemic dissemination through the portal vein, the larvae also can disseminate through lymphatic channels. Other organs, muscle (5%), spleen (1%), bones (3%), kidneys (2%), heart (1%), pancreas (1%) and central nervous system (1%) are involved only rarely.<sup>[3,4]</sup>

Even in the countries where *Echinococcus* infestation is endemic, occurrence of hydatid cyst other than liver is rare and there are very few case reports of hydatid cysts involving the parotid gland, parapharyngeal space, infratemporal fossa, maxillary sinus and pterygopalatine fossa have been reported in the literature.<sup>[5]</sup> Till date, only one case of hydatid cyst has been reported involving the subcutaneous tissue of the face primarily without any other site involvement.<sup>[6]</sup>

The majority of hydatid cysts are asymptomatic and symptom depend on location, size and pressure caused by enlarging cyst. After the development of the embryo in intestine various organs are infested by its migration through intestinal mucosa. Patients with infestation must undergo thorough systemic investigations because multi-organ involvement is seen in 20-30%.<sup>[7,8]</sup>

The diagnosis of *Echinococcus* infection mainly depends on the clinical history of the patient, diagnostic radiological findings and serologic tests. ELISA, Casoni skin tests, latex agglutination, immune electrophoresis and direct hem agglutination are serological methods, used for the diagnosis of hydatid disease. An increase in titer indicates recurrence of disease and a decrease in titer indicates resolution<sup>[9,10]</sup>. For the evaluation of mass lesions, fine-needle aspiration cytology (FNAC) is beneficial however there is potential threat to precipitate acute anaphylaxis and spread of daughter cysts<sup>[8]</sup>. Though no

casualty has been reported till date because of this but potential risk exist so it is better avoided. Ultrasonography has good diagnostic value and rarely miss any case of hydatid disease but confirmatory diagnosis in our study were made by histopathology.

### Material and Methods

Socio-demographic data from a total 34 cases of hydatid disease were collected. All the cases of hydatid cyst were diagnosed in the department of pathology. Detailed history of patient was recorded including age, sex, occupation, dietary habits, presenting complaints, operative findings and radiological findings. The data was entered in Microsoft Excel and proportions were calculated. Pathological Diagnosis: Gross examination is cyst with proper precaution, after it histopathological evaluation by H & E stained slides is done for confirmatory diagnosis.

### Results and Observation

Out of 34 cases, liver was involved in 30 cases. After liver, lung is most commonly affected site showing involvement in 4 cases. Most of the patients were of 41-50 years of age.

Cyst size varied from 6 cm to maximum of 26 cm. Average cyst size is 13.5 cm. Incidence of hydatid disease is more in male as compared to female with ratio of about 2.5:1. Most of the cases were found having animals at home or live in close association with animals.

**Table 1:** Gender wise distribution of Cases

	Close association with Animals	No close animal association	Total
Male	17	9	26
Female	5	3	8
Total	22	12	34

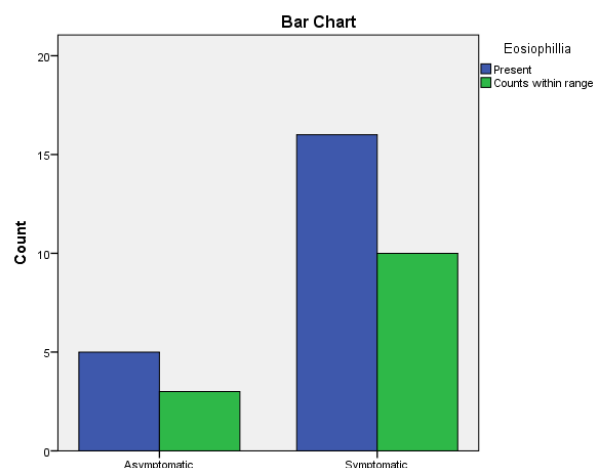
**Table 2:** Associated clinical findings

Associated finding	No. of cases
Jaundice	16
Abdominal pain	05
Asymptomatic	08
Ascites	01
Cough and Respiratory distress	04
Total	34

**Table 3:** Raised Eosinophil count with respect to symptoms

Patient condition/ Presentation	Eosinophil count		Total
	Raised	Counts within range	
Asymptomatic	5	3	8
Symptomatic	15	11	26
Total	20	14	34

**Graph 1:** Correlation of Eosinophil count and clinical symptoms



We found that 66% of all patients had elevated eosinophil counts

**Discussion**

The two major species of medical and public health importance are *Echinococcus granulosus* and *E. multilocularis*, which cause cystic echinococcosis (CE) and alveolar echinococcosis (AE), respectively. Several studies done all over the world confirm that *Echinococcus granulosus* is mainly an infection of animal parasite of dogs, foxes, wolves and jackals. Human beings are affected accidentally by contamination of food by the eggs found in feces excreted by these animals. Many of the hydatid cysts are asymptomatic and highlight the fact that the symptom depends on location, size and pressure caused by enlarging cyst [7,8]. We found that most cases had exposure to animals. Therapy with nontoxic scolicidal agents or combination chemotherapy with mebendazole is of therapeutic value in the treatment of patients with recurrence or a high risk of contamination [8].

The diagnosis of hydatid cyst is confirmed by histology [5],[6],[9]. Patients with *Echinococcus* infestation must undergo thorough systemic investigations because 20-30% have multiorgan involvement. For the evaluation of mass lesions in the cervical region, fine-needle aspiration cytology (FNAC) is beneficial however there is potential threat to precipitate acute anaphylaxis and spread of daughter cysts [6].

The diagnosis of *Echinococcus* infection mainly depends on the clinical history of the patient, diagnostic radiological findings and serologic tests. ELISA, Casoni skin tests, latex agglutination, immune electrophoresis and direct hem agglutination are serological methods, used for the diagnosis of hydatid disease. An increase in titer indicates recurrence of disease and a decrease in titer indicates resolution [7,8]. Eosinophilia can serve as one of the many diagnostic clues to look for the presence of helminthic infestation if other non-infectious causes of eosinophilia are ruled out. [10]

**Conclusion**

Hydatid cyst can involve any part of the body. Such cysts at unusual locations often produce nonspecific symptoms; consequently, it is advisable that the hydatid cyst be considered in the differential diagnosis of all cysts of the body. Thus a complete diagnostic work-up including detailed clinical history, specific information about animal contact, radiological examination and complete blood counts to look for Eosinophilia and confirmatory histopathology is of utmost importance.

**References**

1. Eckert J, Deplazes P. Biological, epidemiological, and clinical aspects of echinococcosis, a zoonosis of increasing concern. *Clin Microbiol Rev.* 2004;17: 107–35.
2. Eroğlu A, Atabekoğlu S, Kocaoğlu H. Primary hydatid cyst of the neck. *Eur Arch Otorhinolaryngol.* 1999;256:202–4.

3. Mathur PN, Parihar S, Joshi CP, Kumawat JL. Hydatid disease-still endemic in the southern region of state of Rajasthan , India : a clinical study carried out in tertiary care hospital. *Int Surg J.* 2016;3(4):1802–5.
4. Kireşi DA, Karabacakoğlu A, Odev K, Karaköse S. Uncommon locations of hydatid cysts. *Acta Radiol.*2003;44:622–36.
5. Polat P, Kantarci M, Alper F, Suma S, Koruyucu MB, Okur A. Hydatid disease from head to toe. *Radiographics.* 2003;23:475–94.
6. Gangopadhyay K, Abuzeid MO, Kfoury H. Hydatid cyst of the pterygopalatine-infratemporal fossa. *J Laryngol Otol.* 1996; 110:978–80.
7. Ozturk, Serdar Hydatid cyst in the soft tissue of the face without any primary. *Ann Plast Surg.*2001;46:170–3.
8. Michail OP, Georgiou C, Michail PO, Felekouras E, Karavokyros I, Marinos G, Giannopoulos A, Griniatsos J. Disappearance of recurrent intra-abdominal extrahepatic hydatid cyst following oral albendazole administration. *West Indian Med J* 2007; 56(4):16-21.
9. Akal M, Kera M. Primary hydatid cyst of the posterior cervical triangle. *J Laryngol Otol* 2002; 116:153-155.
10. Aletras H, Symbas N: Hydatid disease of the lung. In *General Thoracic Surgery*. 5th edition. Edited by ShieldsTW, LoCicero J, Ponn RB. Philadelphia: Lippincott Williams and Wilkins; 2000:1113–1122.
11. Khanna V, Tilak K, Mukhopadhyay C, Khanna R. Significance of diagnosing parasitic infestation in evaluation of unexplained eosinophilia. *J Clin Diagnostic Res.* 2015;9(7):DC22-DC24.