



## Uterine Lipoma- Exceptional Occurrence with Endometrial Carcinoma; More than just a Coincidence

Authors

Prapanna P.<sup>1</sup>, Sharma S.<sup>2</sup>

### Introduction

Pure lipoma of the uterus is an extremely rare entity. Most of them are postoperative chance findings following hysterectomy for leiomyoma.

Uterine lipomas are rare, benign tumours that are part of a spectrum of uterine fatty tumours. Uterine fatty tumors can be subdivided into pure lipomas, mixed lipomas which include lipo-leiomyoma, fibrolipoma and immature lipoma. The average incidence of uterine fatty tumors ranges from 0.03% to 0.2%. The more common lipomatous tumor is lipo-leiomyoma with varying amounts of the two components. Endometrial carcinoma is the commonest genital tract malignancy among women in western countries. In United States about 41,200 new cases registered every year. Its incidence in India is on the rise mainly because of the changes in the lifestyle & obesity. More than 70% of cases, are confined to uterus at time of diagnosis. Endometrial carcinoma with pure lipoma of the uterus makes an interesting but yet unproven relationship. Ultrasonography (USG) and Computed Tomography (CT) scan can help in diagnosis owing to characteristic findings.

**Keywords:** Endometrial lipoma, endometrial carcinoma.

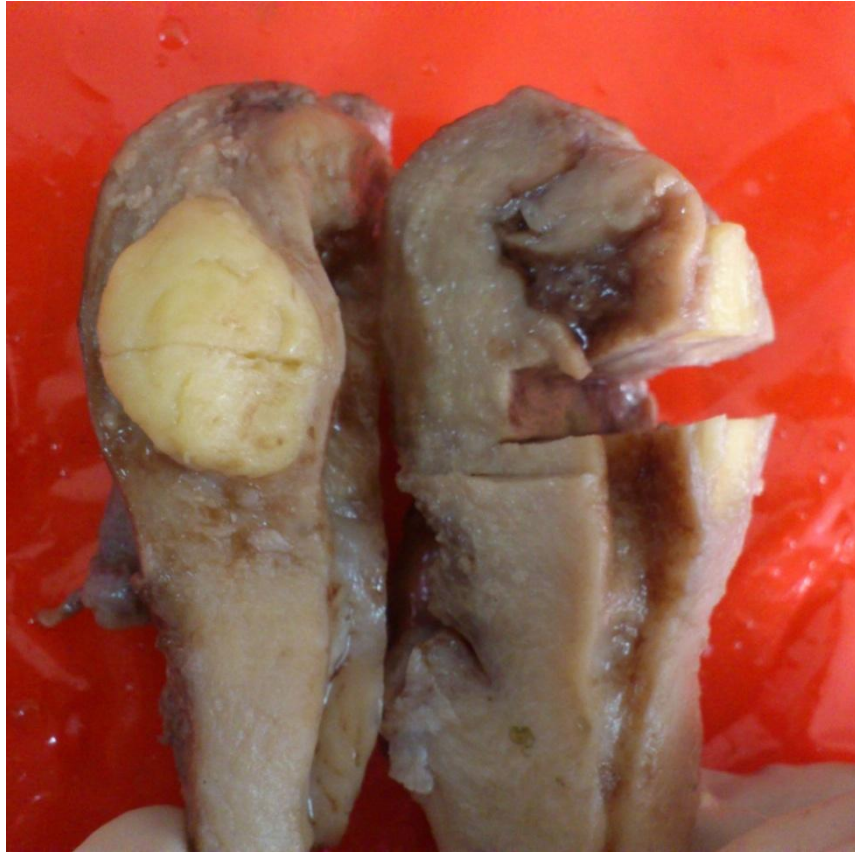### Case report

A 65 year old postmenopausal female presented with bleeding, foul smelling discharge per vaginum and dull aching pelvic pain for last 6 months. Per speculum examination was done which revealed a mucopurulent discharge. Transvaginal USG revealed thickened endometrium approx. 9mm thick, a heteroechoic endometrial polyp measuring 19.9 mm and hyperechoic lesion measuring 20X 11 mm in posterior myometrium. Hysteroscopic examination was then performed which showed hypertrophied posterior endometrial wall with anterior wall atrophy, a polyp measuring 1X2 cm over right posterolateral surface, obscuring right ostia and a normal left ostia. CT scan revealed nonspecific fat densities with dilated endometrial cavity. On endometrial curettage, abundant amount of necrotic grey white material was obtained, histopathological examination of which revealed well differentiated endometrial carcinoma. Patient was considered for surgical treatment following which an abdominal hysterectomy and bilateral salpingo-oophorectomy with pelvic lymphadenectomy was performed.

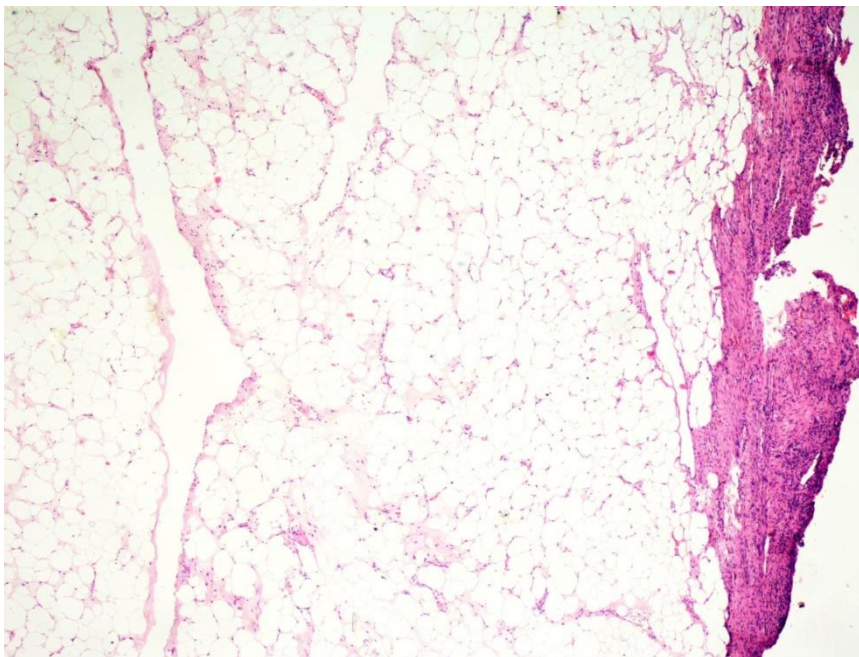
The hysterectomy specimen measured 8X5X3cm showed a well circumscribed yellow fatty lesion in the posterior wall of uterus, measuring

1.5X1cm (Figure 1). Polypoidal mass measuring 3X1X1cm was seen in the cavity. Endometrial thickness was increased up to 1.5 cm. On histopathological examination of the tissue from yellow lesion, the tumor was composed of mature

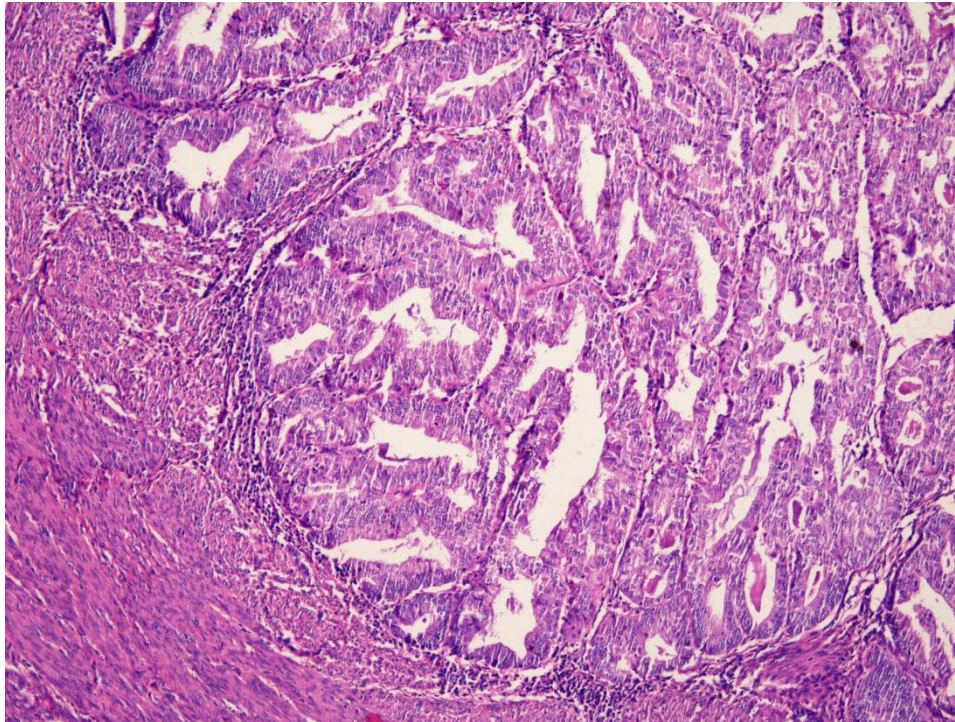
fat cells without any intervening smooth muscle cells (Figure 2). Polypoidal mass showed irregularly distributed glands infiltrating the myometrium confirmed as well differentiated endometrial carcinoma (Figure 3, 4).



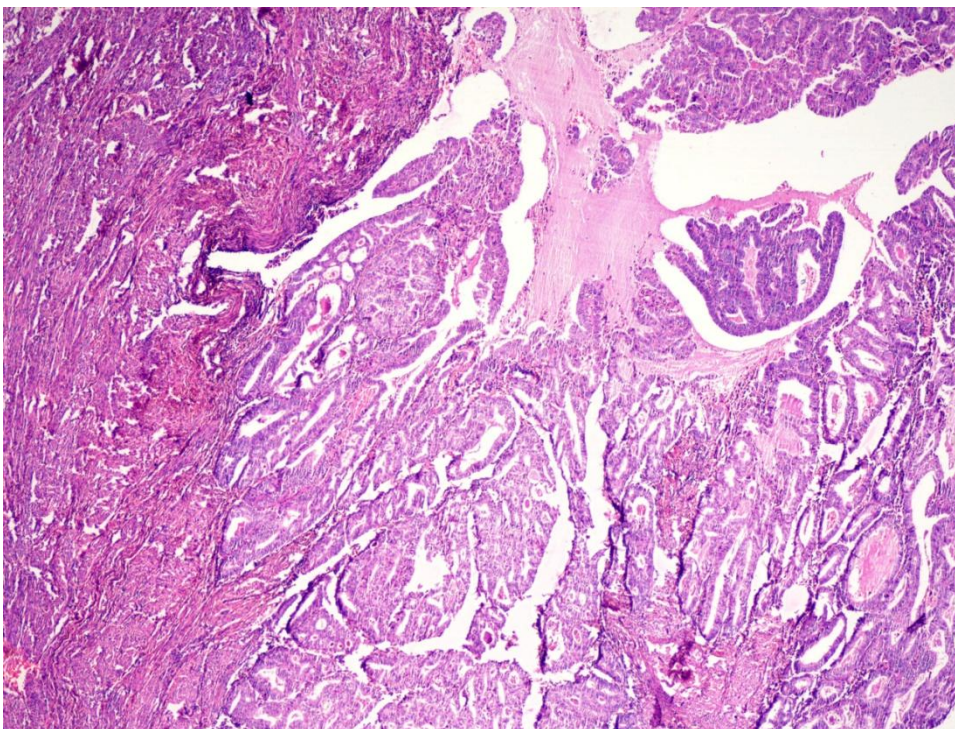
**Fig.1** Gross picture of hysterectomy specimen showing well defined yellow fatty lesion.



**Fig.2** Photomicrograph showing mature adipose tissue consistent with lipoma (200X)



**Fig.3** Photomicrograph showing well differentiated endometrial carcinoma (200X)



**Fig 4** Photomicrograph showing well differentiated endometrial carcinoma (200X)

### Discussion

Lipomatous or fatty tumors are rare benign neoplasms of the uterine corpus.<sup>1</sup> The histogenesis of these lipomatous tumors in the uterine wall continues to be an enigma.<sup>1</sup> As fat tissue is not native to the uterus, various theories of histogenesis have been proposed. These include

misplaced embryonic fat cells, metaplasia of the muscle or connective tissue cells into the fat cells<sup>2</sup>, lipocytic differentiation of specific primitive connective tissue cells, proliferation of perivascular fat cells accompanying the blood vessels into the uterus<sup>3</sup>, inclusion of the fat cells into the uterine wall during surgery or fatty

infiltration or degeneration of the connective tissue<sup>4</sup>. Most of the lipomatous tumors are seen in post menopausal women which also point towards loss of ovarian function as possible etiology.<sup>5</sup> Some authors have suggested the role of disturbed fat metabolism in old age as a plausible cause of development of uterine lipomas.<sup>6</sup> Theory of neo-metaplasia suggested by Seinski is well supported by immunohistochemical studies done by Mignona et al<sup>7</sup>. Mignona et al described vimentin, smooth muscle actin and S 100 positivity in uterine lipomas, suggesting probable origin from smooth muscle. Lipomas of uterus usually appear in women with a higher mean age than is common for leiomyomas, mainly after the menopause; our patient was 65 years of age at the time of diagnosis. Uterine lipomas may present with urinary frequency, uterine bleeding,<sup>3,4</sup> and a smaller proportion with abdominal pain, when these tumours reach larger dimensions. They are often misdiagnosed as carcinomas due to the old age of the patients, rapid progression of abdominal swelling, abdominal pain, and the well-circumscribed, hyperechoic texture on ultrasonography (USG). In our case USG findings also reflected these findings. Preoperative diagnosis can be made to avoid unnecessary surgery by current imaging modalities such as computed tomography (CT) and magnetic resonance imaging (MRI). The diagnosis of primary pure lipoma on histopathology should be made only if the smooth muscle cells are confined to the periphery. Uterine lipomas can be considered for the differential diagnosis of uterine mass in postmenopausal women. They have excellent prognosis except when they are associated with other tumors as in our case it was associated with endometrial carcinoma.

Uterine lipoma with endometrial carcinoma is a very rare finding, till today only three such case reports have been published in this context.<sup>8,9</sup> Whether the association between endometrial carcinoma and uterine lipoma is purely coincidental or have some underlying histopathogenesis remains elusive. Krenning<sup>2</sup> et

al discussed the role of androgen to estrogen conversion locally in the lipoma as a possible cause of endometrial carcinoma as well as polyps. Certain associations of uterine lipoma with endometrial polyp<sup>9</sup>, ovarian thecoma<sup>10</sup>, cervical carcinoma were considered to be chance findings by the authors who described them.

To conclude, uterine lipomas are uncommon entities and even more uncommon is their association with endometrial carcinoma. Our cases represent one of these rare entities and have findings that correlate well with clinical, radiological and histopathological findings described for such cases in the literature. Uterine lipomas in pure forms and their association with other malignancies of female genital tract require further studies to prove any relationship.

#### References

1. Gupta RK, Hunter RE. Lipoma of the uterus. Review of literature with views of histogenesis. *Obstet Gynecol* 1964; 24: 255-257.
2. W. Sieinski, Lipomatous neo-metaplasia of the uterus. Report of 11 cases with discussion of histogenesis. *International Journal of Gynecological Pathology*, 1989; 8: 357-363.
3. Resta L, Maiorano E, Piscitelli D, Botticella M Lipomatous tumors of the uterus: clinico-pathological features of 10 cases with immunocytochemical study of histogenesis. *Pathology Research and Practice* 1994; 190: 378-383.
4. Dharkar DD, Kraft JR, Gangaharan D. Uterine lipoma. *Arch Pathol Lab Med* 1981; 105: 43-45.
5. Bruntsch KH Large solitary lipoma of the uterus and cervical carcinoma. *Zentralbl Gynakol*. 1951; 73:96-99.
6. Lin KC, Sheu BC, Huang SC. Lipoleiomyoma of the uterus. *Int J Gynaecol Obstet* 1999; 67: 47-49.
7. Mignogna C, Di Spiezio Sardo A, Spinelli M, Sassone C, Cervasio M, Guida M, *et*

- al.* A case of pure uterine lipoma: Immunohistochemical and ultrastructural focus. *Arch Gynecol Obstet* 2009; 280: 1071-1074.
8. Douvier S, Nabholz JM, Brechet E, Collin F, Cuisenier J. The association of uterine lipoma and cancer of endometrium. Diagnostic and etiopathogenic approach. *Gynecol Obstet Biol Reprod.* 1990; 19: 301-305.
  9. Reslova T, Resl M. The coincidence of pure lipoma, leiomyoma, and endometrial carcinoma. *Acta Medica* 2003; 46: 129-130.
  10. R. Vilallonga, A. García, J. Castellví, J. M. Fort, M. Armengol, and S. Ramón y Cajal, "Lipoma of the Uterine Corpus: Exceptional Eventuality Combined with an Ovarian Thecoma," *Case Reports in Medicine*, vol. 2009, Article ID 340603, 4 pages, 2009. doi:10.1155/2009/340603