



## Study of Liver in Post Mortem Cases in Tertiary Care Centre – A Study of 4 Years

Authors

**Dr Shailendra Singh Thakur<sup>1</sup>, Dr Vipin Todase<sup>2</sup>**

<sup>1</sup>Assistant Professor, Dept of Pathology, M.G.M Medical College, Indore, M.P state, India

<sup>2</sup>Senior Resident, Dept of Pathology, M.G.M Medical College, Indore, M.P state, India

\*Corresponding Author

**Dr Vipin Todase**

Email: [vips.todase@gmail.com](mailto:vips.todase@gmail.com)

### Abstract

*Post mortem evaluation of the liver has been very useful in reaching the diagnosis of patient cause of death. Autopsy studies provide us with useful baseline data to start a step towards finding cause of death. The study was conducted in the department of Pathology, M.G.M Medical College, Indore (M.P) from 2013 to 2017. Liver specimens were collected from 127 cases of post mortum as a part of examination of multiple viscera, over a period of 4 years. Sections from representative area were submitted for processing, sectioned and stained with Hematoxylin and Eosin stain. The present study was retrospective study. It is observed that 127 cases were evaluated out of which 85 (66.93%) were males and 42 (33.07%) were females. Out of 127 specimens, 31(24.40%) are cases of normal liver morphology followed by chronic venous congestion 41 (32.28%) cases, fatty change 26 (20.47%) cases,, steatohepatitis hepatitis 18 (14.5%) cases, cirrhosis 10 (7.87%) cases, Metastasis in 01 (0.78%)case. The aim of the study was to study spectrum of histopathological lesions encountered in liver autopsy. In this autopsy study of 127 cases of liver specimens, the diagnosis found are fatty change, chronic venous congestion, portal triaditis and cirrhosis were the main findings and metastasis to liver was reported in one case.*

**Keywords:** Alcoholic Cirrhosis; Liver; autopsy.

### Introduction

Autopsy study provides useful and valuable information about the disease to find out the exact cause of death. The Main Purpose of Autopsy is to know the exact cause of death. Liver is the main site of many metabolic activities. It is vulnerable to many metabolic, toxic, microbial and circulatory insults and is one of the most frequently injured organ in the body. Secondaries are also very common in liver from malignancies of organs like

gastrointestinal tract. Diagnosis found is fatty change, chronic venous congestion, portal triaditis and cirrhosis were the main findings and metastasis to liver was reported in two cases. In some cases moderate to marked autolytic changes are seen in the specimens as they are improperly preserved or brought by the police quite late to Pathology Department / histopathology laboratory.

The main purpose of the study was to analyse different patterns of liver diseases that are reflected

in the morphology of liver at autopsy to study the clinicopathological correlations in various hepatic lesions. Autopsy study is useful to monitor the cause of death and to plan medical strategy<sup>[1]</sup>. Alcohol abuse generally leads to mainly three liver diseases; these are fatty liver, hepatitis and alcoholic cirrhosis. Any one or all the three can occur at the same time, in the same patient<sup>[2]</sup>.

**Materials and Methods**

127 specimens of liver of the deceased were observed, received in the Department of Pathology, M.G.M Medical College India, Specimens were examined grossly as well as microscopically. Post-mortems tissue usually received in department of pathology are cases of sudden death in which cause is unknown, road / railway accidents, burns, drowning and poisoning. Liver specimens were received either as a part of examination of multiple viscera. Tissues fixation is done in 10% formalin, paraffin blocks were made. Only formaline fixed tissues are included in the study. Autolysed tissues are excluded from study. Sections were cut and were stained with H & E and examine for any pathology.

**Results**

It is observed that 127 cases were evaluated out of which 85 (66.93%) were males and 42 (33.07%) were females [Table 2]. Out of 127 specimens, 31(24.40%) are cases of normal liver morphology followed by chronic venous congestion 41 (32.28%) cases, fatty change 26 (20.47%) cases,, steatohepatitis hepatitis 18 (14.5%) cases, cirrhosis 10 (7.87%) cases, Metastasis in 01 (0.78%) case [Table 1]. [Figure 1]

Fatty liver is common more common in male patients than female. Age group of 50-60 years of age shows increase prevalence of fatty changes. [Table 3] [Figure 1]

Cirrhosis of liver is also more common in male than female and age proponderence is more common in the age 50 – 60 years. [Table 4] [Figure 2] [Figure 3]

**Table 1** Distribution of histopathological diagnosis

Histopathological Diagnosis	No Of Cases 127	Percentage (%)
Normal	31	24.40%
CVC/Acute Sinusoidal Congestion)	41	32.28%
Fatty Liver	26	20.47%
Steatohepatitis	18	14.17%
Cirrhosis	10	7.87%
Malignancy (Metastasis)	01	0.78%

**Table 2** Histopathological Diagnosis With Relation To Sex

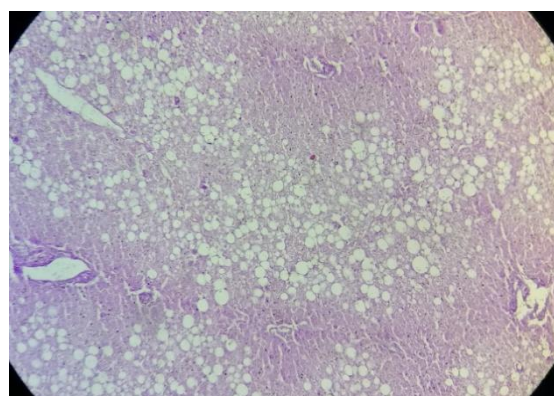
Diagnosis	Male	Female	Total Cases
Normal	19	12	31
(CVC/ Acute Sinusoidal Congestion)	22	19	41
Fatty Liver	20	06	26
Steatohepatitis	14	04	18
Cirrhosis	09	01	10
Metastasis	1	0	01
Total	85	42	127
Percentage(%)	66.93	33.07	

**Table 3** Cases of Fatty Change

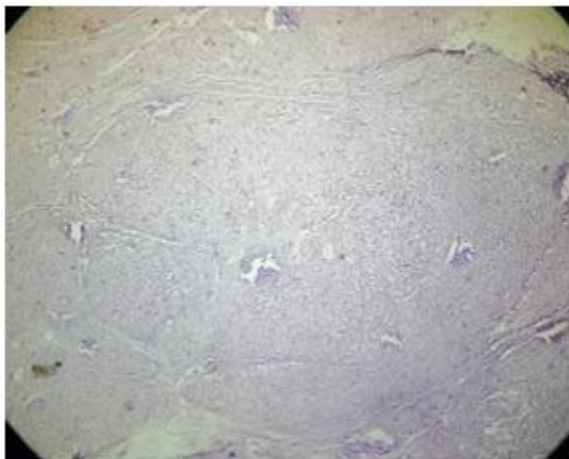
Age (years)	Male	Female	Total	Percentage%
51-60	09	04	13	50.00%
41-50	05	01	06	23.07%
31-40	04	01	05	19.23%
21-30	02	00	02	7.69%
Total	20	06	26	

**Table 4** Cases Of Cirrhosis of liver

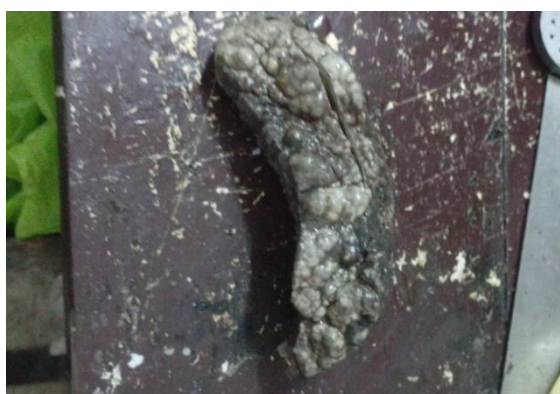Age (years)	Male	Female	Total	Percent age%
51-60	05	00	05	50%
41-50	02	01	03	30%
31-40	01	00	01	10%
21-30	01	00	01	10%
Total	09	01	10	



**Figure 1** Histopathological picture of fatty liver



**Figure 2** Histopathological picture of cirrhosis of liver



**Figure 3.** Gross picture of mix nodular cirrhosis of liver

### Discussion

Histopathological study is an important value in improving the knowledge and diagnostic setup for clinical assessment. In this study, incidences were found higher in 4th and 6th decades of life. Out of 127 cases, 85 males (66.93%) and 42 females (33.07%) were found to be affected. Men were more prone to death by diseases as compared to women the reason being men were beard earners as compared to women which makes them prone to alcohol consumption.

Alagarsamy J. et. al<sup>[3]</sup> observed that cases with normal histology of liver was 22%, fatty change 20%, hepatitis 10%, congestion 26%, cirrhosis 16%, hemangioma 6%. In comparison to this study, our study also have normal histology of liver in 26.56%, fatty change 21.87%, congested liver 20.31%, chronic hepatitis 12.5%, steatohepatitis 3.12 % and cirrhosis 9.37 %, which is similar to their result.

Thamil Selvi R. et.al<sup>[4]</sup>. observed fatty changes in 26.9% followed by normal 25.9%, congestion 16.7 %, hepatitis 13.9%, cirrhosis and abscess 7.4% and malignancy 1.9% which is similar to our result. The high incidence of fatty change in liver is because a large percentage of people in this region take alcohol which is major causative factor for developing fatty change. Regular intake of alcohol between 40-80 gm increases the liver weight and frequency of fatty changes in liver<sup>[5]</sup>. Cirrhosis is the end stage of many chronic liver diseases. This term refers to diffuse hepatic fibrosis with replacement of normal lobular architecture by parenchymal nodules separated by fibrous tissue. Architectural changes are histologically best appreciated on a reticulin stain<sup>[6]</sup>. Alcohol consumption is found to be one of important risk factors for liver diseases. Also men indulge themselves in alcoholism, smoking etc. Mainly people from lower and middle class tend to fall in this category. Regular intake of alcohol between 40-80 gms increases the liver weight and frequency of fatty change in liver. Fatty liver might be the most common silent liver disease among general population in Tehran, Iran.<sup>[7]</sup>

Most of the cases that were reported in our hospital were due to Road traffic accidents. Also autopsies were being performed in suspected cases of poisoning, burns, drowning etc.

### Conclusion

In present study the most common liver disease is fatty change in liver (20.47%). Majority of steatosis cases have history of chronic alcoholism (80.42%). Most common cases coming for postmortem examination are road traffic accidents, 25 cases out of 64 cases (39.06%) as antemortem liver function tests are not available in these cases, from history, gross and histopathological examination ,chronic consumption of alcohol may be the most probable cause of steatosis in western Odisha in the age group of 21-50 years. The most common hepatotoxin causing chronic liver disease is alcohol. A diagnosis of drug- or toxin- induced liver injury may be made on the basis of a temporal association of liver

damage with drug or toxin exposure, recovery (usually) upon removal of the inciting agent, and exclusion of other potential causes.

Hence community awareness is highly needed to modify their lifestyles and avoid excess alcohol consumption to prevent pathological changes in liver.

### Acknowledgement

Authors acknowledge the immense help received from Dept. Of Pathology M.G.M Medical College, Indore., the scholars whose articles are cited and included in references of this manuscript. The authors are also grateful to authors/ editors/ publishers of all those articles, journals and books from where the literature for this article has been reviewed and discussed and our colleges who supported us.

### References

1. Rezek R, Philipp and Max Millard: In autopsy pathology, Springfield, Thomas. 1963; 464-467.
2. John T Galambos: Liver in 4th Ed. Gastroenterology, WB Saunders Company, Philadelphia. 1985; 2985-3048.
3. Alagarsamy J, Muthureddy Y et al. Incidentally discovered diseases – An Autopsy Study of Fifty Cases. International Journal of Science and Research.2014; 3(5):1332.
4. Thamil Selvi R, Selvam V et al. Common Silent Liver Disease In and Around of Salem Population: An Autopsy Study. Journal of Clinical and Diagnostic Research.2012;6 (2):207-10.
5. Singal P,Kaur M, Deepika. Incidental Findings in Autopsy Examination of Liver : A Study of 70 Cases .Ann. Int. Med. and Den. Res. 2017;3(3),PT30-PT32.
6. Desmet V, Rosai J. Liver : Rosai and Akerman's Surgical Pathology. Vol 1.St Louis,USA : Elsevier Mosby; 2004:925-940.
7. Rosoul Sotoudehmanesh, Masoud Sotodueh, Ali Ali- Asgari ,et al. Silent liver diseases in

Autopsies from Forensic Medicine of Tehran. Archives of Iranian Medicine, 2006; 9 (4): 324-28.