

**Research Paper**

Clinical Profile and Management of Mirizzi's Syndrome- Ten years Experience in a Tertiary Care Hospital in a Developing Country

Authors

Muzafar Bashir¹, Aijaz Ahmad Malik², Nadeem Ul Nazeer³, Showkat Ali Zargar⁴

¹M.B.B.S, M.S, Ex Senior Resident, Department of General Surgery, Sher-i-Kashmir-Institute-of-Medical-Sciences (SKIMS), Soura, Srinagar, Kashmir, 190011, INDIA.

²M.B.B.S, M.S, Professor, Department of General Surgery, Sher-i-Kashmir-Institute-of-Medical-Sciences (SKIMS), Soura, Srinagar, Kashmir, 190011, INDIA.
Email: drajazamalik@yahoo.com

³M.B.B.S, M.S, Mch, Senior Resident, Department of CVTS, Sher-i-Kashmir-Institute-of-Medical-Sciences (SKIMS), Soura, Srinagar, Kashmir, 190011, INDIA.
Email: nadeem_kawoosa@yahoo.co.in

⁴MBBS, MD, DM Gasterentology, Ex Professor and Head, Department of Gasterentology, Sher-i-Kashmir-Institute-of-Medical-Sciences (SKIMS), Soura, Srinagar, Kashmir, 190011, INDIA
Email: showkatzargar6@gmail.com, showkatzargar@yahoo.com

Corresponding Author

Dr Muzafar Bashir

Address Kharibagh, Chadoora, Budgam , 191113, INDIA
Phone number 7006407055, Email: drmuzafarbashir@gmail.com

Abstract

Background: *Mirizzi's syndrome (MS) is defined as an extrinsic compression of common hepatic duct from an impacted stone in cystic duct or Hartmann's pouch. Sometimes stones erode through main duct leading to fistula formation. Preoperative awareness is necessary to avoid intra operative complications because of altered anatomy locally. The aim of this study was to assess magnitude of syndrome in patients getting operated for cholelithiasis, role of pre-operative evaluation [laboratory and radiological or endoscopic retrograde cholangio pancreaticography (ERCP)] for suspecting the syndrome and subsequent role of ERCP and various surgical procedures.*

Methods: *The study was descriptive conducted both retrospectively and prospectively. In the retrospective group, all records, demographic characteristics, clinical features, laboratory investigations, imaging, surgical records and histopathological examination (HPE) were reviewed. In the prospective group, patients who had suspicion of MS underwent specific investigations and subsequent surgery if needed.*

Results: *During study period of ten years, 6286 patients underwent cholecystectomy. Out of these 150 patients were diagnosed to have MS with an incidence of 2.3%. Pain right hypochondium was the most common presenting feature. Type- I MS was most common (82.6%). Most common laboratory abnormality was raised alkaline phosphatase (ALP, increased in 87% of patients) and bilirubin (increased in 52% patients). Ultrasonographic (USG) finding were suggestive in 61.3%, ERCP and magnetic resonance cholangio pancreaticography (MRCP) in 34.6% and 4.0% respectively. Majority were treated with choleystectomy only. Overall complications after ERCP procedures were 6.8% and 5.3% patients developed complications post operatively. No patient underwent a laparoscopic procedure.*

Conclusion: *Type –I MS was most common because of high incidence of gallstone disease in our state. Pre-operative suspicion can be made by a combined evaluation approach including high bilirubin and ALP, USG finding suggestive of MS, MRCP, while ERCP can be diagnostic as well as a good palliation procedure but surgery is the definitive treatment.*

Keywords: *Mirizzi's syndrome; MS, surgical management; ERCP; Endoscopic retrograde cholangio pancreaticography; Cholecystectomy.*

Introduction

Mirizzi's syndrome (MS) is an uncommon complication of gall stone disease and refers to common hepatic duct (CHD) obstruction caused by extrinsic compression from an impacted stone in cystic duct or Hartman's pouch. In 1948 Argentinean surgeon Pablo Mirizzi first described the syndrome, in the setting of long standing cholelithiasis and cholecystitis^[1]. MS is a rare complication with reported incidence of 0.05 – 2.7%^[1,2,3] and is often not recognized pre-operatively. In 1982, MC Sherry et al^[4] classified syndrome into two types i.e., type-I which involves external compression of CHD by stone impacted in the cystic duct and type – II which occurs when a cholecysto-choledochal fistula is caused by stone migration into common hepatic duct. Csendes et al^[5] further suggested a modified classification. In this classification type – II is cholecysto-choledochal fistula that involves less than one third of the circumference of the bile duct, type III is a fistula involving upto 2/3rd of circumference and type – IV is the complete obstruction of the duct.

Later Nagakawa et al, in 1998^[6] proposed another classification of their syndrome where type I denotes extrinsic compression (stenosis) of CHD by stone generally impacted in the cystic duct or in the infundibulum of gall bladder (GB), type II-fistulization of CHD from a stone impacted in the cystic duct or in the infundibulum of the GB, type III-CHD stenosis due to stones at cystic duct confluence, type IV- CHD stenosis caused by cholecystitis without stones in the cystic duct or infundibulum of the GB. The syndrome is encountered more frequently in females and pain in the right hypochondrium is the most common presenting feature. This condition holds a great risk of serious injury to CHD or common bile duct (CBD) when a standard cholecystectomy technique is used^[7]. Since accurate pre-operative diagnosis remains difficult^[8,9], awareness and recognition of the disease condition are of the utmost importance for safe and optimal management. This is a dangerous alteration to

anatomy, rarely recognized pre-operatively and has potential to lead to significant morbidity and biliary injury particularly in the laparoscopic era.

Materials and Methods

This study was descriptive and consisted of retrospective review and prospective evaluation of patients who were treated in our institute with a diagnosis of MS. The study population consisted of all the patients having gall bladder stone disease. The retrospective period encompassed between January 2000 to June 2007 (131 patients) and prospective period encompassed July 2007 to October 2009 (19 patients). The aim of study was to assess magnitude of this syndrome in symptomatic gall stone disease in patients undergoing cholecystectomies, their demographic and clinical profile, methods for diagnosing the condition pre-operatively and subsequent endoscopic and surgical methods employed and their outcome.

All records, demographic characteristics, clinical features, laboratory investigations, imaging, surgical records and histopathological examination (HPE) were reviewed. In the prospective group, all patients suspected of having MS preoperatively were included in the study. The patients were subjected to routine investigations {(including liver function tests (LFT)}, ultrasonographic evaluation of abdomen. For prospective period all patients who underwent cholecystectomy were subjected to questionnaire. Patients who had associated jaundice, cholestasis, cholangitis, intra hepatic ductal dilatation and suspicion of MS underwent endoscopic retrograde cholangio pancreaticography (ERCP). ERCP was used in usual manner and MS was suspected on following ERCP findings:

Normal CBD – diameter below level of stone
Filling defect at confluence of cystic and bile duct.
Dilatation of hepatic duct above level of obstruction.

Endoscopic sphincterotomy was done after visualization of stones. CBD was cleared by use of dormia basket, balloon catheter or mechanical

lithotripsy according to the size of stone. In event of failure of complete clearance, a nasobiliary drain or a plastic stent was put in CBD. In patients who were critically sick due to pyogenic cholangitis at presentation, ENBD (endo nasal biliary drain) was placed in CBD and stone extraction was deferred till sepsis settled.

All patients underwent surgery in the same hospital sitting. Abdomen was opened by subcostal incision and GB was inspected. Incision on fundus was made and the impacted stone removed. GB was also inspected from inside and intraoperative cholangiography was done to determine the location and size of any fistula, stenosis, ductal stone and to establish the integrity of CBD wall. Patients were classified into four types of MS according to Csendes classification. Cholecystectomy alone was done mainly in type-I MS. In patients who were having associated CBD – stones, cholecystectomy with CBD exploration and T-Tube drainage was done. Partial cholecystectomy was the safe procedure for type II MS. For patients with fistula involving 1/3 – 2/3rd of CBD circumference, partial cholecystectomy with choledochoplasty with T-Tube drainage was done. All patients were followed at 3, 6 & 12 months thereafter. The limitation of the study was that it was a hospital based study- and not a population based study. Also, the study contains combination of retrospective and prospective data.

Results

During a period of ten years, a total of 6286 cholecystectomies were performed. Among these patients, one hundred and fifty patients (2.3%) were diagnosed to have MS. Mean age of patients was 47.2 years with a range of 14-80 years. Most common age group involved was 21-40 years (26.7%). Females were mostly involved with a male female ratio of 1:3. Pain RHC was most common complaint in our patients. Twenty six percent of patients had associated jaundice at the time of presentation. Alkaline phosphatase (ALP) levels were raised in 87 (58%) patients and among

them, most patients had levels between 321-500 I.U. Mean ALP was 675.9 I.U. Majority of patients [78(52%)] had bilirubin levels between 1-5 mg%. Mean serum bilirubin was 2.9 mg%. Mean follow up of patients in retrospective group was 4.3 years and in prospective group was 9 months. The demographics, clinical characteristics and laboratory parameters in the studied subjects are given in table 1 and table 2.

Table 1 Demographics and clinical characteristics in the studied subjects.

Demographic characteristics	
Total No. of cholecystectomies performed	6286
Total No. of patients diagnosed as Mirizzi's syndrome	150 (2.3%)
Mean age (range)	47.2 yrs (14-80)
Male: Female	1:3
Clinical presentation of studied patients	
Clinical features	
Pain right hypochondrium	89 (59.3%)
Jaundice	39 (26%)
Fever	32 (21.3%)
Vomiting	26 (17.3%)
Cholangitis	24 (16%)
More than one symptom was present in many patients.	

Table 2 Laboratory parameters in the studied subjects.

Laboratory abnormalities		
ALP levels (I.U)	n (%)	Mean
Upto 320	63(42%)	675.9
321-500	38(25.3%)	
501-1000	28(18.6%)	
>1000	21(14%)	
Serum bilirubin (mg%).		
<1	58(38.6%)	2.9 mg%
1-5	78(52%)	
5.1-10	9(6%)	
>10	5(3.3%)	

ALP- Alkaline phosphatase levels.

USG was the most common investigatory tool used in our patients, suspecting the diagnosis in 61.3% of cases (Fig 1). Most common ultrasonographic (USG) finding was cholelithiasis with choledocholithiasis and intra hepatic ductal dilatation [54 (36%)]. The patients who had associated CBD stones underwent ERCP. Six of

our patients had pre operative diagnosis by MRCP. The patients who presented with cholangitis underwent pre operative ERCP followed by surgery. ERCP was the initial therapeutic approach in 59/150 patients. Out of these, CBD clearance was done in 39 (66.1%) patients, ENBD catheter was put in 10 (16.9%) patients and stenting was done in 10 (16.9%) patients. The USG findings, pre-operative diagnostic method, initial approach, and ERCP procedures performed is tabulated in table 3, table 4a and 4b.

Table 3 USG Findings, Pre-operative diagnostic method, Initial approach.

USG Findings	
Findings	%age
Cholelithiasis with choledocholithiasis and intra hepatic ductal dilatation	54 (36%)
Cholelithiasis with impacted stone at cystic duct with mucocele	40 (26.6%)
Cholelithiasis with stone at Hartmann's pouch	20 (13.3%)
Cholelithiasis with impacted stone at cystic duct with contracted gall bladder	19 (12.6%)
Cholelithiasis with stone impacted at cystic duct with intrahepatic duct dilatation.	13 (8.6%)
Cholelithiasis with choledocholithiasis with oriental cholangiohepatitis (OCH).	4 (2.6%)

Table 5 Type of surgical procedure used

	Type of Mirizzi's syndrome				
	TOTAL	I	II	III	IV
Cholecystectomy	90 (60%)	90	0	0	0
Partial cholecystectomy	24 (16%)	13	11	0	0
Cholecystectomy +Choledocholithotomy + T-Tube drainage	16 (10.6%)	16	0	0	0
Partial cholecystectomy+Ch oledocholithotomy with choledochoplasty with T tube drainage	6 (4%)	0	3	3	0
Cholecystectomy with Choledochoduodenostomy	5 (3.3%)	5	0	0	0
Partial cholecystectomy with choledochoplasty	4 (2.6%)	0	4	0	0
Cholecystectomy with suture repair of cholecysto choledochal fistula	2 (1.3%)	0	2	0	0
Partial cholecystectomy with choledochoplasty with T tube drainage	2 (1.3%)	0	0	2	0
Cholecystectomy with hepaticojejunostomy	1 (0.6%)	0	0	0	1

Table 6 Distribution of Mirizzi syndrome

TYPE	n (%)
Type-I	124 (82.6%)
Type – II	20 (13.3%)
Type-III	5 (3.3%)
Type – IV	1 (0.6%)

T tube cholangiogram was done at one week post op. The patients were followed up at regular intervals (one week, three weeks, three months,

Table 4a and 4b Pre-operative diagnostic method, Initial approach method, ERCP procedures performed.

Table 4a

Pre-operative diagnostic method	
Modality	n (%)
USG	92 (61.3%)
ERCP	52 (34.6%)
MRCP	6 (4%)
Initial approach method	
	n (%)
Surgery	91(60.6%)
Endotherapy and surgery	59 (39.3%)

Table 4b ERCP procedures

Endotherapy	n (%)
CBD clearance	39 (66.1%)
ENBD	10 (16.9%)
Stenting	10 (16.9%)

CBD- common bile duct,

ENBD-Endo nasal biliary drainage

Surgery was initial procedure in 91 (60.6%) patients. Cholecystectomy constituted the main surgical procedure for type I patients and rest of patients underwent partial cholecystectomy. The surgical procedures performed are given in table 5.

then 6 monthly). The patients were subjected to baseline investigations (including LFT), USG abdomen at follow up. Complications occurred in only 4 patients after ERCP and only few patients developed complications post operatively (table 7). Four of our patients developed biliary stricture on follow up.

Table 7 Complications after ERCP and surgery

Complications post ERCP					
	TOTAL	MS I	MS II	MS III	MS IV
Pancreatitis	1 (1.6%)			1	
Papillary bleed	1 (1.6%)		1		
Biliary leak	1 (1.6%)			1	
Drug allergy	1 (1.6%)			1	
Total	4 (6.8%)				
Post surgery complications					
	TOTAL	MS I	MS II	MS III	MS IV
Recurrent cholangitis	1 (0.6%)				1
Liver abscess	1 (0.6%)				1
Wound infection	2 (1.3%)		1	1	
Late benign stricture	4 (2.6%)		2	2	
Total	8 (5.3%)				

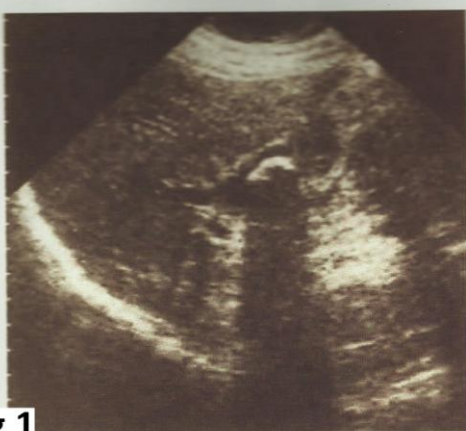

Fig 1

Longitudinal scan during real-time ultrasonography at the level of the porta hepatis shows a dilated common hepatic duct. Just inferiorly to it is a large impacted gallstone with acoustic shadowing in a patient with confirmed Mirizzi syndrome.

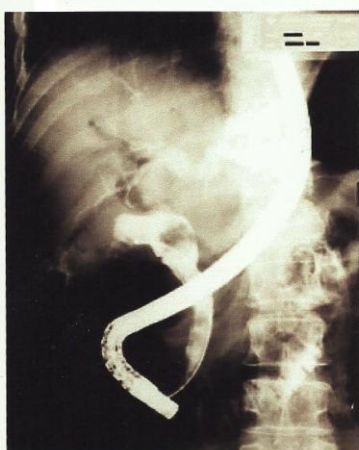

Fig 2

Preoperative ERCP demonstrates compression of the common hepatic duct by a large 2-cm stone in the cystic duct with dilation of proximal bile ducts characteristic of Mirizzi's syndrome.

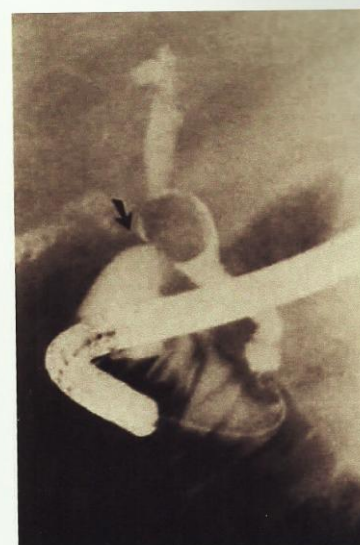


Fig. 3: ERCP showing calculus eroded into the common duct.

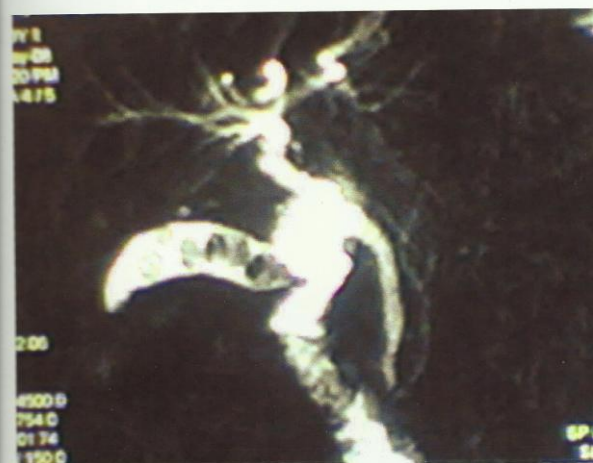

Fig. 4: MRCP showing type-I Mirizzi defect.

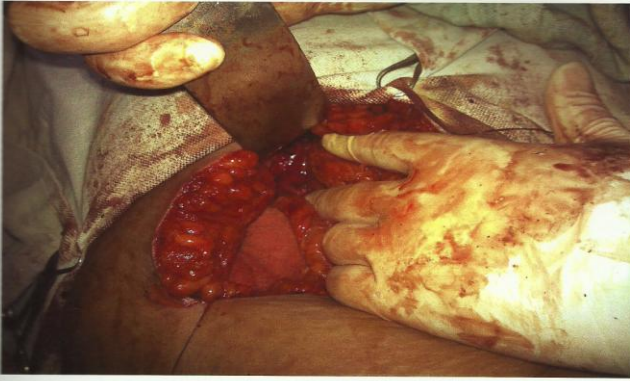

Fig. 5: Intraoperative picture of type-III Mirizzi's syndrome.

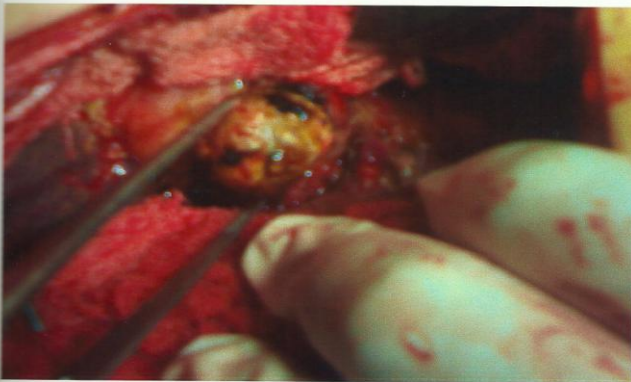

Fig. 6: Stone being removed through the cholecystocholedochal fistula in the same patient after removal of shrunken gall bladder.

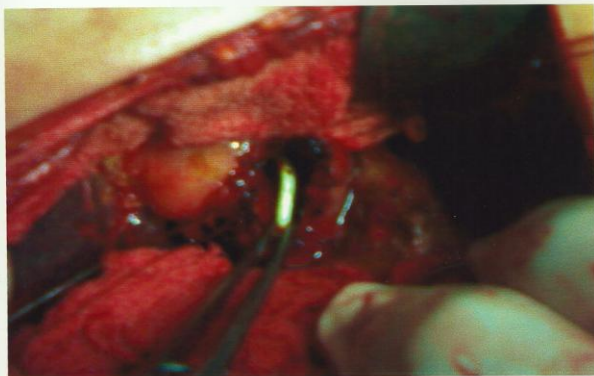


Fig. 7: Intraoperative image showing the fistula.

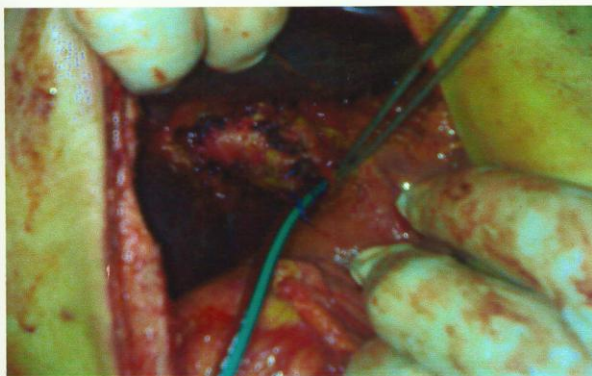


Fig. 8: Choledochoplasty of type-III Mirizzi defect performed by using 10mm gall bladder cuff.

Discussion

During ten years period, a total of 6286 cholecystectomies were performed for the patients with gall stone disease and out of these 150 cases (2.3%) of MS were seen. The incidence correlates well with the reported incidence in the literature [10-13]. There is a wide variation in the reported incidence of various types of MS. According to Csendes et al [5] classification, the frequency of type I, II, III & IV lesion in 219 patients reported by them were respectively 10.5%, 41.1%, 44.3% and 4.1%. Among our 150 patients, 124 (82.6%) patients were type-I, 20 (13.3%) were type – II, 5 (3.3%) as type – III, & 1 (0.6%) patient was classified as type – IV. Whereas no definite reason had been offered to explain wide variability in the incidence of various types of MS, reported by different authors, the possible explanation for very high number of type-I lesion in our series is possibly because of high incidence of cholelithiasis in our state [14] and thereby much number of cholecystectomies performed. The incidence of gall bladder stone disease is high in Kashmir. The patients have recurrent attacks of acute cholecystitis due to high fat diet in the cold geographical region of Kashmir. The patients usually present late when jaundice gets noticed. The mean age of our patients was 47.2 years with a range of 14 – 80 years. Majority (> 2/3rd) of patients were in age group of 21 – 60 years and remaining 1/3rd beyond 60 years of age. Our results in terms of age are in agreement with Csendes et al [5] and Mithani et al [15].

In our series of 150 patients, 110 (73.3%) were females, thereby male to female ratio was 1:3 approximately. Our results concur with largest series of 219 patients reported by Csendes et al [5]. Most of the patients in our series presented with pain right hypochondrium suggestive of biliary pain in the patients. Twenty six percent were jaundiced at the time of presentation and 16% had associated cholangitis. Our series results were in agreement with Al-Akeely et al [13] and Ibraullah et al [16]. Liver function tests were deranged in all the patients. Serum bilirubin and ALP are useful

biochemical markers for diagnosing biliary obstruction regardless of etiology. In the setting of USG-finding suggestive of MS, the elevated bilirubin and ALP would further raise the suspicion of MS. In our study bilirubin was elevated in 92 (61.3%) and ALP was elevated in 87 (58%) patients. Majority of our patients with USG evidence of biliary obstruction with concomitant dilatation above the site of obstruction had elevated serum bilirubin and ALP levels. Similar observation was made by other authors, Al-Akeely et al^[13] and Ibraullah et al^[16]. The sensitivity of USG diagnosis increases if the obstruction level of cystic duct will induce intrahepatic duct dilatation, above it. MS was suspected in 61.3% of our patients by USG. In a study by Al-Akeely et al^[13], the correct diagnosis at USG was reported in 82% of cases. Chan CY et al^[2] reported USG sensitivity of 23 – 46% in his series.

In our study ERCP was useful for palliation in patients with pyogenic cholangitis. A total of 59 patients required ERCP, in view of cholangitis (n = 14) and progressive cholestasis (n = 45). After stabilization of cholangitis and serum bilirubin below 10 mg/dl the patients underwent surgery. The mean duration of hospital stay after ERCP was 3 days (range 2-5 days). Although ERCP suggested diagnosis of MS but the definitive type was not made on ERCP (Fig 2, Fig 3). In fact from our experience open surgical procedure is required for correct characterization of MS. The stone extraction was successful in 39 of 59 patients (66.1% of patients who underwent ERCP) and ENBD catheter insertion and biliary stenting was performed in 20 (33.8% of patients who underwent ERCP) patients. In other words, ERCP was performed in 59/150 patients (39.3%) and out of these 59 patients, ERCP was successful in clearing bile ducts in 39 patients (26% of patients who were diagnosed having MS). CBD was not cleared in 20 patients (endoscopic failures) who required endo nasal biliary drainage (ENBD) or stenting (Table 4b). Subsequently the patients were subjected to open cholecystectomy. Our

results are in agreement with other reports series on use of ERCP in MS by England et al^[17]. ERCP is safe and successful as only 4/59 patients (6.8%) developed complications. Our institute lies in a third world country, where modern modes of diagnosis like MRCP have been in use for only few years. In regard to our institute, MRCP has been introduced since 2006 only. This is the reason why MRCP has not been used in many patients (Fig 4). Also, as a matter of practice, ERCP is used in patients who have therapeutic indication on the basis of clinical presentation, laboratory and USG data.

Surgery is the ultimate treatment modality for MS. In our series open cholecystectomy was the most common surgical procedure done in 111 out of 124 patients of type-I MS, as it was safely done. Partial cholecystectomy was performed in 13 patients of type-I due to unfavorable anatomy in Calot's triangle. In type-II patients, eleven patients underwent partial cholecystectomy as otherwise a future stricture formation was anticipated in them at the junction, seven patients needed choledochoplasty and two were treated with primary repair of cholecysto-choledochal fistula without compromising the lumen of common hepatic or bile duct. All 5 patients of type- III MS underwent partial cholecystectomy will choledochoplasty using 10 mm GB-cuff with T-Tube drainage. This novel technique avoided a formal bilioenteric anastomosis and its complications in this set of patients without any notable complications on their follow up. According to Baer & Colleagues using such flap from diseased GB is prone to failure^[18]. They therefore recommend choledocho-duodenostomy and achieved satisfactory results. In our study, all five patients of type – III MS were managed successfully using a GB – flap and distally placed T-Tube for 6 – 8 weeks (Fig 5, 6, 7, 8). We are in agreement with Johnson and Colleagues that T-Tube decompression remains integral to the management of type –III MS^[19]. The management of M S type – IV is almost established with bilioenteric anastomosis as standard treatment

[2,5,18]. The only patient in our series with type – IV MS underwent cholecystectomy with Roux-en-y-hepatico jejunostomy. These surgical interventions were in accord with the accepted published procedures for Mirizzi syndrome [5,15,19,20,21]. Postoperative complications and mortality were within the expected rates [13,21,22,23].

There was no in-hospital mortality.

Laparoscopic cholecystectomy has now become the gold standard in the treatment of gall stone. Its success usually depends (among other factors) on the ability to safely grasp and laterally retract the GB for easy dissection around the cystic duct in the region of Calot's triangle. These maneuvers are not only difficult but may be impossible to perform in MS. For these reasons MS has been considered by various authors to be a contraindication for laparoscopic cholecystectomy [24,25]. However, some authors have reported success with the laparoscopic technique in type I MS [26]. None of our patients underwent laparoscopic cholecystectomy anticipating a high rate of conversion as well as complications during this period with this subset of patients of GB stone disease.

Conclusion

The incidence of MS in our state (2.3%) correlates well with literature. Type-I MS was seen in 82.6% possible due to where high incidence of GB-stone disease. Pre-operative diagnosis is very important to prevent severe injuries at time and surgery. Laboratory parameters, USG followed by ERCP are reasonably helpful modalities for disease suspicion. ERCP is of help for palliation and surgery is the definite procedure for the syndrome.

Conflicting Interest: Nil

Acknowledgement: Nil

References

1. Waisberg J, Corona A, de Abreu IW, et al. Benign obstruction of common hepatic duct (Mirizzi syndrome): Diagnosis and

operative management. *Arq Gastroenterol* 2005 ; 42(1) : 13 – 18.

2. Chan CY, Liao KH, Ho CK, et al. Mirizzi syndrome: A diagnostic and operative challenge. *Surgeon* 2003; 1(5): 273 – 278.
3. Yeh CN, Jan YY, Chen MF. Laparoscopic treatment for Mirizzi syndrome. *Surg Endosc* 2003;17(10) : 1573 – 1578.
4. Mc Sherry CK, Ferstenberg H, Virshup M. The Mirizzi syndrome. Suggested classification and surgical therapy. *Surg Gastroenterol* 1982; 1: 219 – 225.
5. Csendes A, Carlos Diaz JC, Burdiles P, et al; Mirizzi syndrome and cholecystobiliary fistula. A unifying classification. *Br. J Surg* 1989 : 76(11); 1139 – 1143.
6. Nagakawa T, Ohta T, Kayahara M et al. A new classification of Mirizzi syndrome from diagnostic and therapeutic view points. *Hepatogastroenterology* 1997 ; 44(13) : 63 – 67.
7. Baer HU, Mathews JB, Schweizer WP, et al. Management of the Mirizzi syndrome and surgical implications of cholecystocholedochal fistula. *Br J Surg* 1990 ; 77(7) : 743 – 745.
8. Corlette MB, Bismuth H. Bilobiliary fistula. A trap in the surgery of cholelithiasis. *Arch Surg* 1975; 110(10) : 377 – 383.
9. Yip AW, Chow WC, Chan J, et al. Mirizzi syndrome with cholecystocholedochal fistula: Pre-operative diagnosis and management. *Surgery* 1992 : 111(3); 335 – 338.
10. Bower TC, Nagorney DM. Mirizzi syndrome. *HPB Surg.* 1988 ; 1(1) : 67 – 74.
11. Hassler H, Becker CD. Mirizzi syndrome : anamnesis, diagnosis and therapy based on 5 cases. *Chirurg.*1984;55(12):817– 821.
12. Hunt DR. Another Paper on Mirizzi syndrome. *ANZ J Surg.* 2004; 74(10):826.
13. Al-Akeely MH, Alam MK, Bismar HA, et al. Mirizzi syndrome : Ten years experience from a teaching hospital in

- Riyadh. World J Surg 2005; 29(12) : 1687 – 1692.
14. Mahajan R, Khuroo S, Zargar SA, et al. Prevalence of biliary tract disease in India. Gut 1989 ; 30(2) : 201 – 205.
 15. Mithani R, Schwesinger WH, Bingener J, et al. The Mirizzi syndrome. Multidisciplinary management promotes optimal outcome. J Gastrointest Surg 2008 12(6) : 1022 – 1028.
 16. Ibraullah M, Saxena R, Sikora SS, et al. Mirizzi syndrome identification and management strategy. Aust N Z J. Surg 1993; 63(10) : 802 – 806.
 17. England RE, Martin DF. Endoscopic management of Mirizzi syndrome. Gut 1997 ; 40(2) : 272 – 276.
 18. Baer HU, Matthews JB, Schweizer WP, et al. Management of Mirizzi syndrome and the surgical implications of cholecystocholedochol fistula. Br J Surg. 1990 ; 77(7) : 743 – 745.
 19. Johnson LW, Sehon JK, Lee WC, et al. Mirizzi syndrome: experience from a multi institutional review. Am Surg. 2001 ; 61(1) : 11 – 14.
 20. Schafer M, Schneiter R, Krahenbuhl L. Incidence and management of Mirizzi syndrome during laparoscopic cholecystectomy. Surg Endosc 2003; 17:1186–1190.
 21. Cortes MR, Vasquez AG. Frequency of the Mirizzi syndrome in a teaching hospital. Cir Gen 2003; 25:334–337.
 22. Chatzoulis G, Kaltsas A, Danilidis L, et al. Mirizzi syndrome type IV associated with cholecystocolic fistula: a very rare condition: report of a case. BMC Surg 2007; 7:6.
 23. Karademir S, Astarcioglu H, Sokmen S, et al. Mirizzi's syndrome: diagnostic and surgical considerations. J Hepatobiliary Pancreat Surg 2000; 7:72–77.
 24. Rust KR, Clancy TV, Warren G, et al. Mirizzi syndrome a contraindication to coelioscopic cholecystectomy. J Laparosc Surg 1991 ; 1(3) : 133 – 137.
 25. Posta CG. Un expected Mirizzi anatomy : a major hazard to the common bile duct during laparoscopic cholecystectomy. Surg Laparosc Endosc 1995 ; 5(5) : 412 – 414.
 26. Binnie NR, Nixon SJ, Palmer KR, Mirizzi syndrome managed by endoscopic stenting and laparoscopic cholecystectomy. Br J Surg 1992 ; 79(7) : 647.
 27. Rohatgi A, Singh KK. Mirizzi syndrome: laparoscopic management by subtotal cholecystectomy. Surg Endosc 2006; 20:1477–1481.