



### Original Research Paper

## Olecranon Fossa in Humeri of North Indian Population of Jammu- A Morphometric Study

Authors

**Berjina Farooq Naqshi<sup>1</sup>, Adil Bashir Shah<sup>2</sup>, Sangeeta Gupta<sup>3</sup>**

<sup>1</sup>Demonstrator, Department of Anatomy, Government Medical College, Srinagar, Kashmir, India

<sup>2</sup>Registrar, Department of Orthopaedics, Government Medical College, Srinagar, Kashmir, India

<sup>3</sup>Professor, Department of Anatomy, Government Medical College, Jammu, India

Corresponding Author

**Berjina Farooq Naqshi**

Email: [berjinaadil@gmail.com](mailto:berjinaadil@gmail.com)

### Abstract

**Introduction:** Fractures of olecranon can occur as a result of hyperextension trauma to elbow joint. Various implants are available for diverse fractures in distal humerus and these are contoured for anatomy of this region. Morphometry of olecranon is important since their fractures occur in 10% of upper extremity fractures.

**Material and Method:** Present study was conducted on 100 dry humeri from Department of Anatomy, GMC Jammu. Morphometry of distal humerus was studied i.e. distance between proximal and distal point of olecranon fossa, distance between distal part of olecranon fossa and trochlea, and distance between proximal edge of olecranon fossa and trochlea.

**Result:** Distance between proximal and distal point of olecranon fossa was  $1.80 \pm 0.17$ cm, distance between distal part of olecranon fossa and trochlea was  $1.42 \pm 0.16$ cm, and distance between proximal edge of olecranon fossa and trochlea was  $3.22 \pm 0.27$ cm.

**Conclusion:** Morphometric analysis of distal humerus is used in endoprosthetic construction, reconstructive operations, etc. Morphometric measurements of olecranon fossa are important since olecranon fractures occur in 10% of all upper extremity lesions.

**Keywords:** Olecranon fossa, morphometry, distal humerus.

### Introduction

Examination of the upper and lower limb asymmetries can be useful to medical anthropologists, archaeologists, and for medicolegal studies<sup>(1)</sup>. Fractures of the distal segments of humerus involving olecranon can occur as a result of hyperextension trauma to the elbow joint. Various implants are available for the

diverse fracture patterns observed in the distal humerus and these are contoured specifically for the anatomy of this region<sup>(2)</sup>. Complex anatomy of the elbow, small size of fracture fragments and limited amount of subchondral bone, combine to make improvements in the outcome of operative management of intra articular fractures even for skilled surgeons<sup>(3)</sup>. Rogers TL (1999) introduced a

new method of determining the sex of skeletal remains based on four morphological features of the posterior, distal humerus. Morphometry of the distal end of humerus has a significant role in the determination of sex<sup>(4)</sup>. Morphometry of distal end of humerus is important since olecranon fractures occur in 10% of all upper extremity lesions. The lesion might be the result of indirect or direct trauma, especially forced hyperextension of the elbow joint<sup>(5)</sup>.

### Material and Method

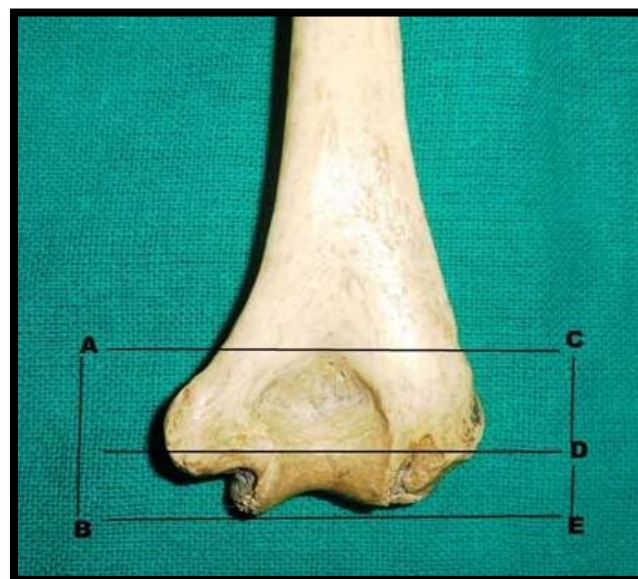
The present study was conducted on 100 dry humeri of unknown age and sex, which were obtained from Department of Anatomy, GMC Jammu. Prior permission was taken from Head of Department, Anatomy, GMC, Jammu. The morphometry of distal humerus was studied in detail. Humerus bones were dry and complete in all respects so as to give correct morphometry. Parameters measured were the distance between proximal and distal point of olecranon fossa, the distance between distal part of olecranon fossa and trochlea, the distance between proximal edge of olecranon fossa and trochlea (Table 1) (Fig 1). Most of the measurements of humerus were done using Vernier Calliper and measuring tape. Mean and standard deviation was determined.

### Results

**Table 1:** Showing measurements related to olecranon fossa

S. No.	Parameters (in cms)	Mean±SD
1	distance between proximal and distal point of olecranon fossa	1.80±0.17
2	distance between distal part of olecranon fossa and trochlea	1.42±0.16
3	distance between proximal edge of olecranon fossa and trochlea	3.22±0.27

**Fig 1:** Distal End of Humerus Illustrated Measurements Taken



AB– Distance Between Proximal Edge of Olecranon Fossa and Trochlea

CD– Distance Between Proximal and Distal Point of Olecranon Fossa

DE– Distance between Distal Part of Olecranon Fossa and Trochlea

### Discussion

The distal humeral end articulates with the bones of the forearm and fractures involving it may pose several reconstructive problems like damage to the nerve and blood vessels. These fractures gain special attention for orthopaedic surgeons and to overcome these problems, they ought to know the morphometry of distal humerus<sup>(2)</sup>. Morphometry of distal end of the humerus is of significance for testimation of sex even in a fragmentary state<sup>(6)</sup>. It is helpful in archaeological fields and is of help to orthopaedicians for treatment of distal humerus fractures, for their reconstruction in case of extensive damage<sup>(7)</sup>. Morphometry of trochlea is very important for prosthetic sizing and designing of the distal end of humerus. The data so created could be used in endoprosthesis construction and in the clinical orthopaedic trauma practice-prosthetic replacement, reconstructive operations, bone plasty etc in the area of the elbow joint<sup>(8)</sup>. Morphology of the distal end of the humerus is important because it provides the fundamental

information for surgical procedures of orthopaedic surgeons and anthropologists<sup>(9)</sup>.

The mean distance between proximal and distal point of olecranon fossa was found to be

1.80±0.17 cm, with a mean of 1.77±0.15 cm on right side and 1.82±0.19 cm as mean on left side which was in consonance with study of Premchand et al.,<sup>(10)</sup> (2014).

**Table 2:** Showing comparison of distance between proximal and distal point of olecranon fossa

Author	Race	Right		Left	
		Mean(cm)	SD	Mean(cm)	SD
Premchand et al <sup>(10)</sup>	South Indians	1.76	0.16	1.82	0.15
Present study	North Indians	1.77	0.15	1.82	0.19

Complex anatomy of elbow, small size of the fracture fragments and limited amount of subchondral bone, which is often osteopenic, combine to make, very difficult, the operative

management of intra articular fractures even for skilled surgeons. This problem can be overcome if morphometry of distal humerus is worked out<sup>(11)</sup>

**Table 3:** Showing comparison of distance between distal part of olecranon fossa and trochlea

Author	Race	Right		Left	
		Mean(cm)	SD	Mean(cm)	SD
Premchand et al <sup>(10)</sup>	South Indians	1.4	0.13	1.44	0.14
Present study	North Indians	1.41	0.15	1.43	0.16

The mean distance between distal part of olecranon fossa and trochlea was found to be 1.42±0.16 cm, with a mean of 1.41±0.15 cm, on

right side and 1.43±0.16 cm as mean, on left side. Results of Premchand et al., (2014) were in consonance with our study.

**Table 4:** Showing comparison of distance between proximal edge of olecranon fossa and trochlea

Author	Race	Right		Left	
		Mean(cm)	SD	Mean(cm)	SD
Premchand et al <sup>(10)</sup>	South Indians	3.16	0.23	3.27	0.25
Present study	North Indians	3.19	0.24	3.26	0.30

The mean distance between proximal edge of olecranon fossa and trochlea was found to be 3.22±0.27 cm, with mean of 3.19±0.24 cm, on right side and 3.26±0.30 cm, on left side. Results of Premchand et al., (2014) were in consonance with our study.

morphometric knowledge is important since olecranon fractures occur in 10% of all upper extremity lesions.

### Conclusion

The morphometric analysis of distal end of humerus is important to maintain normal elbow joint functioning. The data is used in endoprosthetic construction, reconstructive operations, bone plasty etc in the area of elbow joint. The various morphometric measurements related to olecranon fossa can get distorted due to fractures in the area of the olecranon fossa. Its

### References

1. Lokanadham S, Khaleel N and Raj PA. Morphometric analysis of Humerus bone in Indian population. *Sch.J.App.Med.Sci.*, 2013; 1(4): 288-90.
2. Somesh MS, Prabhu LV, Shilpa K, Pai MM, Krishnamurthy A and Murlimanju BV. Morphometric study of the Humerus segments in Indian population. *Int. J. Morphol.* 2011; 29(4): 1174-80.
3. Ring D and Jupiter JB. Complete fractures of the distal humerus and their

- complications. *J Shoulder Elbow Surg* 1999; 44(1): 57-60.
4. Rogers TL. Visual method of determining the sex of skeletal remains using the distal humerus. *J Forensic Sci.* 1999; 44(1): 57-60.
  5. Rommens PM, Kuchle R, Schneider RU and Reuter M. Olecranon fractures in adults: factors influencing outcome injury. *Injury.* 2004; 35(11): 1149-57.
  6. Hegazy AA. Radiographic morphometric study of the normal distal humerus in adult Egyptians. *Int J Adv Res* 2013; 1(9): 155-61.
  7. Lakshmi Kantha BM and Kulkarni R. Estimation of total length of humerus from its fragments in south Indian Population. *Int J Anat Res* 2014; 2(1): 213-20.
  8. Katsarov A and Yordanov Y. Morphology of the distal humerus in human and its clinical significance. *J Biomed Clin Res Suppl.* 2009; 2(1): 144-7.
  9. Desai SD and Shaik HS. A morphometric study of Humerus segments. *J. Pharm. Sci. Res.* 2012; 4(10): 1943-5.
  10. Premchand SA and Manjappa T. Reconstruction of humeral length from measurements of its segments in South Indian population. *Int J Sci Res.* 2014; 3(8): 1956-9.
  11. Ring D and Jupiter JB. Complete fractures of the distal humerus and their complications. *J Shoulder Elbow Surg.* 1999; 8: 85-97.