



Case Report

T Lymphoblastic Lymphomas: Two Unsuspected Cases in Head and Neck Region

Authors

Pooja Prapanna, Neelam Wadhwa, Preeti Diwaker, Nadeem Tanveer, Vinod K. Arora, Anupama Tandon

Introduction

Extra-nodal Non Hodgkin lymphomas with involvement of soft tissues and bone destruction as a primary event are very rare. Few reported cases have been of B cell origin the most common culprit being Burkitt lymphoma. (salamao) Soft tissue involvement in NHL is often limited to immunocompromised individuals.^{1,2} We report two rare cases of T-cell lymphoma involving head and neck region soft tissues in pediatric patients with no known immunological deficit.

Case Reports

A 4 year old male presented with cheek swelling to FNA clinic. CT scan showed left pterygo palatine fossa mass with intraorbital and intracranial extension (Fig.1). Fine needle aspirate smears revealed monomorphic intermediate size lymphoid cells with scant cytoplasm, dense chromatin and inconspicuous nucleoli, few cells showed nuclear clefts (Fig 2). Special stains were performed for **Acid phosphatase**, which showed fine cytoplasmic granularity (Fig 3a), further immunocytochemistry confirmed T lineage (**CD45+ , CD3+**) (Fig3b, 4). In the light of morphological evaluation and immunochemical staining a diagnosis of T cell lymphoma was given.

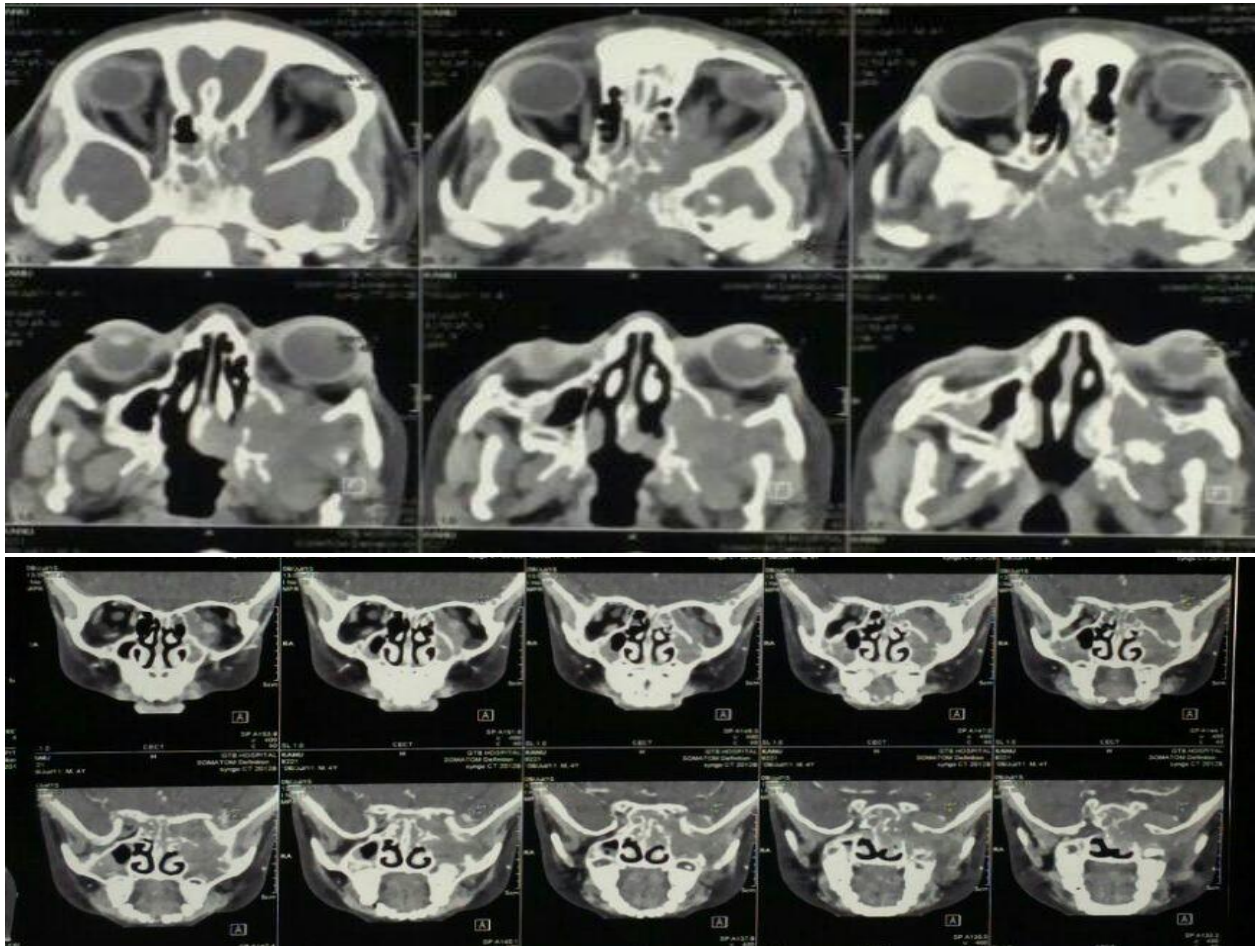
Hematological workup showed marrow replacement by tumor cells with only few atypical cells in peripheral blood.

Another case is of a 5 year old male who presented with exophytic mass involving left upper eye lid, diffuse swelling of right thigh and lump near right ankle clinically diagnosed as retinoblastoma with osteosarcoma (Fig. 5)

CT scan (Fig 6) showed large soft tissue mass involving distal right thigh causing marked erosion of distal metaphysis and diaphysis of femur. Multiple calcific foci were also seen within the mass.

Fine needle aspirate smears revealed small to intermediate sized lymphoid cells with scant-moderate cytoplasm, condensed chromatin and inconspicuous nucleoli. Cytoplasmic vacuoles were seen in few cells. Tumor showed high mitotic activity (Fig. 7a, 7b). H&E staining was done on cell block (Fig. 8). Immunohistochemistry revealed tumor cells to be positive for LCA and CD3, thus confirming T-cell lineage. (Figs 9a, 9b)

Both the patients received immediate treatment intervention and are right now in remission phases of their disease.



Case 1 : Cheek Swelling Fig 1) Axial and coronal sections of orbit showing soft tissue mass in left pterygopalatine fossa with extension in middle cranial fossa and left orbital apex Left maxillary sinus and nasal cavity also involved

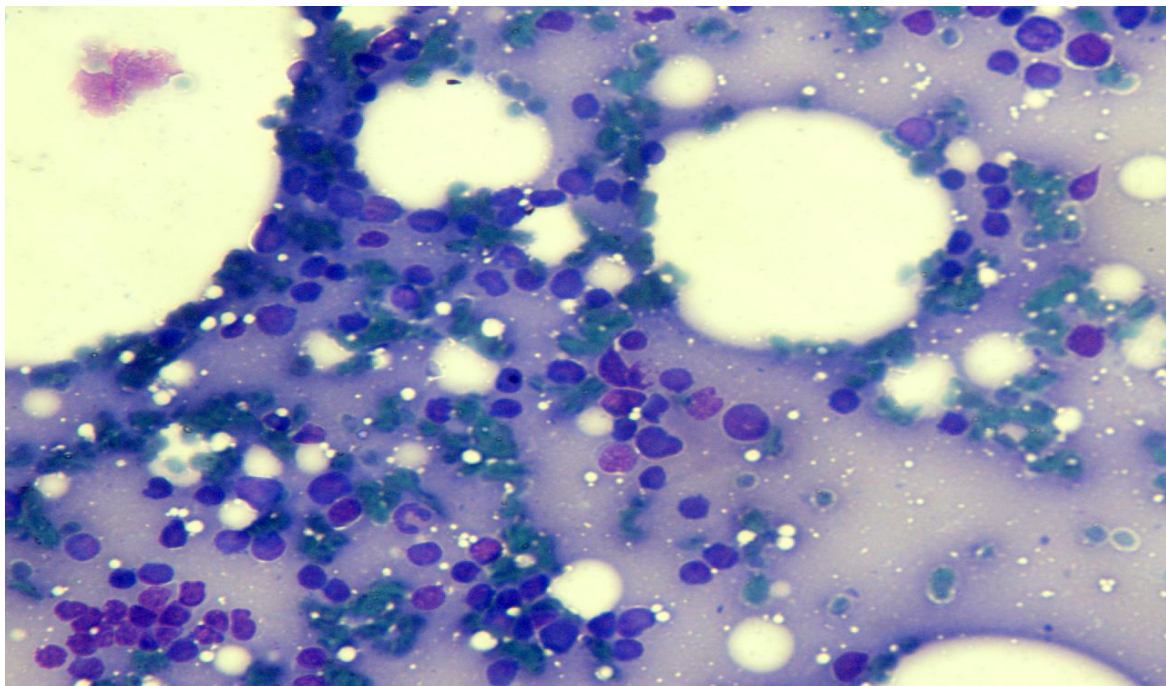


Fig 2) MGG stained smears showing tumor cells singly scattered monomorphic intermediate size lymphoid cells with scant cytoplasm, dense chromatin and inconspicuous nucleoli, few cells showed nuclear clefts

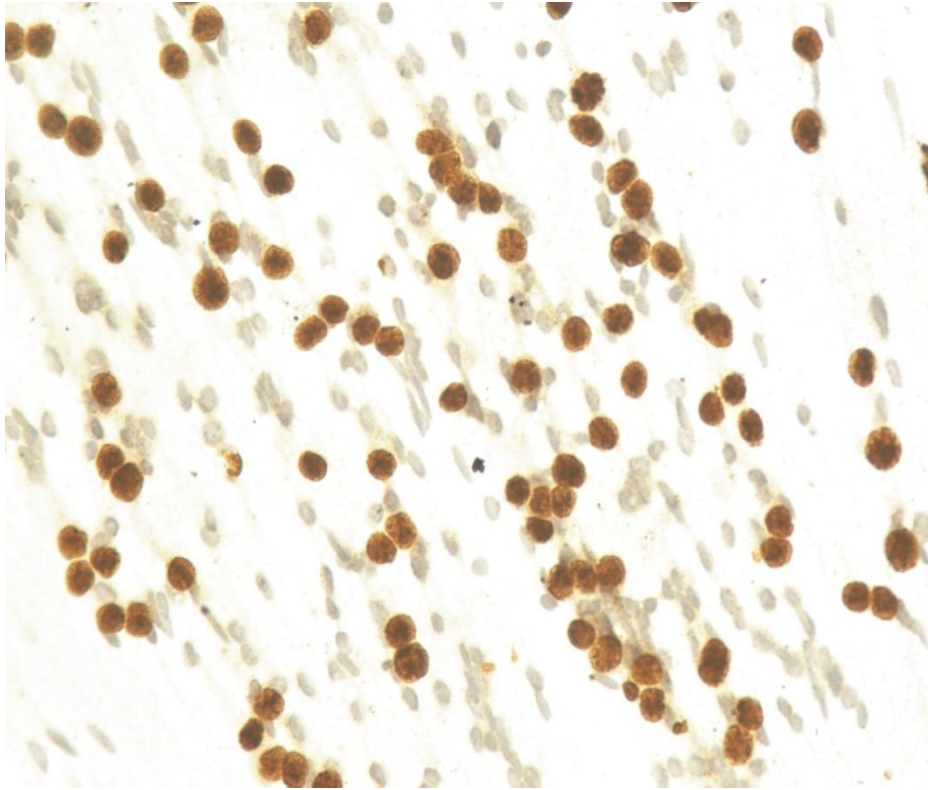


Fig 3 a) Photomicrograph showing tumor cells positive for LCA

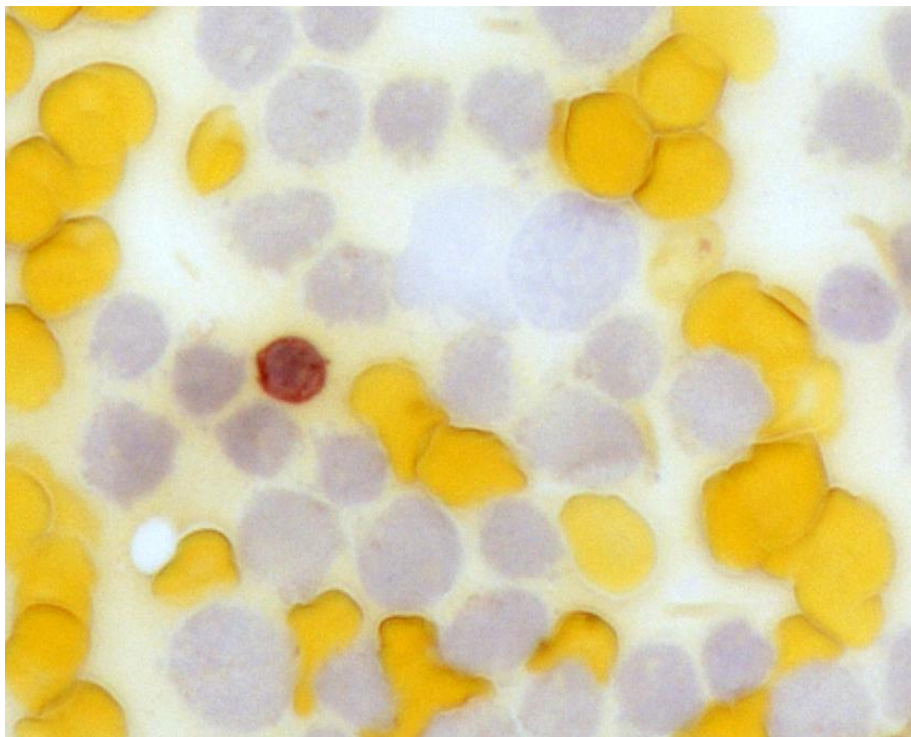


Fig 3 b) Photomicrograph showing Acid phosphatase positivity

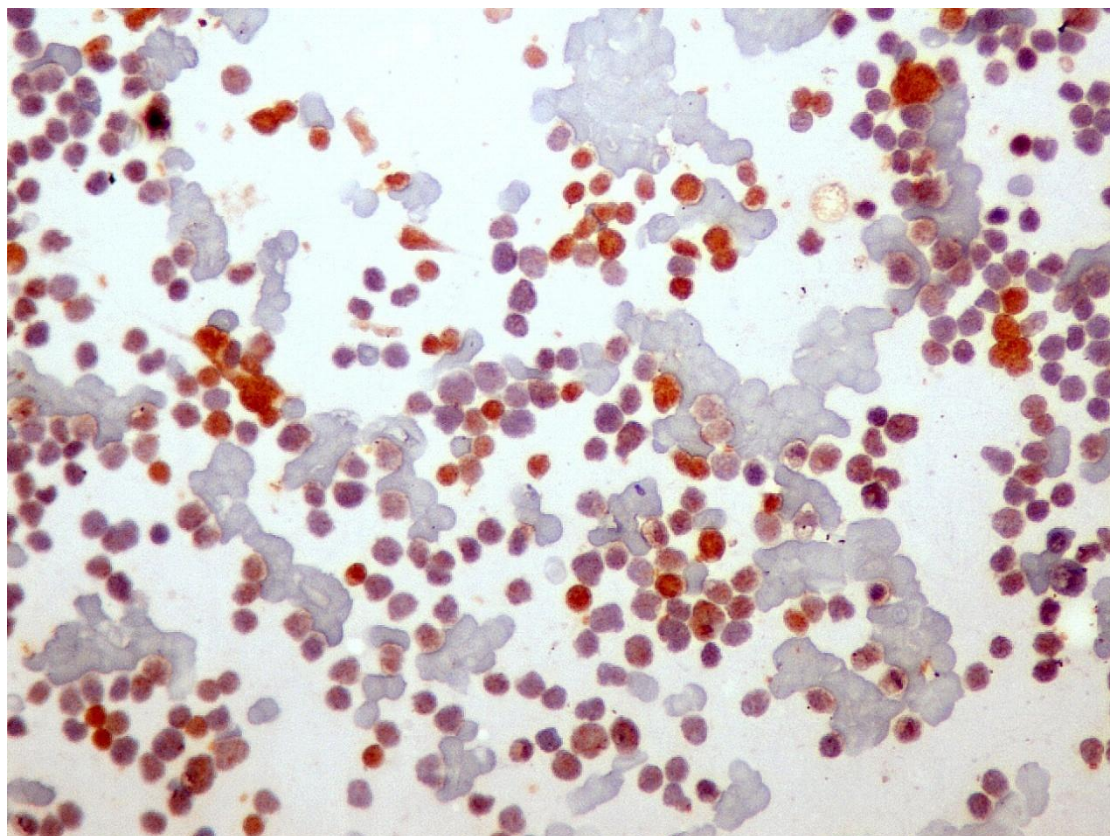


Fig 4 Bone marrow aspirate smears showing diffuse replacement of marrow by tumor cells with CD3 positivity

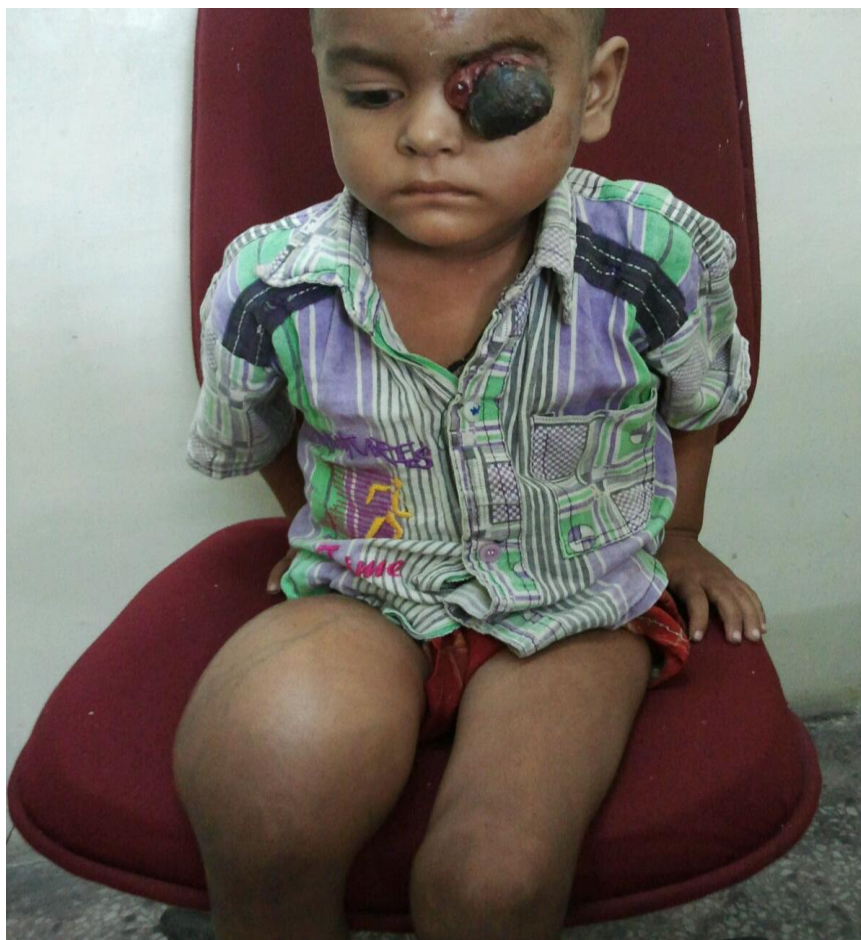

Fig 5: Case 2: Patient with exophytic mass involving left upper eye lid and diffuse swelling of right thigh

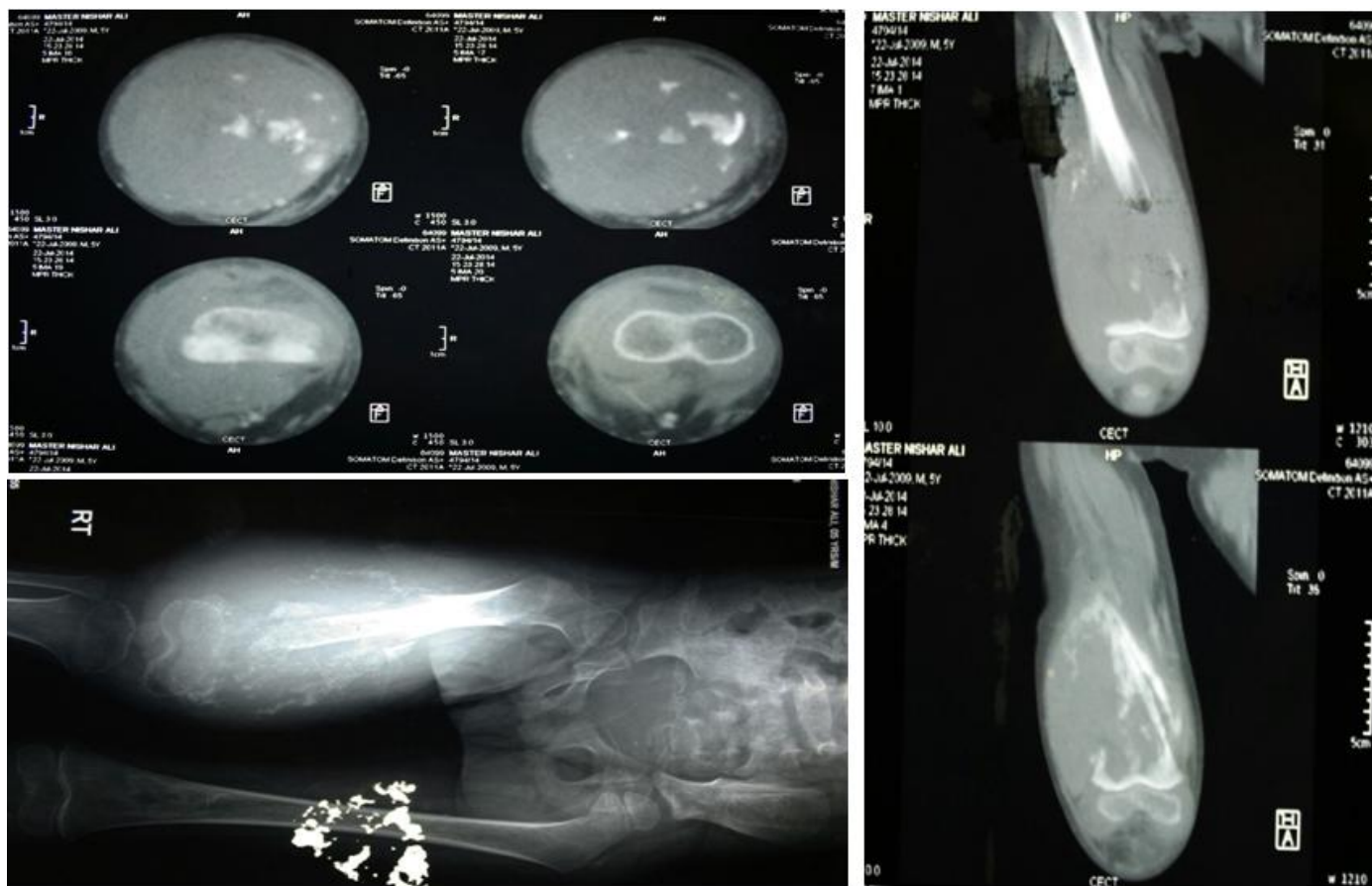


Fig 6 Coronal and axial CT sections of distal thigh showing large soft tissue mass with calcific foci involving muscles, marked erosion of shaft of femur with thick periosteal reaction

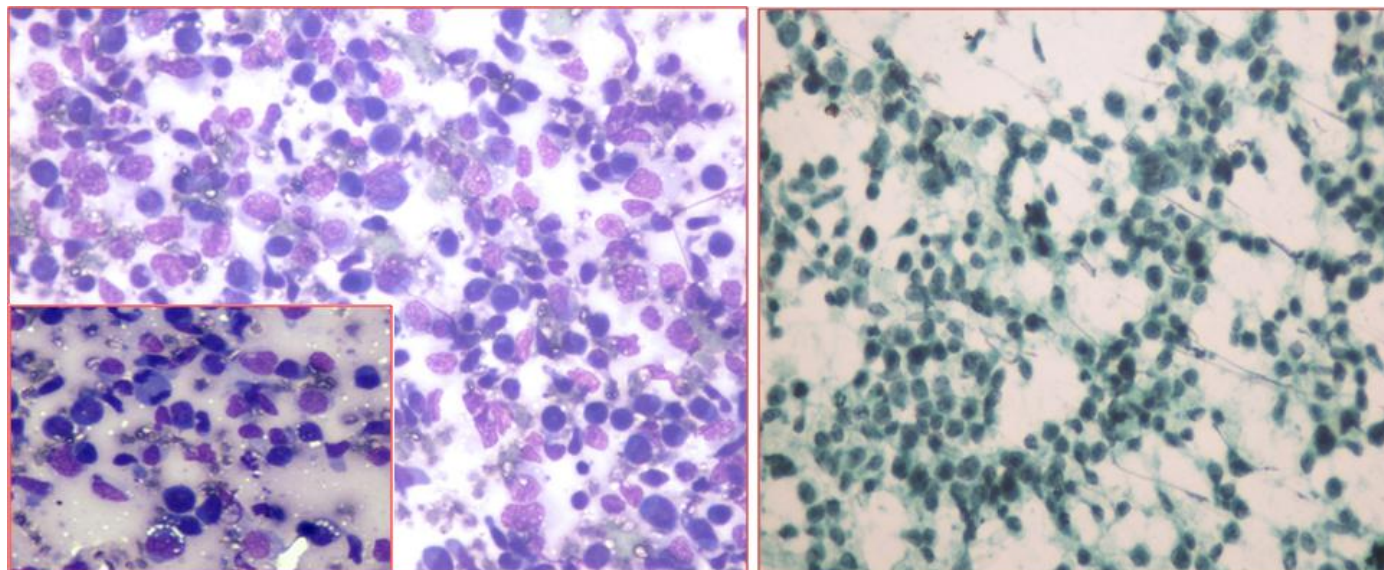


Fig 7: MGG and PAP stained smears showing lymphoid cells with scant-moderate cytoplasm, condensed chromatin and inconspicuous nucleoli.
INSET: showing cells with cytoplasmic vacuolation and mitotic activity

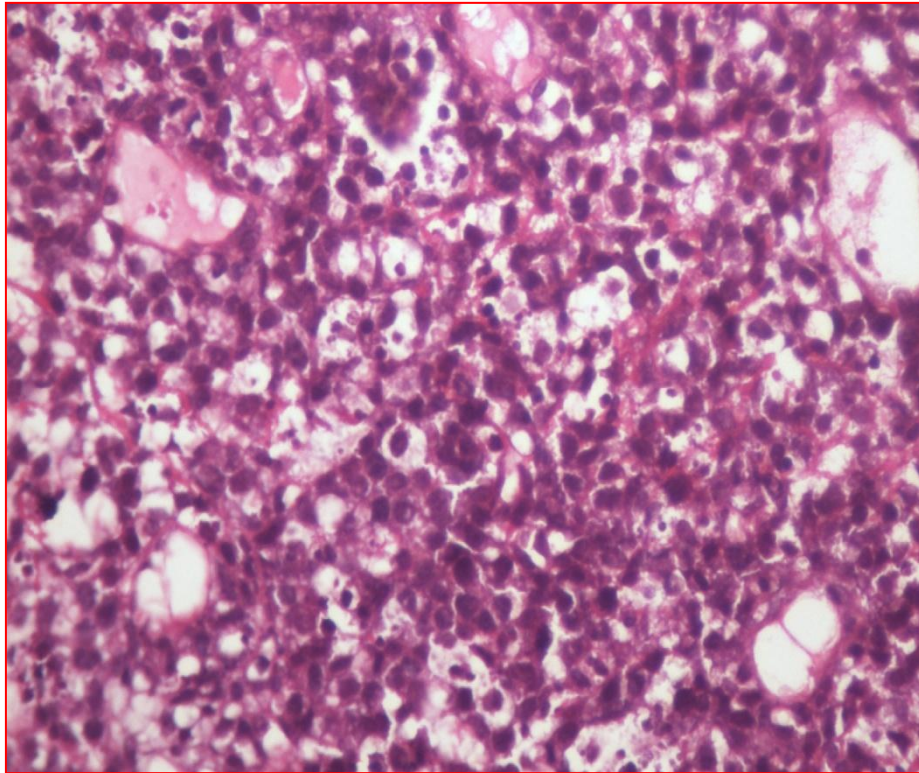


Fig 8: H& E Staining on cell block of the tissue showing tumor cells

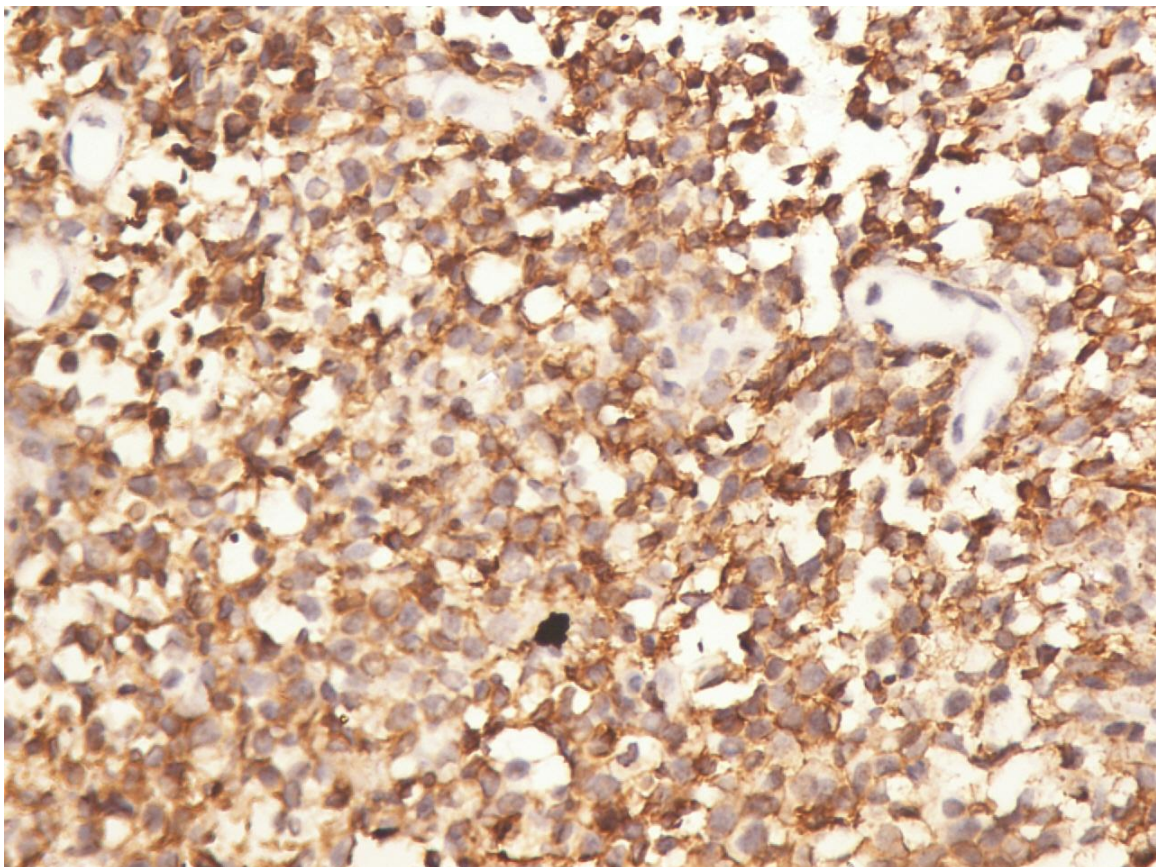


Fig 9a Photomicrograph showing tumor cells positive for LCA

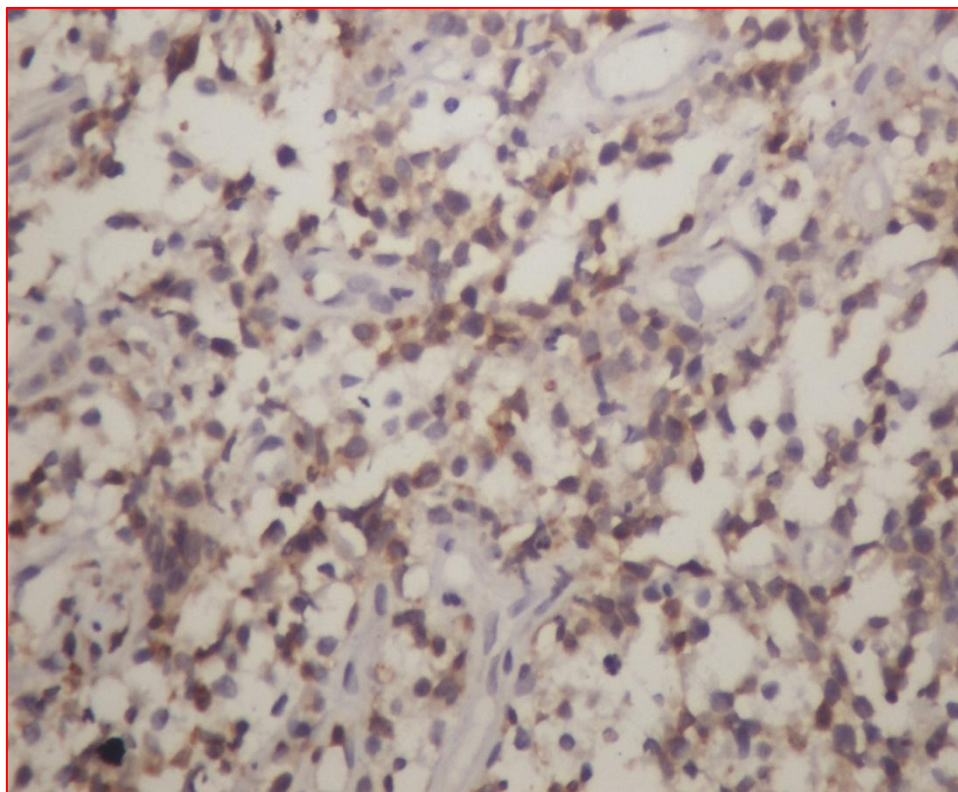


Fig 9 b: Immunohistochemical staining for CD3; Tumors cells showing CD3 positivity

Discussion

Pediatric lymphomas are the third most common group of malignancies in children and adolescents accounting for about 12% of all newly diagnosed cases in this age group. In contrast to adult lymphoma, pediatric lymphomas are of high grade and tend to have diffuse and extra nodal involvement. Extranodal NHL in children commonly presents with mediastinal mass (26%), abdominal lump (29%), and head and neck mass (29%). Three main histological subtypes of NHL in children are lymphoblastic lymphoma, small cell lymphoma (Burkitt and non Burkitt) and large cell lymphoma (B or T phenotype).

Extranodal NHL involving soft tissue and bone are most commonly large cell lymphomas with B cell phenotype. T-cell NHL involving soft tissue with osseous destruction have been rarely described in literature. Salamao R et al reviewed 19 lymphoma cases presented as soft tissue mass. Histological and immunophenotypic studies revealed only one case of T cell lymphoma and rest were of B cell phenotype.

Only few cases of primary soft tissue T cell NHL involving facial bones and extremities have been reported in adults.^{2, 7-9}

We have delineated clinical, radiological and pathological features of two rare cases of T cell NHL in pediatric age group with soft tissue involvement in Head and neck region and extremity. No such cases with simultaneous involvement of head and neck and extremities have been reported in pediatric age group till date. T-cell NHL should be considered while investigating rapidly progressive head and neck mass in pediatric setting. Since T-cell lymphomas are associated with an aggressive course, early diagnosis and prompt treatment is the key for success.

References

1. Salamao DR, Nascimento AG, Lloyd RV et al Lymphoma in soft tissue: a clinicopathologic study of 19 cases. *Hum Pathol.* 1996;27:253-7.
2. Rana K, Narula V, Bhargava E, Shankar R, Mahajan N T-Cell Lymphoma of the

- Oral Cavity: Case Report J Clin Diagn Res. 2015; 9: MD03-4.
3. Corti M, Villafane M, Bismans A et al. Soft-tissue masses as presentation of non-Hodgkin's lymphoma in AIDS patients. An Bras Dermatol. 2013; 88: 631-4.
 4. Bakshi S. Childhood Non Hodgkin Lymphoma: clinical profile. Ind J Med Pediatr Oncol 2003; 24: 27-9.
 5. Derenzini E, Casadei B, Pellegrini C et al. Non-hodgkin lymphomas presenting as soft tissue masses: a single center experience and meta-analysis of the published series. Clin Lymphoma Myeloma Leuk. 2013; 13: 258-65.
 6. Travis WD, Banks PM, Reiman HM. Primary extranodal soft tissues lymphoma of extremities. Am J Surg Pathol. 1987;11
 7. Ellestein J, Xeller C, Fromowitz F, Elias JM et al. Soft tissue T cell lymphoma of the forearm: a case report. J Hand Surg Am. 1984 May;9(3)
 8. Axiotis CA, Fuks J, Jennings TA, Kadish AS. Peripheral T-cell lymphoma presenting as a soft-tissue mass of the extremity. Arch Pathol Lab Med. 1988;112: 850-1.
 9. Sirsath NT, Lakshmaiah KC, Das U, Lokanatha D, Chennagiri SP, Ramarao C. Primary extranodal non-Hodgkin's lymphoma of oral cavity - a single centre retrospective study. J Can Res Ther 2014;10: 945-50.