



Compendium of Urinalysis – Urine Reagent Strips and Microscopy

Authors

Dr Nataraju G, Dr Gayathri M N, Dr Meghana P

Department of Pathology, Mysore Medical College and Research Institute, Mysuru, Karnataka, India

Corresponding Author

Dr Meghana P

Department of Pathology, Mysore Medical College and Research Institute, Mysuru, Karnataka, India

Phone number – 9591402851, Email: meghanap.mp@gmail.com

Abstract

Background: Urine examination also referred to as liquid renal biopsy has provided valuable clinical information about the functional status of the kidney. These results can be relied for a number of applications, including screening for diagnosis of asymptomatic disease, monitoring and following the course of a disease. Deplorably, because of the routine nature of this test, pathologists often spend comparable time examining both normal and abnormal urine specimens in an unsystematic fashion.

Methodology: Dipstick and microscopy urinalyses were carried out on 100 consecutive urine samples of patients and the results were statistically analyzed.

Results: Age of patients ranged from 1 month to 80 years. Male patients were in a higher number than females in most of the age groups. Dipstick showed sensitivity of 82%, 76% and 87% and specificity of 71%, 92% and 89% for leukocytes, nitrite and blood respectively.

Conclusion: The urinalysis by dipstick method should be followed by the microscopy for more accurate and valid results.

Keywords: Urinalysis, urine reagent strips, microscopy.

Introduction

An epidemiological transition is taking place in India with a decline in communicable diseases and a growing burden of chronic diseases. According to the first annual report published by the chronic kidney disease registry of India, diabetes and hypertension are the major causes of chronic kidney disease in India.¹ The present management strategies in renal diseases, aims mainly to the arrest of progression to the end stage renal disease.

As serum biochemical parameters do not show abnormality until late, renal diseases are seldom

diagnosed in the early stages.² Thus the tests which detect early stages of renal disease are of paramount importance.

Urine is a key health indicator for many diseases. Urine examination also referred to as liquid renal biopsy has provided valuable clinical information about the functional status of the kidney.^{3,4} The results can be relied for the diagnosis of asymptomatic disease, monitoring and following the course of a disease. Thus, urinalysis has evolved from an effectively bedside procedure to a well established and standardized laboratory practice.⁵

Deplorably, because of the customary nature of the test, pathologists often spend more time examining both normal and abnormal urine samples in a disorganized fashion. As the usual urine microscopy is labour concentrated and subject to less cautious analysis if done by rote, evaluating the practicability of pre-screening the urine specimens with a reagent strip prior to the urine microscopy may result in a better microscopic examination and faster results.

Materials and Methods

Collection of the specimen:

The 100 consecutive urine samples were collected in a clean, wide-mouthed and dry disposable plastic cups. Key patient data consisting of name, age, gender, collection date and time were affixed to the container before the sample is collected. All the urine samples were completely processed within 2 hours of collection, to circumvent the growth of any contaminating bacteria. Urine samples thus obtained were divided into 2 parts for urinalysis.

Dipstick urinalysis

The urinalysis includes physical, chemical and microscopic examination. The first part was immediately tested using reagent strip for urinalysis. The strips had specific reagent pads for qualitative and semi-quantitative evaluation of leukocytes, nitrite, urobilinogen, protein, pH, blood, specific gravity, ketone, bilirubin and glucose. The leukocytes measurement was read after 2 minutes, where as the nitrite and blood measurements were read at 60 seconds and the results were recorded as positive or negative.

Microscopic urinalysis

Urine samples were primed for microscopy by centrifuging 10 mL of urine for 5 minutes, at 1000 rpm. The supernatant was poured off and about 0.05 mL of the sediment was subsequently examined at low and high powers for the presence of white blood cells (WBCs), bacteria, red blood cells (RBCs), crystals, casts, epithelial cells, parasites and fungi.⁶ Cut off values for a positive result are: > 5 WBCs per high power field or > 3

RBCs per high power field or > 20 squamous epithelial cells per high power field or > 5 hyaline casts per low power field or presence of crystals, bacteria or yeast.

Results

100 consecutive urine samples were studied. Results obtained from the dipstick analysis and urine microscopy were compared.

In the present study, age of the patients ranged from 1 month to 80 years. Male patients were in a higher number than females in most of the age groups. Majority of the patients were from 61-70 years age group (Table 1). Out of the 100 samples, 95% of the urine specimens showed abnormal microscopic findings, while dipstick analysis showed 85% urine samples to be abnormal. Males had the higher prevalence of abnormal findings on urine microscopy (55%) than females (45%). Urine microscopy showed positive for WBCs in 83 of 100 samples whereas only 73 samples were positive on dipstick analysis. By manual urine microscopy, 75 of 100 samples were positive for bacteria, while only 59 samples were positive for nitrite on reagent strip analysis. 74 cases showed RBCs (Figure 1) on microscopy, while dipstick detected only 67 cases. Squamous epithelial cells (Figure 2) were seen in 40 urine samples by microscopy. 33 samples showed pathological casts on microscopy, and 29 out of these 33 samples showed protein positivity on dipstick. The total number of urine samples with protein positivity on dipstick analysis was 37. Hyaline (Figure 3) and granular (Figure 4) casts were the most common casts seen, followed by the RBC casts. Crystals were seen in 40 cases and calcium oxalate (Figure 5 and 6) crystals were the most common followed by the uric acid crystals (Figure 7). And 2 samples showed fungal hyphae (Figure 8) on urine microscopy.

Performance characteristics of urine reagent strips

Dipstick analysis showed 82 % sensitivity and specificity of 71 % for leukocytes. The nitrite and blood showed sensitivity of 76 % and 87%

respectively and the specificity of 92% and 89% respectively. When the leukocytes, nitrite and blood in dipstick were together taken into consideration, the sensitivity and specificity were

82% and 85% respectively and the positive and negative predictive values were 95% and 57% respectively.

Table 1: Distribution of age and sex in the study group

Age groups (yr)	Males	Females	Total (%)
0 – 10	11	06	17
11 – 20	05	08	13
21 – 30	01	09	10
31 – 40	04	03	7
41 – 50	08	04	12
51 – 60	08	06	14
61 – 70	13	08	21
71 – 80	04	02	06
Total	54	46	100

Table 2: Performance characteristics of dipstick urinalysis for leukocytes

Microscopy		
	+	-
Dipstick	68	05
+	15	12
-		

Parameter	Percentage
Sensitivity	82
Specificity	71
Positive predictive value	93
Negative predictive value	78

Table 3: Performance characteristics of dipstick urinalysis for nitrite

Microscopy		
	+	-
Dipstick	57	02
+	18	23
-		

Parameter	Percentage
Sensitivity	76
Specificity	92
Positive predictive value	97
Negative predictive value	56

Table 4: Performance characteristics of dipstick urinalysis for blood

Microscopy		
	+	-
Dipstick	64	03
+	10	23
-		

Parameter	Percentage
Sensitivity	87
Specificity	89
Positive predictive value	96
Negative predictive value	70

Table 5: Performance characteristics of leukocytes, nitrite and blood dipstick urinalysis

Dipstick	Microscopy	
	+	-
	+	189
-	43	58

Parameter	Percentage
Sensitivity	82
Specificity	85
Positive predictive value	95
Negative predictive value	57

Figure 1: Red blood cells (40 x)



Figure 2: Squamous epithelial cells (40 x)

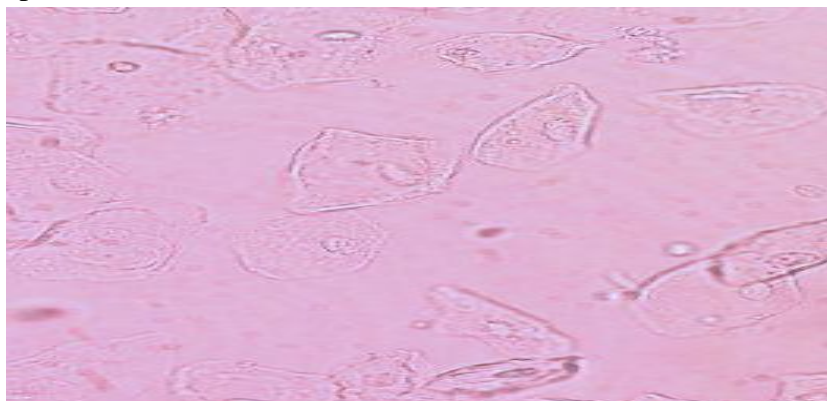


Figure 3: Hyaline cast (40 x)



Figure 4: Granular cast (40 x)



Figure 5: Calcium oxalate dihydrate crystal (40 x)



Figure 6: Calcium oxalate monohydrate crystal (40 x)

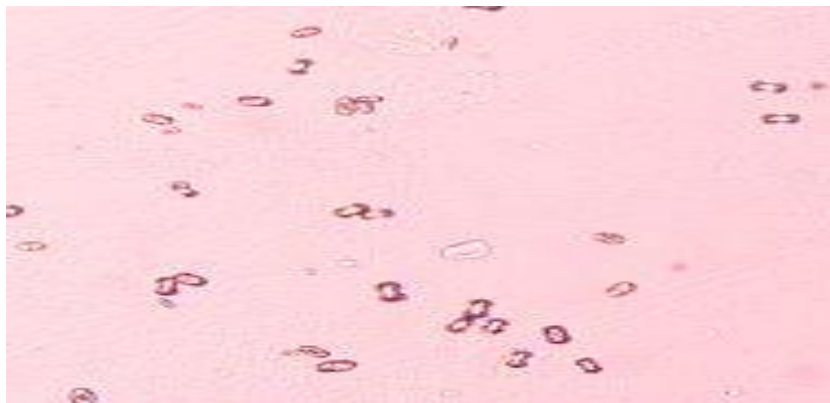


Figure 7: Uric acid crystal (40 x)

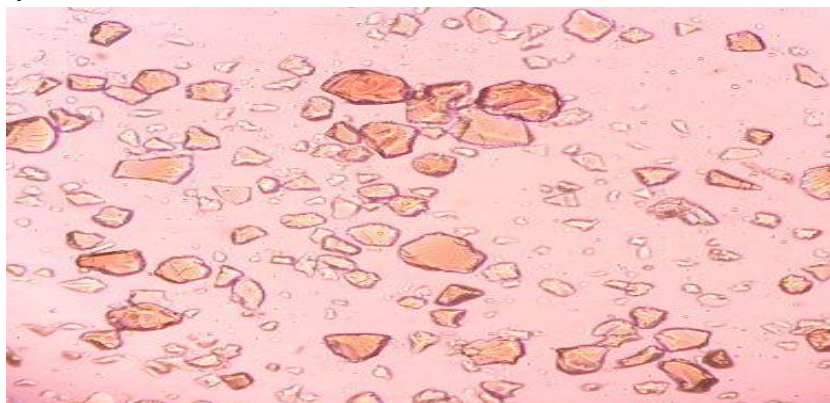
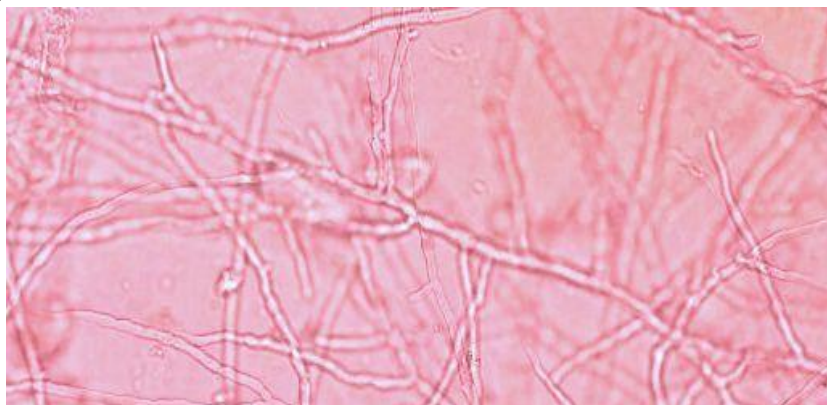


Figure 8: Fungal hyphae (40 x)

Discussion

Renal biopsy is an invasive procedure, time consuming and with repeated examination the patient acceptability of the procedure is poor. More rapid methods of diagnosis are thus valuable. The present concern has focused on suitable deployment of limited laboratory resources in the present day cost cognisant world and urinalysis has been a prototype of many new investigations.

Some authors feel that the work-load can be reduced notably by pre screening the urine specimens using the reagent strips and performing microscopic analysis on only those urine samples showing abnormality on reagent strips.⁷⁻¹⁰ In disparity, others are of opinion that pre-screening the urine samples using a reagent strip alone, and performing the microscopic analysis on biochemically abnormal urine results obtained on dipstick analysis is of modest importance as the loss of significantly valuable clinical data outweighs the cost savings.¹¹⁻¹³

Studies performed at the University of Nebraska by Tetrault GA suggested that only 1.5% of clinically significant microscopic findings would be missed by not performing sediment examination of specimens with completely negative dipstick results.¹⁴ Based on their study the laboratory reduced the number of microscopic sediment examinations it performed by 41.8%.

In contrast, Bartlett and colleagues found that 14.4% of their cases would be labelled falsely negative based on dipstick analysis only. And thus

all the urine samples at Bartlett's institution are examined microscopically.¹⁵

Shaw et al in their study on urinalysis concluded that a protein and blood negative dipstick result may be used to rule out the requirement for performing a microscopic examination in routine urinalysis, but only with false negative results of 13%.¹⁶

In the present study, the result obtained from the reagent strips were compared with the urine microscopy. The results thus analyzed demonstrate that the bedside reagent strips may be used for rapid analysis of urine to diagnose the uncomplicated conditions. Reagent strips have the benefit of being simple and rapid and can be easily performed in primary care. While the microscopic urinalysis for WBCs, bacteria and RBCs is noticeably more time consuming and labour exhaustive than the reagent strip method.

Although the usage of reagent strips remain an important tool in screening the cases of haematuria, the method does not confirm the diagnosis as it cannot differentiate between haemoglobinuria and myoglobinuria.

Furthermore, haemoglobinuria can occur without haematuria. Urine microscopy is thus useful in differentiating this and by detecting erythrocytes it confirms a positive dipstick reaction as haematuria and also gives considerable idea about the origin of haematuria within the urinary tract system by the morphology of RBCs.^{17,18} And also in the dipstick analysis, urinary protein and glucose excretions in excess of 500 mg/dL and 2 mg/dL respectively may diminish the intensity of the

reaction colour, as can certain drugs like cephalixin if administered in high doses, or boric acid if used as a preservative. The nitrite test depends on the detection of nitrites which are produced through the action of the bacterial enzyme nitrate reductase in the urinary bladder. Urine must be retained in the bladder for minimum of 4 hours for conversion of nitrate to nitrite and also, some organisms like Staphylococci and Pseudomonas do not convert nitrate into nitrite, thus resulting in false negative results on dipstick analysis.

Previous evaluations of the predictive value of combining leukocyte, nitrite and blood tests on dipstick have produced incongruous results,^{19,20} but the present study suggests that these tests to be of value.

In the present study, when only leukocyte was taken into consideration, sensitivity and specificity were 82% and 71% respectively. And consideration of leukocyte, nitrite and blood together, increased the specificity and positive predictive values to 85% and 95% respectively; however the sensitivity remained the same.

Conclusion

Rapid diagnosis or exclusion of the disease is valuable to the physician for early management and to arrest the progression of the disease. Therefore, reagent strip test may be performed when a very rapid result is desired. However exclusion of the microscopic examination, in our learning, resulted in only marginal workload savings. This fairly modest savings is overshadowed by the significant loss in valuable clinical data. Thus the urinalysis by dipstick method should be followed by the microscopy for more accurate and valid results.

More vigilance has to be taken by the laboratories contemplating the exclusion of routine urine microscopy based on the dipstick screen, to regard as whether such screening would be effective in their patient population.

Acknowledgments

We thank Dr. Bharathi M, Professor and Head, Department of Pathology, for sharing her pearls of wisdom with us during the course of this study.

Sources of support in the form of grants: Nil

References

1. Prabahar MR, Chandrasekaran V, Soundararajan P. Epidemic of Chronic Kidney Disease in India - What Can Be Done? Saudi J Kidney Dis Transpl 2008;19:847-53.
2. Prigent A. Monitoring renal function and limitations of renal function tests. Semin Nucl Med. 2008 Jan;38(1):32-46.
3. Marcussen N, Schumann J, Campbell R, Kjellstrand C. Cytodiagnostic urinalysis is very useful in the differential diagnosis of acute renal failure and can predict the severity. Ren Fail. 1995;17:721-9.
4. Obroniecka I, Rojewska J, Wancowicz Z. The value of urine sediment cytomorphology in the ambulatory differential diagnosis of hematuria. Pol Merkur Lekarski. 1998 Nov;5(29):285-7.
5. Morrison MC, Lum GDipstick Testing of Urine—Can It Replace Urine Microscopy? Am J Clin Pathol 1986; 85: 590-594.
6. World Health Organization. Manual of basic techniques for a health laboratory (2nd Ed). Geneva; World Health Organization, 2003.
7. Valenstein PN, Koepke JA: Unnecessary microscopy in routine urinalysis. Am J Clin Pathol 1984; 82:444-448.
8. Kiechle FL, Karcher RE, Epstein E: Routine microscopic examination of the urine sediment revisited. Arch Pathol Lab Med 1984; 108:855-856.
9. Smalley DL, Bryan JA: Comparative evaluation of biochemical and microscopic urinalysis. Am J Med Technol 1983; 49:237-239.
10. Christenson RH, Tucker JA, Allen E: Results of dipstick tests, visual inspection,

- microscopic examination of urine sediment, and microbiological cultures of urine compared for simplifying urinalysis. ClinChem 1985;31:448-450.
11. Nanji AA, Adam W, Campbell DJ: Routine microscopic examination of the urine sediment—Should we continue? Arch Pathol Lab Med 1984; 108:399-400.
 12. Resnick M: Simplifying urinalysis. Clin Chem 1985; 31:450-451.
 13. Szwed JJ, Schaust C: The importance of microscopic examination of the urinary sediment. Am J Med Technol 1982; 48:141-143.
 14. Tetrault GA. Automated reagent strip urinalysis: utility in reducing work load of urine microscopy and culture. Lab Med. 1994;25:162-167.
 15. Bartlett RC, Zern DA, Ratkiewicz I, Tetreault JZ. Screening for urinary tract infection with the Yellow IRIS. Lab Med. 1992;599-602.
 16. Shaw ST Jr, Poon SY, Wong ET. "Routine urinalysis": is the dipstick enough? JAMA.1985;253: 1596-1600.
 17. Bataille A, Wetzstein M, Hertig A, Vimont S, Rondeau E, Galichon P. Evidence of dipstick superiority over urine microscopy analysis for detection of hematuria. BMC Res Notes 2016;9:435.
 18. Anigilaje EA, Adedoyin OT. Correlation between dipstick urinalysis and urine sediment microscopy in detecting haematuria among children with sickle cell anaemia in steady state in Ilorin, Nigeria. Pan Afr Med J. 2013; 15:135.
 19. Wenk RE, Dutta D, Rudert K, et al. Sediment microscopy, nitriteuria and leukocyte esteraseuria as predictors of significant bacteriuria. J Clin Lab Automation 1982; 2: 117-21.
 20. Wilkins EGL, Ratcliffe JG, Roberts C. Leucocyte-esterase-nitrite screening method for pyuria and bacteriuria. J Clin Pathol 1985; 38: 1342-5.