



Original Article

A Prospective Study of Inguinal Hernia Patients Managed by Three Stitch Hernioplasty

Authors

Dr S.Jeevaraman¹, Dr Maragathamani Elangovan², Dr N. Mohammed Niyamathullah³,
Dr Vijay Anand⁴

¹Associate Professor of General Surgery, Thanjavur Medical College

²Professor of Surgery, Dhanalakshmi Srinivasan Medical College,

^{3,4}Post Graduate, General Surgery, Thanjavur Medical College

Abstract

Introduction: *Hernia is defined as an abnormal protrusion of a viscus or a part of the viscus through a normal or an abnormal opening in the walls of its containing cavity. The external abdominal hernia is the most common form of spontaneous hernia. The treatment options of hernia should be concerned with prevention of recurrence, prevention of infections and economic considerations. The purpose of this study is to report the observations made in the postoperative follow up of hernia repair by three stitch hernioplasty method, in the Department of general surgery, Thanjavur Medical College, over a period of 2 years.*

Materials and Methods: *100 cases of inguinal hernia admitted at Thanjavur Medical College and Hospital during the study period June 2015 to June 2017 who satisfied the inclusion and exclusion criteria were included in the study. For all these patients, the usual Lichtenstein's repair was not done but a slightly modified procedure, THREE STITCH HERNIOPLASTY was done after getting the consent.*

Results: *Various factors were analysed like age incidence, sex, side and Postoperative complications observed in this group of patients were in 100 patients studied 12 developed seroma, 4 developed haematoma, 2 developed wound infection, 2 developed chronic groin pain, Only one developed recurrence, none developed foreign body sinus and all the patients returned to work early i.e. before 6 weeks except 2.*

Conclusion: *The Three Stitch Hernioplasty is a simple method, easy for the beginners to adopt, has less foreign body reaction, less time consuming, causes less tissue trauma and lesser chance of vascular injury.*

Keywords: *Three stitch hernioplasty, mesh, seroma, recurrence.*

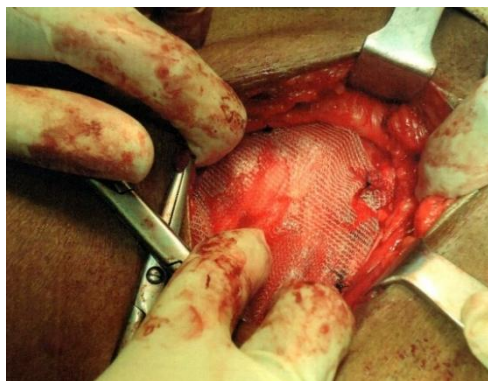
Introduction

Hernia is defined as an abnormal protrusion of a viscus or a part of the viscus through a normal or an abnormal opening in the walls of its containing cavity. Hernia may be spontaneous or acquired. The external abdominal hernia is the most

common form of spontaneous hernia. The treatment options for hernia repair, is still controversial because hernias are polymorphous lesions and because of the choice of operations and the features of the patients are diverse. Recurrence rate in hernia surgery needs further

evaluation. Hence the treatment option for hernia should be concerned with prevention of prevention of infections and economic considerations. The purpose of this study is to report the observations made in the postoperative follow up of hernia repair by three stitch hernioplasty method in the department of General Surgery, Thanjavur medical college, over a period of two years (2015-17).

Three stitch hernioplasty



Aim of the Study

To analyze the following complications in inguinal hernia patients operated by three stitch hernioplasty technique, Recurrence of inguinal hernia, Chronic groin Pain, Foreign body sinus, Seroma, Hematoma, Wound infection are the parameters observed.

Materials and Methods

Type of Study: Prospective study

Cases: 100 cases of inguinal hernia patients admitted at Thanjavur Medical College.

Inclusion Criteria: Indirect inguinal hernia, direct inguinal hernia, Age 21 -60 years, Good muscle tone

Exclusion Criteria: Recurrent hernia ,Sliding hernia, Hypotonia, Age more than 60 years, Bladder outlet obstruction , LRI/COPD , Ischemic heart disease

Materials Used: Polypropylene prosthetic mesh

Period of Study: July 2015 to June 2017

Place: Department of General Surgery, Thanjavur Medical College & Hospital

Method of Study: All the cases included in this study were of elective admission only. Emergency

cases like obstructed or strangulated inguinal hernia were not included in this study.

100 Inguinal Hernia patients admitted in Thanjavur Medical College & Hospital during the study period who satisfied the inclusion and exclusion criteria were included in the study. For all these patients, the usual Lichtenstein's repair was not done, but a slightly modified procedure, three stitch hernioplasty was done after getting their consent.

In this procedure the following steps were carried out. The patient was made to lie in supine position after giving spinal anesthesia. Parts painted and draped. The inguinal skin incision is made in the medial two thirds and 2cms above the inguinal ligament. Incision deepened to reach the external oblique aponeurosis. Three named veins that are present in the subcutaneous plane are cut and ligated. External oblique aponeurosis cut open along the direction of its fibres and the superficial inguinal ring is cut open. A plane of cleavage is created between the external oblique aponeurosis and the conjoint tendon superiorly. The inguinal ligament is well defined by dissecting in the floor of inguinal canal. The cremastic muscle with cord structures is hooked out. Ilioinguinal nerve is preserved to avoid entrapment and chronic pain in the operative period. Direct hernia sac, if present (medial to the inferior gastric artery) must be invaginated by opposing the fibres of transversalis fascia, if the sac is small. For large direct hernias, the sac is opened and the transversalis fascia is repaired. In case of indirect inguinal hernia, the cremastic muscle fibres are cut open followed by the internal spermatic fascia. The sac is identified as a glistening white structure and is dissected up to the deep the ring, after lateralising the cord structures. Sac is cut open at the fundus and the contents, if any must be reduced. Sac is transfixed at its neck and excess sac excised. The sac is pushed inside the deep ring. When the deep ring is patulous, transversalis fascia is plicated by suture narrowing the deep ring (Lytle's •repair). Now the prolene mesh is fashioned as in Lichtenstein's repair, placed and fixed only by three prolene

stitches. *The first stitch is made in the periosteum of pubic tubercle. The second stitch is taken in the inguinal ligament (1.5 cms lateral to pubic tubercle) and the third stitch is from the medial most part of the conjoint tendon* i.e. the mesh is fixed in the medial aspect alone. Haemostasis is achieved. Cord structures placed over the mesh. External oblique aponeurosis sutured with polygalactin (vicryl) in continuous stitches. Wound closed in layers. Scrotal support given. Postoperatively the patients were treated with antibiotics and analgesics, and were discharged on and postoperative day. The patients were followed up intervals of 1 week, 1 month, 3 months, 6 months and 1 year. In the follow up, the patient was assessed for development of any seroma, hematoma, wound infection, chronic groin pain, recurrence, foreign body sinus and their early return to work.

Observation and Results

1. Age incidence

All the cases included in this study were in the age group 21 – 60 years.

Age	Percentage
21 – 30 years	18%
31-40 years	10%
41-50 years	24%
51-60 years	48%

2. Sex incidence

All the patients in this study were males only

	Number	Percentage
Males	100	100%
Female	0	0

3. Side

Of the 100 cases, 50 cases had right sided hernias and 25 cases had left sided hernias and 25 cases had bilateral inguinal hernias

Right	50%
Left	25%
Bilateral	25%

4. Common presentation

- Swelling in the inguino-scrotal or inguinal region — 58%

- Pain in the inguinal region or inguino-scrotal region — 16%
- Swelling and pain in the inguino-scrotal region — 26%

5. Postoperative complications

The patients were examined at regular intervals of 1 week, 1 month, 3 months, 6 months and 1 year for evaluation of postoperative complications and the following observations were made.

Seroma

Among 100 patients followed up in this study, 12 patients developed seroma.

Haematoma

Four patients developed hematoma, out of 100 patients, operated for inguinal hernia by three stitch hernioplasty method.

Wound infections

Two patients developed wound infection, among the 100 patients operated. The patients were given one preoperative dose and three postoperative doses of parenteral antibiotics. The drug used for this was cefotaxirne. The two patients were diabetic and they required additional antibiotics with glycaemic control.

Chronic groin pain

Two patients in our study developed chronic groin pain. Chronic groin pain is defined as, the post-operative pain which lasts for more than 3 months and contributes to significant morbidity. Pain assessment was carried out by VAS (VISUAL ANALOG SCALE) score with a score of less than I as mild, between 1 to 5 as moderate and greater than 5 as severe pain. As per Lichtenstein et al, in a study performed in 1988 the incidence of chronic groin pain is 1 to 2 per cent. In another study conducted in 104 patients treated by laparoscopic hernia repair, by Panton & Panton in 1994, the incidence of the chronic groin pain is only 1%. In this study the incidence of chronic grom pain is 2%. In a study conducted in Armed Force Medical College in 2010 by S.S. Jaiswal, R. Chaudhry, A. Agarwal concluded that meticulous identification and preservation of the nerves, using absorbable suture for fixation and *minimum*

number of sutures to fix a mesh contributed to low incidence of CGP.

Recurrence

Only one patient in our study developed recurrence following three stitch hernioplasty. The patients were followed up at regular intervals of 1 week, 1 month, 3 months, 6 months, 1 year and some patients' upto 2 years. Long term follow up was not possible as this is only a prospective study conducted for a period of 2 years. Recurrence rate in any meticulously done tension free mesh repair or Shouldice method of hernia repair is less than 2 percent. The recurrence rate in this study is 1 percent, but the study was conducted only for 2 years. Only 50 percent of recurrence will occur in the first 2 years and hence a minimum of 5 years of study is necessary to know the efficacy of the type of hernioplasty done in our study. The patient who developed recurrence in our study had a large defect with thinned out fascio-aponeurotic fibres and he also had postoperative wound infection. Moreover he was also a diabetic. The patient developed recurrence after 1 year and 5 months of hernia surgery.

Foreign body sinus

None of the patients in our study developed foreign body sinus as a complication in the follow up.

6. Early return to work

Almost all the patients returned early to their work except two. This was assessed after 4 to 6 weeks of surgery i.e. three stitch hernioplasty. Those who resumed to work before this period were considered to have returned to work early. The two patients had chronic inguinal pain because of which they were disabled from resuming their work.

Discussion

We have come a long way since Bassini first described hernia repair hundred years ago. Now many newer procedures are available for the repair of hernia being practiced in various

institutions with latest technologies, but the older techniques have not been totally abandoned. Even though there are various laparoscopic procedures for inguinal hernia repair, they are effective only in experienced hands. But for the beginners or learners the experience in open hernia surgery is mandatory. The aim of our study is to know the efficacy of three stitch hernia pair which when done, with care and precision in selected patients. With careful dissection and proper repair is as effective as any other tension free/laparoscopic procedures.

Our study includes 100 cases of uncomplicated inguinal hernia, which three stitch hernioplasty was done. The incidence of immediate postoperative complications like wound seroma, hematoma and wound infections were studied along with long term complications like recurrence, chronic groin pain and fistula formation.

Due to the short period of our cohort study, long term follow up could not be undertaken. In our study, the following results were obtained.

Seroma	12%
Hematoma	04%
Wound infection	02%
Chronic pain	02%
Recurrence	01%
Foreign body fistula formation	00%

Conclusion & Summary

The incidence of long term complications of three stitch hernioplasty are comparable to that of other standard tension free open hernia repair as well other laparoscopic procedures. But the only limitation we have in our study is the duration. We still need to follow the cases for a minimum 5 years period to get a standard and liable result. Moreover the three stitch hernioplasty method is a *simple method, easy for the beginners to adopt, has less foreign body reaction, less time consuming, causes less tissue trauma, and lesser chance for vascular injury.*

References

1. Repair of groin hernia with synthetic mesh: meta-analysis of randomized

- controlled trials. *Ann Surg* 235:322-332, 2002.
2. Neurnayer La, Gawande AA, Wang J, et al: Proficiency of surgeons in inguinal hernia repair: Effect of experience and age. *Ann Surg* 242:344- 348, discussion, 348-352,2005.
 3. Grant AM, Scott NW, O'Dwyer PJ : Five — year follow — up of a randomized trial to assess pain and numbness after laparoscopic or open repair of groin hernia. *Br. J Surg* 91:1570-1574,2004.
 4. Nienhuijs SW, Boelens OB,Strobbe U: Pain after anterior mesh repair. *J Am Coll Surg* 200:885-889,2005.
 5. Lichtenstein IL, Shulman AG, Amid PK, et al: The tension-free hernioplasty. *Am J Surg* 157:188-193,1989
 6. Janu PG, Sellers KD, Mangiante EC: Recurrent inguinal hernia: Preferred operative approach. *Am Surg* 64:569-573; discussion. 573 - 574,1998
 7. Sirnons MP, Kleijnen J. van Gelciere D, et al: Role of the Shouldice technique in the inguinal hernia repair: A systematic review of controlled trials and a meta-analysis. *Br J Surg* 83:734-738, 1996.
 8. Sabiston's Textbook of surgery,18th edition. 'olume II: pg 1155 1179
 9. Schwartz's Principles of surgery, 9th edition, pg 1305— 1342
 10. McIntosh A, Hutchinson A, Roberts A, et al. Evidence based management of groin hernia in primary care — a systematic review. *Fam Pract* 2000; 17:442
 11. Schumpelick V, Treutner KH, Ant O. Inguinal hernia repair in adults. *Lancet* 1994;344:375
 12. Kang SK, Burnett CA, Freund E, et al. Hernia: is it a work-related condition'? *Am J med Med* 1999;36:638
 13. Tverskoy M, Cozacov C, Ayache M, et al. Postoperative pain after inguinal herniorrhaphy with different types of anaesthesia. *Anesth Analg* 1990;70:29
 14. Klingsworth AN, Britton Bj, Morris Pj. Recurrent inguinal hernia after local anesthetic repair. *Br J Surg* 1982;68:273
 15. Lichtenstein IL, Shulman AG, Amid Pk. The cause, prevention and treatment of recurrent groin hernia. *Surg Clin North Am* 1993;73:529
 16. Gilber AT. An anatomic and functional classification for the diagnosis and treatment of inguinal hernia. *Am J Surg* 1989;157:331
 17. Scott NW, Webb K, Go PM, et al. Open mesh versus non-mesh repair of inguinal hernia. *Cochrane Database Syst Rev* 2001; (4):CD002197
 18. Bay-Nielsen M, Kehlet H, Strand L, et al. Quality assessment of 26,304 herniorrhaphies in Denmark: a prospective nationwide study. *Lancet* 2001;358:1124
 20. Maingot's Abdominal Operation, Michael J.Zinner, Stanley W. Ashley, eleventh edition pg: 103-120.