



## Idiopathic Generalized Hypercementosis: A Case Report

Authors

**Dr Deep Shah<sup>1</sup>, Dr Shreyansh P. Sutaria<sup>2</sup>, Dr Setu Shah<sup>3</sup>, Dr Bhagyashree Dave<sup>4</sup>**

<sup>1,2</sup>M.D.S., Oral Medicine & Radiology

<sup>3</sup>M.D.S., Oral and Maxillofacial Surgery

<sup>4</sup>M.D.S., Prosthodontics and Crown & Bridge

Department of Oral Medicine & Radiology, College of Dental Science & Research, Bopal, Ahmadabad, Gujarat, India

Corresponding Author

**Dr Deep S Shah**

18, Anupam Society, Nr, Naranpura Cross Roads, Naranpura, Ahmedabad-380013, Gujarat, India

Mobile No: +91 9979973019, Email: [drdeep1929@gmail.com](mailto:drdeep1929@gmail.com)

### Abstract

*The following case report describes the clinical and radio graphical presentation of a female who attended a general dental practice as a new patient. The patient was diagnosed with generalised hypercementosis, possibly attributable to oral neglect. Hypercementosis is associated with a number of aetiological factors, which may be local or systemic in nature. It is important that the general dental practitioner is aware of these factors and is able to distinguish presentation due to a local cause from that of a systemic disease process. The aims of this paper are to illustrate an unusual presentation of hypercementosis and to discuss the radiographic differentiation that led to diagnosis.*

**Keywords:** Hypercementosis, Paget's disease.

### Introduction

The range of patients presenting in the primary care setting provides the general dental practitioner with a multitude of diagnostic challenges. The aims of this paper are to illustrate an unusual presentation of a common pathophysiological process that on first glance may be mistaken for a more sinister condition and to discuss its radiographic differentiation.<sup>1,2</sup>

### Case Report

#### History

A 56 -year-old female patient presented in general dental practice in dept of oral medicine and

radiology at CDSRC as a new patient. Her chief complaint was that of pain in upper left front and back tooth region since 15 days. Pain mainly occurs during mastication.

The patient stated that she had previously been seen by a general dentist for regular dental examinations and for extensive restorative treatment. The patient reported no history of trauma.

The initial treatment provided for this patient involved a course of initial therapy with root canal treatment in #21 22 24 , oral hygiene instruction, extraction of #14 15 16 17 & #31 34 35 36 37, routine restorations and the provision of a

maxillary and mandibular acrylic- based, removable partial denture.

The patient appeared to be in an overall good state of health at the time of the dental visit. A review of the medical history revealed hypertension diagnosed several years earlier and controlled by medication. At the time of the dental examination, only blood pressure medication was being taken by the patient.

### Examinations

The patient's vital signs were all found to be within normal limits. A thorough examination of the head and neck regions revealed no abnormal findings. The intraoral examination revealed a dentition in good state of repair with no abnormalities present. In addition, examination of the oral soft tissues revealed no unusual findings.

The patient's dental radiographs were taken Based on the findings of the oral examination and the patient's previous history. Examination of the periapical radiograph in the area of the left maxillary premolar region revealed an abnormally large and bulbous root on tooth #24

A dental panoramic tomography was taken. This indicated generalised moderate horizontal alveolar

bone loss and an unusual appearance to the roots of a number of teeth with an intact lamina dura outline.

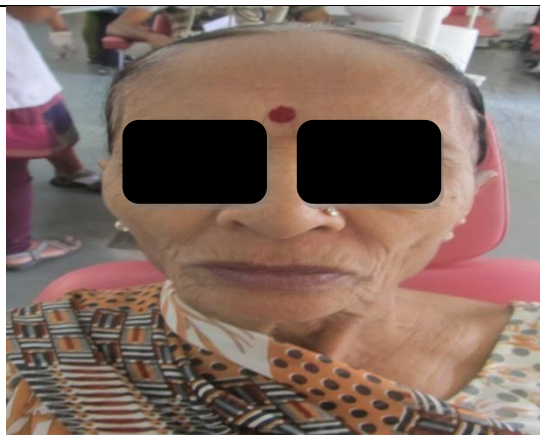### Radiographic Features

On a dental radiograph, the teeth affected by hypercementosis exhibit a bulbous, thickened appearance of the root surface. In addition, an excess amount of cementum is seen along all or part of the root surface. The apical regions of teeth are affected.

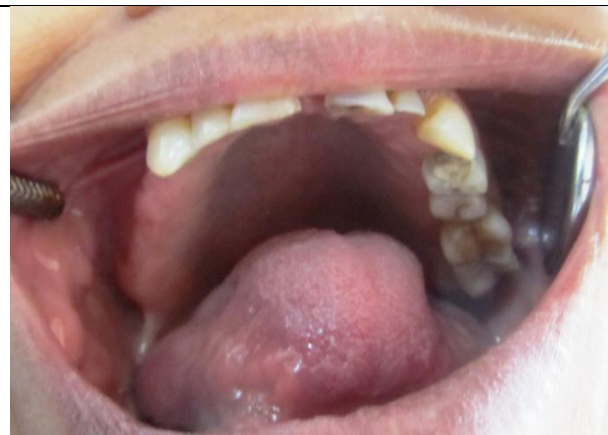Tooth roots affected by hypercementosis appear enlarged and bulbous. The affected roots are separated from periapical bone by both a normal-appearing periodontal ligament space and intact lamina dura.

### Diagnosis and Treatment

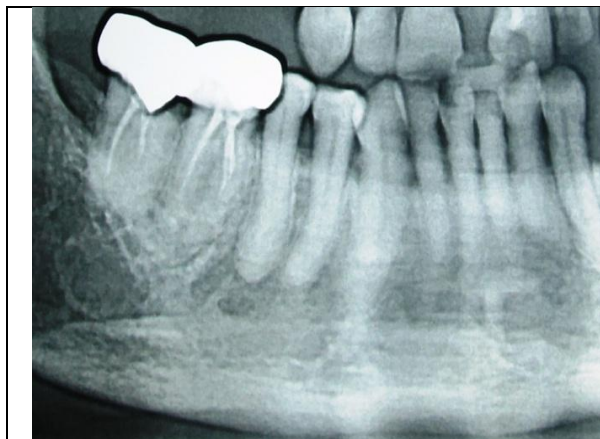
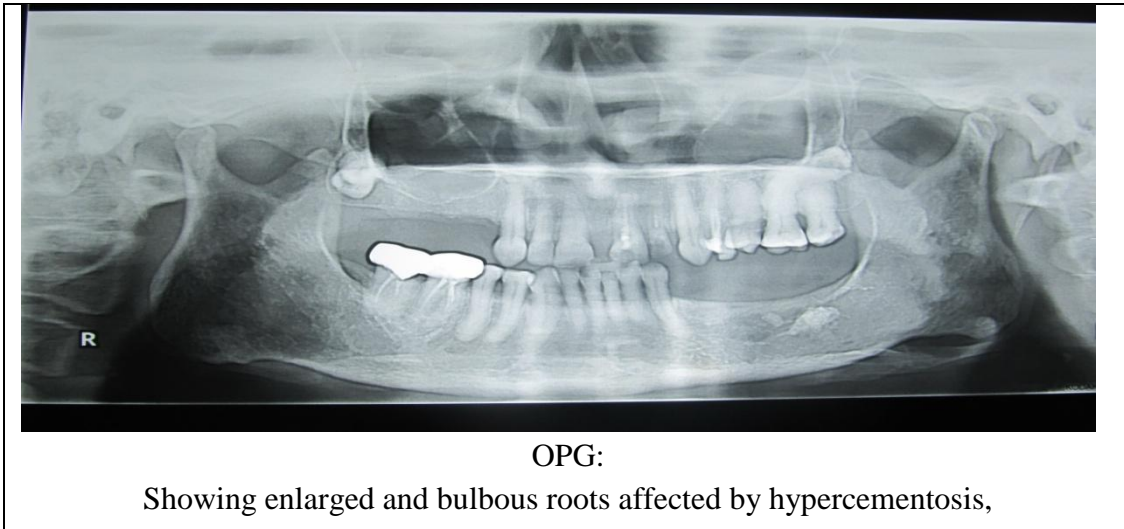
The diagnosis of hypercementosis is made based on the characteristic radiographic features described. Hypercementosis does not require treatment. In cases where extraction of an affected tooth is necessary, the tooth may be sectioned to facilitate removal.



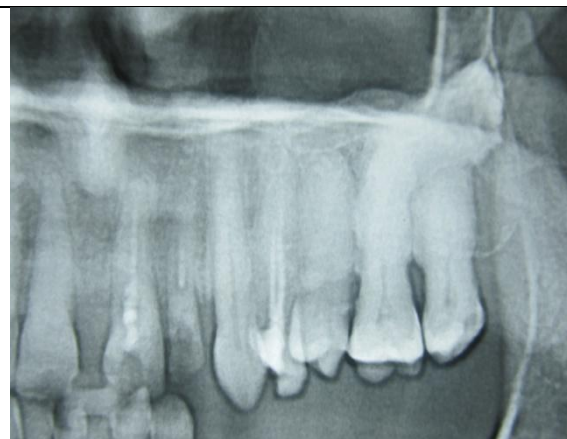Anterior view:  
Normal extraoral appearance



Intraoral view:  
No significant changes



**Mandibular teeth:**  
Teeth affected by hypercementosis exhibit a bulbous, thickened appearance of the root surface and normal-appearing periodontal ligament space and intact lamina dura.



**Maxillary teeth:**  
Teeth affected by hypercementosis exhibit a bulbous, thickened appearance of the root surface and normal-appearing periodontal ligament space and intact lamina dura

**Discussion**

Cementum is an a vascular dental hard tissue that is deposited onto the root dentine surface, whose basic function is to provide support for the tooth in its socket. It is composed of 45-50% hydroxyapatite crystals and an organic matrix primarily consisting of collagen fibres and mucopolysaccharide ground substance.<sup>1</sup> Cementum is deposited at the apex of the tooth throughout life as part of a normal physiological process to maintain occlusal height and thus the root ends to be thicker apically.<sup>1,5</sup>

Hypercementosis (cemental hyperplasia) has been defined as the excessive deposition of the cementum of the tooth. It is a non-neoplastic condition. There appears to be no sexual or racial

predilection and it may occur at any age. It is more prevalent in the permanent dentition and incidence tends to increase with age due to cumulative exposure to aetiological factors.<sup>1,4,5</sup>

The mandibular molars were affected most frequently, followed by the mandibular and maxillary second premolars and mandibular first premolars. Mandibular teeth were affected 2.5 times more often than maxillary teeth.<sup>1,2</sup> Cementum is deposited commonly on the apical two-thirds of a root but may be often found along the whole length of the root. Deposition tends to be irregular in pattern, producing bulbous roots with a characteristic ‘clubbed’ appearance, and may affect focal areas of the root surface.<sup>1,5,6,</sup>

Hypercementosis may affect a single tooth (localised hypercementosis), many or all of the teeth (generalised hypercementosis). Localised hypercementosis appears to occur more frequently than the generalised form and is a common incidental finding on dental radiographs and extracted teeth.<sup>1</sup>

It may be idiopathic; however, there are a number of aetiological factors associated with the condition. Commonly, the presence of low-grade chronic pulpal, periapical or periodontal infection may result in the deposition of cementum, although this is not a consistent consequence.<sup>5</sup> If a tooth is, or becomes, non functional—perhaps due to the loss of an opposing tooth—cementum may be deposited at the apical third of its root(s) in an attempt to achieve occlusal contact.

Mechanical stimulation below a certain threshold may also induce the deposition of cementum. Cementum may be deposited as a repair mechanism in the situation of root fracture in vital teeth with the aim of uniting the separated fragments. Systemic aetiological factors tend to lead to a generalised pattern of hypercementosis.<sup>4,5,6</sup> Hypercementosis is an important manifestation of Paget's disease and is a common finding that may aid diagnosis.

Paget's disease is a chronic, progressive, metabolic bone disease of unknown aetiology, but thought to be a result of a viral infection. It is a relatively common condition, affecting people over the age of 40 years. The condition appears to occur only in the mature skeleton and tends to involve those bones that normally contain haemopoietic tissue in adult life.<sup>5,7</sup>

Paget's disease of the jaws is often detected through routine dental radiographic examination. There may be thickening and widening of the alveolar ridges, flattening of the palate and expansion of the maxillary tuberosities.<sup>1,7,8</sup> This may lead to lip incompetence, alteration of occlusion and spacing of the teeth. Sequelae of Paget's disease of the jaws include disorganised bone breakdown, bone pain, bone deformity, fracture and osteomyelitis following extraction or

routine endodontics.<sup>7,8</sup> The presence of generalized hypercementosis should always suggest to the clinician that Paget's disease could be present.<sup>7</sup>

### **Radiographic Appearance of Hypercementosis**

The diagnosis of hypercementosis is usually made due to the characteristic 'clubbed' appearance of the root(s). There are two main radiographic appearances of hypercementosis: bulbous enlargement (symmetric or asymmetric) and symmetric enlargement, involving the whole of the root surface.<sup>5,6</sup>

The appearance may be subdivided into that where the secondary cementum is of the same density as the primary cementum and dentine, or that where the secondary cementum appears less dense and is able to be clearly differentiated from the primary cementum and dentine. The radiolucent shadow of the periodontal membrane (in its normal dimension) and the radiopaque lamina dura are always apparent around the outer border of the area of hypercementosis, enveloping it as they would normal cementum.

This is an important diagnostic indicator and may help to exclude certain lesions from the differential diagnosis. Thus, periapical cemental dysplasia, condensing osteitis and focal periapical osteopetrosis may be excluded as they all lie outside the shadow of the periodontal membrane and lamina dura.<sup>1,6</sup>

A benign cementoblastoma may radiographically resemble hypercementosis in its early stages; however, once mature, this lesion is of non-uniform density, appears fused to the root and is often accompanied by root resorption. Clinically, there is usually evidence of bony expansion.<sup>3</sup>

There is an exception to the common diagnostic features in the case of periapical infection, where initial hypercementosis is followed by widening of the periodontal ligament space and an absence of the lamina dura outline as the periapical infection progresses.<sup>1</sup>

Occasionally, more often in the situation of excessive occlusal loading, 'spike like'



projections of excess cementum may be seen radiating from the root surface, often at the apex.<sup>1,6,7</sup> Where root fracture of a vital tooth has stimulated the formation of a cemental bridge, hypercementosis may be seen on the radiograph protruding beyond the root outline in the area of the fracture, if the fragments are separated by a radiographically visible distance.<sup>1,6</sup>

In Paget's disease, the bony lesions produced have a characteristic 'cotton wool' appearance because of patchy resorption followed by apposition, as a result of repeated episodes of increased bone resorption followed by excessive and uncontrolled attempts at repair.<sup>6,7,8</sup> After the development of the bony changes, hypercementosis often occurs on one or more roots, commonly of posterior teeth. Therefore, the presence of sclerotic lesions within the bone in association with hypercementosis should lead to the suspicion of Paget's disease.<sup>7,8</sup>

### Conclusion

This report describes a case of generalized hypercementosis likely to be attributable to dental neglect found following routine examination in general dental practice. It was diagnosed on the basis of the radiographic appearance, namely bulbous enlargement of many of the roots of the teeth thought to be in response to chronic pulpal and periodontal inflammation. The outline of the primary cementum and dentine may be seen within most of the lesions.

### Bibliography

1. Generalised Hypercementosis: A Case Report By Rachel Seed And Paul P Nixon; Primary Dental Care 2004;11(4):119-122.
2. Case 3 A Case Of Hypercementosis In Registered Dental Hygienist By Joen Iannucci Haring, Dds, Ms, Is An Associate Professor Of Clinical Dentistry, Section Of Primary Care, The Ohio State University College Of Dentistry.
3. Case Report Atypical Hypercementosis Versus Cementoblastoma L Napier Souza1, S Monteiro Lima Ju'Nior2, Fj Garcia Santos Pimenta2, Ac Rodrigues Antunes Souza And R Santiago Gomez,; Dentomaxillofacial Radiology (2004) Vol. 33; Pg:267-270.
4. R Rajendran ; Regressive Alteration Of Teeth And Disease Of Bone & Joints ; In: Shafer's Textbook Of Oral Pathology (5<sup>th</sup> Edition); Elsevier; 2008; Pg: 811-812 &1001-1007 .
5. Anil Govindrao Ghom; Teeth Anomalies & Disease Of Bone Manifested In Jaw; In: Textbook Of Oral Medicine (2<sup>nd</sup> Edition);Jaypee; 2010; Pg-123-124 & 839-841.
6. Oral Radiology: Principles And Interpretation, 5<sup>th</sup> Edition By Stuart C. White Dds Phd, Michael J. Pharoah Dds; Elsevier 2006 ; Pg 362-364.
7. Paget's Disease Of Bone By Ethel S. Siris; Journal Of Bone And Mineral Research 1998 ;Volume 13; Number 7;Pg:1061-1065 .
8. Paget's Disease Of Bone By John P Walsh ,Mja ; September 2004 Volume 181; Number 5&6; Pg:262-265.