



## Case Report

# Cardiac Metastasis of Primary Adenocarcinoma of Gall Bladder: Case Report

Authors

**Dr Padam Parmar<sup>1\*</sup>, Dr Promil Jain<sup>2</sup>, Dr Veena Gupta<sup>3</sup>, Dr Sonu Kalyan<sup>4</sup>,  
Dr Vasundhara Sharma<sup>5</sup>, Dr Aastha Dhamija<sup>6</sup>**

<sup>1</sup>Assistant Professor, Department of Pathology, Dr S.N. Medical College Jodhpur

<sup>2</sup>Assistant Professor, Department of Pathology, PT BDS PGIMS, Rohtak, Haryana

<sup>3</sup>Professor, Department of Pathology, PT BDS PGIMS, Rohtak, Haryana

<sup>4</sup>Senior Resident, Department of Pathology, PT BDS PGIMS, Rohtak, Haryana

<sup>5,6</sup>Resident, Department of Pathology, PT BDS PGIMS, Rohtak, Haryana

\*Corresponding Author

**Dr Padam Parmar**

Department of Pathology, Dr S.N. Medical College Jodhpur, Rajasthan, India

Email: [drpadamparmar@gmail.com](mailto:drpadamparmar@gmail.com), Tel. No.: 9355149508

## Abstract

*Primary tumors of heart are less common than secondary involvement. Isolated cardiac metastasis usually rare and mostly it is associated with wide spread of malignant tumor. Diagnosis of cardiac metastasis is difficult due to lack of specific cardiac symptoms and presence of symptoms due to disseminated cancer. Cardiac metastasis have been found in autopsies of patients with various malignancies except tumors of central nervous symptoms. We observed cardiac metastasis in patient of gall bladder malignancy (adenocarcinoma) with involvement of various other organs.*

**Keywords:** *autopsy; cardiac metastasis; disseminated malignancy; gall bladder; adenocarcinoma.*

## Introduction

Metastasis to heart and pericardium may go unrecognized until autopsy due to non-specific symptoms. Usually, heart metastases are clinically silent and impairment of cardiac function is observed in approximately 30% of patients which is due to massive pericardial effusion and if the left heart is involved. In symptomatic patients, secondary cardiac metastases may lead to myocardial infarction, arrhythmia, cardiac tamponade, and congestive heart failure.<sup>1,2</sup>

Cardiac metastases are rarely seen as the first site of metastases and usually seen with disseminated cancer. Cardiac metastases have been found in 6–20% of autopsies of patients with malignant neoplasms especially with malignant melanoma, lymphoma, leukemia, breast, and lung cancers.<sup>2</sup> In our patient, we observed cardiac metastasis from primary adenocarcinoma of gall bladder along with metastasis in various organs.

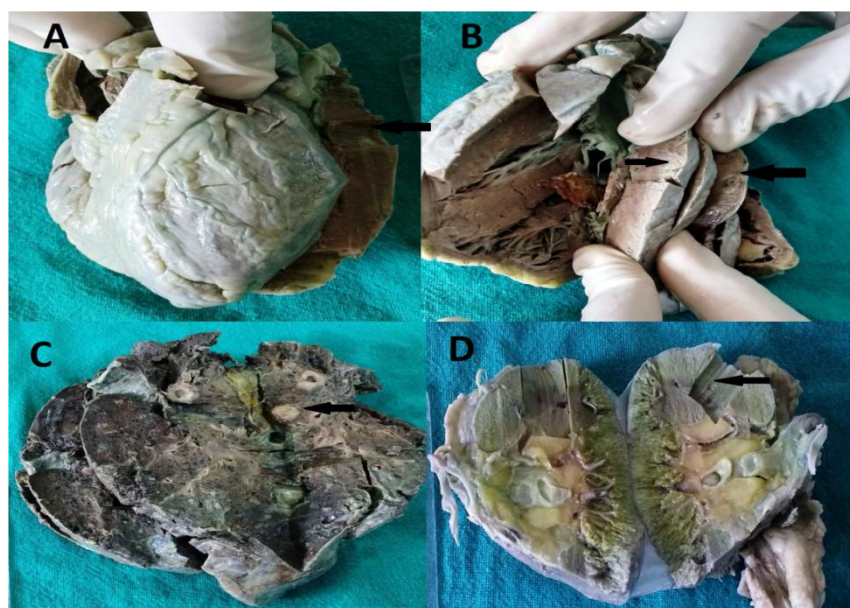### Case Report

A forty year old male admitted to emergency department due to sudden collapse. Past history revealed a diagnosis of primary malignancy of gall bladder five years back and patient was on treatment. During the course of the treatment, patient was dead. A clinical autopsy was conducted with proper consent to know exact nature of death. Autopsy revealed a tumor mass arising from gall bladder which had perforated the upper part of gall bladder. Metastatic tumor nodules were observed on liver surface. All the organs were grossly normal for tumor metastasis. Representative part of spleen, kidney and lungs along with whole specimen of brain, heart and liver with gall bladder were sent for histological examination.

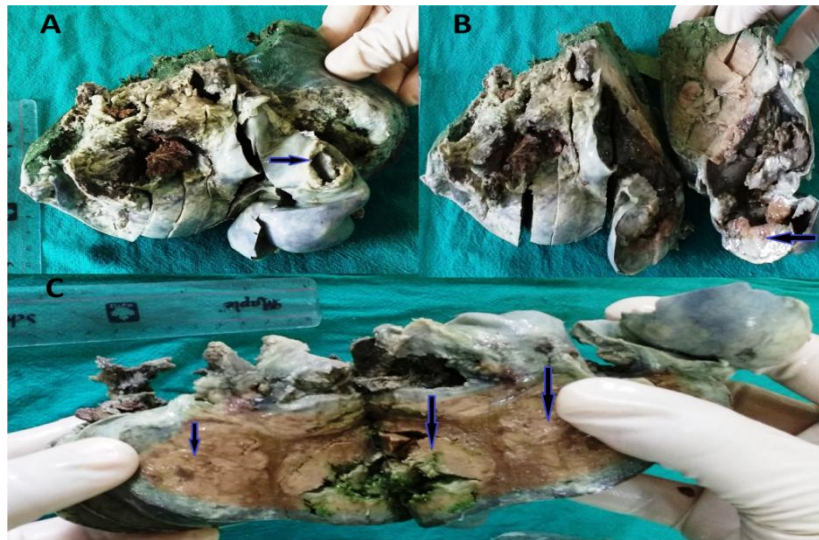
Heart specimen was received which was weighing 210 gms and measuring 10x6x4 cms. On cutting open, right ventricular wall, left ventricular wall and interventricular septum measured 0.3, 1.5 and 1.2 cms in thickness respectively. Multiple circumscribed grey white nodules identified (varying in diameter from 0.2 to 0.5 cms) in right and left ventricular walls. (figure 1) No abnormalities were observed on serial sectioning of brain specimen and spleen. On serial sectioning

of lung and kidney, multiple circumscribed grey white nodules identified (varying in diameter from 0.1 to 0.3 cms). (figure 1) External surface of liver showed multiple grey white nodular areas. On serial sectioning of liver, multiple grey white nodules identified varying in diameters from 1.6 to 4.0 cms. External surface of gall bladder showed a perforation of 1.5 cms diameter with protrusion of grey white mass. On cut open, multiple gall stones identified along with grey white mass (measuring 7x4 cms) which is almost obstructing the lumen of gall bladder and protruding through perforation. (figure 2)

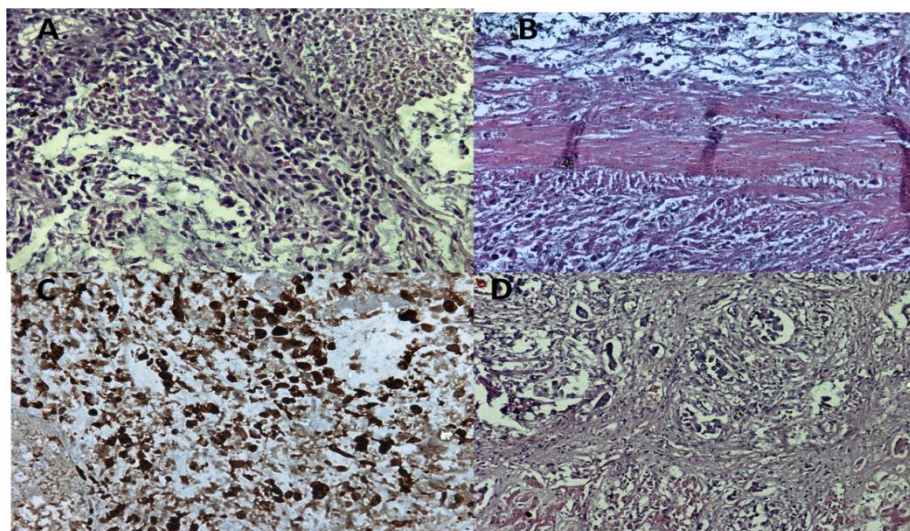
Histopathological sections from gall bladder mass showed features of adenocarcinoma, which was infiltrating all the layers of gall bladder with extensive areas of necrosis. Sections examined from liver showed multiple areas of infiltration by adenocarcinoma with extensive areas of necrosis (metastatic tumor nodules). (figure 3) Representative sections examined from different portions of brain were unremarkable. Representative sections examined from multiple grey white nodules of heart, lung and kidney showed foci of infiltration by adenocarcinoma. (figure 4 & 5) Sections examined from piece of spleen showed congestion only.



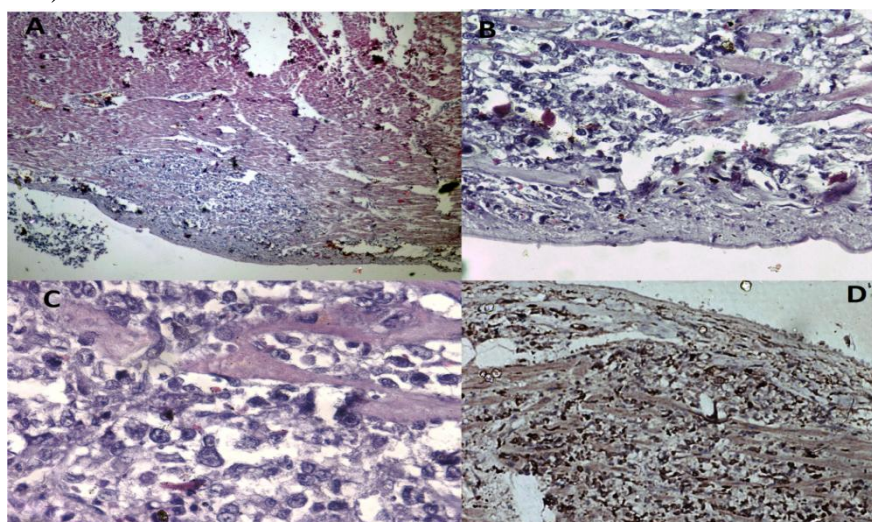
**Figure 1.** A) Gross external surface of heart- normal, B) two grey white nodules in heart wall (arrow), C) grey white nodule in lung (arrow), and D) Grey white nodule in kidney (arrow).



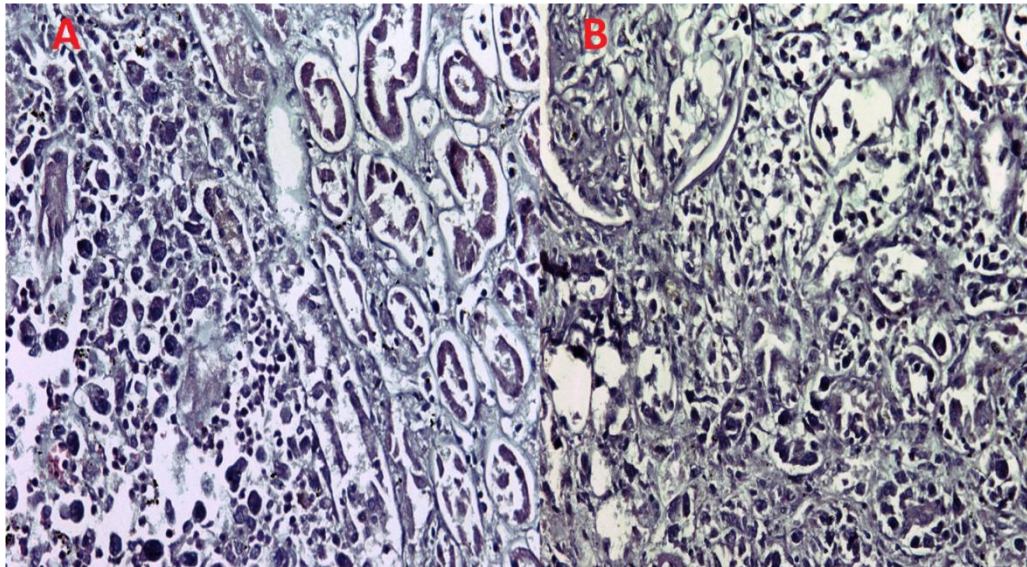
**Figure 2** A) Gall bladder mass with perforation (arrow) and metastatic nodules on liver surface. B) Cut surface of gall bladder- tumor mass (arrow) with liver metastatic nodules. C) metastatic nodules-Liver. (arrows)



**Figure 3** A) Gall bladder mass – adenocarcinoma. (H&E, 20X), B) tumor infiltrating through gall bladder wall, C) positive immunostain with cytokeratin (CK) in tumor cells. (IHC, 20X), and D) tumor infiltrating in liver tissue. (H&E, 20X).



**Figure 4** H& E sections- tumor metastasis in heart wall with A) 10X, B) 20X, C) 40X magnification, and D) positive immunostain with cytokeratin (CK) in tumor cells.(IHC, 20X).



**Figure 5** Tumor (adenocarcinoma) infiltrating in renal parenchyma A) &B)- H&E,20X .

### Discussion

Cardiac metastasis was found in 3.4% of the general autopsies and in 11.6% of autopsies in known cancer patients with disseminated disease.<sup>3,4</sup> Solitary metastases to the heart are very rare. Therefore suspicious of cardiac metastasis, are increasingly taken into account during post-mortem examinations even in absence of clinical symptoms of cardiovascular disease.<sup>5</sup> Cardiac metastases predominantly occur in patients in the sixth and seventh decade of life with advanced stage of various malignancies. There is no sex preference for cardiac involvement.<sup>4,5</sup>

Primary tumors of the heart are rare, occurring at a frequency of 0.02% in pooled autopsy series.<sup>5</sup> Histologically, three quarters of primary heart tumors are benign and almost half of them being myxomas. Secondary or metastatic heart tumors occur comparatively more frequently, with an incidence at least 100 times higher than primary tumors of the heart. The right side of the heart as compare to left side is more commonly involved by metastasis. The factors postulated for the infrequency of cardiac metastasis are the strong action of the myocardium, metabolic peculiarities of striated muscle, rapid blood flow through the heart, and lymph flow moving away from the heart.<sup>6</sup>

Thus, like primary tumors of the heart, metastases may imitate valvular heart disease or cause

cardiac failure, ventricular or supraventricular heart rhythm disturbances, conduction defects, syncope, embolism, or, quite often, pericardial effusion. Not infrequently, cardiac tumor invasion contributes to the mechanism of death in affected patients.<sup>5</sup>

In principle, every malignant tumor can metastasize to the heart. Till date, metastases from tumors of central nervous system have not been seen with cardiac metastases. Malignant tumor can metastasize to the heart by four different pathways including lymphatic, hematogenous, direct extension, and transvenous extension via the superior or inferior venacava. Pericardium is most commonly involved than myocardium (second most common), and endocardium. Sites of metastases in heart depend on the preferential metastatic pathway of the tumor of origin. Lymphatic and hematogenous spread tends to give rise to pericardial and myocardial metastases respectively. Malignant melanoma, lymphoma, leukemia, soft tissue and bone sarcoma usually spread hematogenously. Only rarely endocardial tumor deposits found.<sup>2,5</sup>

Malignant melanomas represent the tumor with the highest rate of cardiac metastases due to higher hematogenous spread.<sup>3</sup> Carcinomas of lung and breast are the most common tumors affect the pericardium due to higher lymphatic metastatic pathway. Cardiac metastases of

infradiaphragmatic tumors are markedly less frequent. Renal cell carcinoma, hepatocellular carcinoma, leiomyoma of the uterus, Wilm's tumor, pheochromocytoma and adrenal cortex carcinoma have been observed to extend through the inferior, and carcinoma of the lung and thyroid gland through the superior vena cava into the right atrium.<sup>2,5</sup>

Since the clinical picture is chiefly dominated by generalized tumor spread, cardiac metastases usually remain clinically silent, due to small metastatic tumor foci. Localization of metastases in the heart usually determines the symptomatology. Pericardial involvement can lead to pericarditis with pericardial effusion. Massive pericardial effusion lead to hypotension, dyspnea and peripheral cyanosis, pulsus paradoxus, and venous congestion. In cases of a slow increase in pericardial fluid, it can remain asymptomatic. Other causes of heart failure in patients with cardiac metastases may be due to massive myocardium involvement, intracavitary growth with obliteration of heart chambers or valvular heart disease.<sup>2,5</sup>

Cardiac metastases can provoke atrial and ventricular heart rhythm disturbances, as well as conduction defects. Syncope and sudden death have been reported. Arrhythmia in patients with cardiac metastases is usually the result of multiple factors such as hypoxemia or altered electrolyte concentrations, or secondary to tumor involving autonomic fibers or coronary arteries. The sudden occurrence of an arrhythmia in a patient with a known malignancy suggests the possibility of metastatic involvement of the myocardium. Myocardial infarction can be the result of compression of a coronary artery by tumor mass or due to invasion.<sup>4,5</sup>

Diagnosis of cardiac metastasis with any physical or laboratory examinations is difficult in diffuse tumor disease. Intracavitary tumors which lead to systolic and or diastolic murmurs usually appear as filling defects under radionuclide or contrast medium angiography. These techniques are usually avoided due to possibility of embolism of

tumor fragments or tumor adherent thrombotic material. Sometimes in individual cases, diagnosis of intracardiac metastasis can be established by catheter biopsy, usually under fluoroscopic guidance. With massive pericardial effusion, heart sounds often diminish. Electrocardiographic recordings may document arrhythmias, or conduction defects. Usually non-specific ST-segment changes are found. Supplemental diagnostic imaging methods include computer tomography and magnetic resonance imaging.<sup>4</sup>

### Conclusion

It is necessary to suspect cardiac metastases in a patient with advanced cancer even in absence of cardiac symptoms and when the patient develops sudden clinical deterioration hemodynamically. Therefore all the cases would need specific attention to rule out cardiac metastasis on autopsy.

**Source of Funding-** None.

**Conflict of Interest-** All authors state that there are no conflicts of interests.

### References

1. Tamura A, Matsubara O, Yoshimura N, Kasuga T, Akagawa S, Aoki N. Cardiac metastasis of lung cancer: A study of metastatic pathways and clinical manifestations. *Cancer*. 1992;70:437-42.
2. Bussani R, De- Giorgio F, Abbate A, Silvestri F. Cardiac metastases. *Clin Pathol* 2007;60:27-34.
3. Tas F, Mudun A, Kirma C. Cardiac involvement in melanoma: A case report and review of the literature. *J Can Res Ther*. 2010;6:359-61.
4. Chiles C, Woodard PK, Gutierrez FR, Link KM. Metastatic involvement of the heart and pericardium: CT and MR imaging. *Radiographics*. 2001;21:439-49.
5. Reynen K, Kockeritz U, Strasserb RH. Metastases to the heart. *Ann. Onc*. 2004;15: 375-81.
6. Dasappa L, Saldanha SC, Kuntegowdanahalli LC, Jacob LA, Babu

G, Babu MS, et al. An unusual presentation of cardiac metastasis in breast cancer. Clin Cancer Investig J. 2016;5:89-91.