



A Prospective Study done to Delineate the Parameters of Sub Chorionic Hematoma (Ultrasound detected) which Correlate with Favourable Pregnancy Outcome. do IVF pregnancies show a higher incidence of Subchorionic hematoma?

Authors

Dr Nidhi Gupta¹, Dr Akanksha², Dr Kaustubh Srivastav³

¹Professor, Dept of Obstetrics and Gynaecology, S.N. Medical College Agra, U.P. India

²Assistant Professor, Dept of Obstetrics and Gynaecology, S.N. Medical College Agra, U.P. India

³Consultant Dept of Obstetrics and Gynaecology, TAURUS HOSPITAL Kanpur U.P. India

Institution where the study was done

Malhotra test tube baby and Maternity Center and Global

Rainbow Hospital Pvt Ltd., Agra-282003, U.P. India

Corresponding Author

Dr Nidhi Gupta

4/16 A Bagh Farzana Agra -282002, Uttar Pradesh, India

Email: dr.nidhi_gupta@rediffmail.com

Abstract

Introduction: Intrauterine hematomas are common ultrasonographic findings that may be associated with first-trimester bleeding. Serial ultrasonography can detect haematoma characteristics and progression which may have predictive value for a favourable pregnancy outcome.

Material and Methods: This was a prospective study involving pregnant women of 14 weeks or less attending antenatal clinic in Malhotra test tube baby and Maternity centre and Global Rainbow hospital Pvt. Ltd. Agra with chief complaints of vaginal bleeding. 788 cases were screened from Jan 2016—Jan 2018, subchorionic haematoma was identified in 97 cases and these were followed up with serial sonograms till 24 weeks of gestation. The outcome was recorded in terms of haematoma volume, size, site, fetal cardiac activity, relative size with respect to gestational sac, symptom regression and outcome. Results were analyzed.

Results: 61% women with subchorionic hematoma belonged to the age group 21-30 years with a mean gestational age of 9.2 weeks. IVF conceived pregnancies demonstrated a much higher incidence (22.78%) which is almost double that observed in non-IVF pregnancies (9.68%). 57.7 % of cases had an anterior location of haematoma and the mean volume being 30 ± 9.2 cc. 52.2% cases showed progressive decrease in size with complete resolution of haematoma while 11% had an increase in size. Cases with relative size <20% mostly had a favourable outcome and prognosis worsening with relative size >50%.

Conclusion: Assisted reproductive techniques pose a higher risk for incidence of subchorionic haematoma. A relative size of haematoma >50% is significantly associated with an increased risk of spontaneous abortion. Advanced maternal age and an early gestational age at diagnosis may be considered a risk factor for poor outcomes. Late first or second-trimester bleeding also worsens the prognosis. Position or absolute size did not correlate well to the outcome.

Keywords: Subchorionic hematoma, prognosis, first trimester bleeding.

Introduction

A patient is faced with extraordinary anguish when vaginal bleeding accompanies her pregnancy causing anxiety about the outcome of the pregnancy for a couple, and a diagnosis of subchorionic haematoma is still an enigma as the obstetricians are as yet unable to give a satisfactory answer as to the chances of a favourable pregnancy outcome.

5% to 25% of all pregnancies are complicated by first-trimester bleeding¹ and only half of the women who experience vaginal bleeding are able to continue their pregnancies. Possible causes of bleeding which can be identified on ultrasonographic examination include subchorionic haemorrhage, embryonic demise, anembryonic pregnancy, incomplete abortion, ectopic pregnancy, and gestational trophoblastic disease. Other non-obstetric causes of bleeding like cervicitis, vaginitis, cystitis, genital trauma, cervical cancer, polyps and haemorrhoids can be identified on careful history and examination.²

Ultrasound has proven to be a valuable tool in providing a definitive diagnosis as to the cause of vaginal bleeding in first trimester but there is not much clarity on the prognostication. Ultrasound examination is crucial in establishing Intra-Uterine Pregnancy and early pregnancy failure and to exclude other causes of bleeding, such as ectopic pregnancy and molar pregnancy.³

One of the sonographic features used in the evaluation of fetal viability in early pregnancy is the presence of subchorionic hematoma, an entity put forth initially by Mantoni and Pederson in 1981⁴. The exact aetiology of intrauterine hematomas remains unclear but pre-existing medical conditions, certain autoimmune diseases, and immunological factors have been implicated.^{5,6,7}

Over the years it has been established in various studies that presence of subchorionic haemorrhage puts a pregnancy at a higher risk of abortion but the available clinical methods do not throw light on the status of gestation whether the fetus is salvageable by conservative treatment or it has

undergone irreparable damage requiring evacuation of uterine contents.

The present study was conducted in the Malhotra test tube baby and Maternity centre and Global Rainbow Hospital Pvt. Ltd. with the aim of evaluation of patients with first trimester bleeding and ultrasound proven Subchorionic haematoma and to delineate the parameters of sub chorionic hematoma namely haematoma volume, site and haematoma size relative to gestational sac and chalk out a possible predictive relationship to pregnancy outcome.

Material and Methods

This was a prospective study including antenatal cases of gestational age less than 14 weeks, presenting with vaginal bleeding in Malhotra test tube baby and maternity centre and Global Rainbow hospital Pvt Ltd, Agra during the study period (January 2016 to Jan 2018). Women who agreed to participate in the study completed a written informed consent form.

Inclusion criteria

- An intrauterine live pregnancy
- Gestational age between 5 and 14 weeks
- A crown-rump length of greater than 4 mm
- And the existence of cardiac activity

Exclusion criteria

- nonviable or nonvisible embryos
- pathologic features, including fibroids, polyps, and uterine malformations
- history of abortifacient intake
- those who underwent elective termination of pregnancy

Methods

Antenatal patients presenting with vaginal bleeding between 5 and 14 weeks' gestation underwent routine antenatal examination.

A detailed obstetric history, physical examination and ultrasonographic assessment was undertaken with emphasis on crown-rump length, gestation sac characteristics (gestational sac diameter, regularity, turgidity, yolk sac) cardiac activity,

presence or absence of hematoma, position of the hematoma (subchorionic/retroplacental/both), location of the hematoma (anterior/posterior/fundal/corpus) size of hematoma relative to gestational sac diameter.

Local examination, per abdominal examination and per speculum examination was carried out to rule out causes of bleeding apart from subchorionic haematoma.

All routine investigations were carried out and documented.

Treatment

All patients included in the study were subjected to same treatment

- Bed rest⁸
- Folic acid supplementation⁹
- Progesterone therapy¹⁰⁻¹³

Follow up

All patients with live fetuses with continued fetal heart activity and subchorionic hematoma were followed up at seven- to ten-day intervals initially till the bleeding resolved.

And further repeated sonograms were obtained at an interval of two weeks until

- The subchorionic bleeding resolved and the pregnancy continued,
- Or until the pregnancy ended in abortion
- Or upto 24 weeks of gestational age whichever was earlier.

Observations

Out of the 788 patients screened over the study period 158 were IVF pregnancies and 630 were spontaneous conceptions. Subchorionic haematoma was detected in 97 cases out of which 5 patients had absent cardiac activity at presentation hence were not followed up.

220 patients were found to have a live fetus but absence of any subchorionic haemorrhage. After counseling and informed consent the patients were divided into two groups-

- I. **Group A-** subchorionic haematoma present with a viable fetus
- II. **Group B-** subchorionic haematoma absent with a viable fetus

After accounting for a loss of follow up, at the time of analysis 90 cases of Group A and 200 cases of Group B were available.

Results

Cases in both the groups matched well regarding age, parity, marital status, educational status and socio-economic status. Mean gestational age of haematoma group was 9.2 weeks and study group was 7.4 weeks. In haematoma group the mean duration of bleeding at presentation was 1056.2+/-645.68 minutes and 1043.2+/-643.44 minutes in control group. (Table 1).

Both groups were comparable with regard to maternal age, smoking history, and medical and reproductive history. (Table 2)

The incidence of subchorionic haematoma in population presenting with features of threatened abortion was calculated to be 97 of 788 (12.30%). IVF conceived pregnancies demonstrated a much higher incidence of subchorionic haematoma (22.78%) which is double than that observed in non-IVF pregnancies (9.68%). Frozen-thawed embryo transfer, parity of 1 or greater, and blastocyst transfer may be contributing factors in IVF patients.

90% cases of the study group were of gestational age less than 10 weeks at initial presentation and 10% cases of study group were of gestational age 10-14 weeks.

75.5% gestational sacs in the study group were good turgid with regular outline. 71.1% showed a normal yolk sac, 20% condensed yolk sac and 8.8% depicted a very large yolk sac on ultrasonography. (Table 3)

52% patients presented with a subchorionic haematoma volume less than 20cc, followed by 31% cases of haematoma volume between 20 to 50cc and 17% cases with haematoma volume more than 50cc at first visit.

The mean volume of subchorionic haematoma in this study was 30+9.2cc.

When the relative size of the gestational sac was observed it was seen that 82.2% of cases continued pregnancy with sizes <20%, 92.6% with

volume between 20-50% and 83.4% with volume >50%. While comparing the volume of subchorionic hematoma at first visit the best outcome of pregnancy continuation was seen where volume was <50%. (Table 4)

Majority of subchorionic haematoma were anteriorly located (55.5%), followed by posterior (18.8%), fundal (10%) and isthmic (15.7%) in location. 51.1% of women with anterior subchorionic hematoma continued pregnancy whereas 4.4% anterior and posterior located hematomas showed adverse outcome. No significant association could be made out in the results on basis of site of haematoma and pregnancy outcome. (Table 4)

Rest and progesterone therapy were found to be very effective in symptom regression with 52% patients reporting complete resolution of complaints by 3rd follow up visit (Fig.1). 13.2% patients with severe symptoms heavy vaginal bleeding with abdominal pain had unfavourable outcomes. Vaginal bleeding and abdominal pain were not significantly correlated with pregnancy outcome.

By the 3rd follow up visit, a majority 52% patients showed complete resolution of haematoma, 32%

cases demonstrated a decrease in size of subchorionic haematoma but 11% cases showed an increase in haematoma size.

A spontaneous abortion rate of 13.2% in haematoma population was observed which is comparable to previous studies. Rate of spontaneous abortion was found to be 6% in control group which is comparatively lower. This shows that the presence of subchorionic haematoma itself puts a pregnancy at higher risk of miscarriage compared to general population.

In our present study we have observed 21.8% and 16.6% is the abortion rate in cases presenting with gestational age less than 10 weeks and more than 10 weeks respectively.

Although an absolute size of haematoma >60cc appeared to be associated with a uniformly adverse outcome in our study, but in most of the studies, including ours, the estimated volume of the hematoma did not correlate with the outcome of the pregnancy when statistically analysed.

Subchorionic haematoma with a relative size of haematoma <50% were found to have a better prognosis compared to those having a relative size of haematoma >50% but the result is statistically insignificant.

Table 1 General Characteristics of the Women in the two Groups

General Characteristics	Group A	Group B
Mean Age	25.4±5.31	24.8±5.27
Mean Parity	I	I
BMI	27.7	28.6
Socioeconomic status	Class II	Class II
Mean Gestational Age	9.2 weeks	7.4 weeks
Mean Duration of Bleeding	1056.2±643.68 min	1043.2±643.44min

Table 2 Associated Obstetric and Medical Complicating Factors

	Group A		Group B	
	Number	Percentage	Number	Percentage
Maternal age >35 yrs	31	34%	73	36.7%
History Of Previous Termination Of Pregnancy	27	30%	78	38.9%
Previous spontaneous abortion	19	21%	49	24.4%
IVF conception	55	61%	80	40%
Previous perinatal death	19	21%	42	21.1%
Smoking/ tobacco consumption	15	17%	36	17.8%
History of Chronic hypertension	14	16%	26	13.3%
History of Gestational diabetes	5	5%	10	5.5%

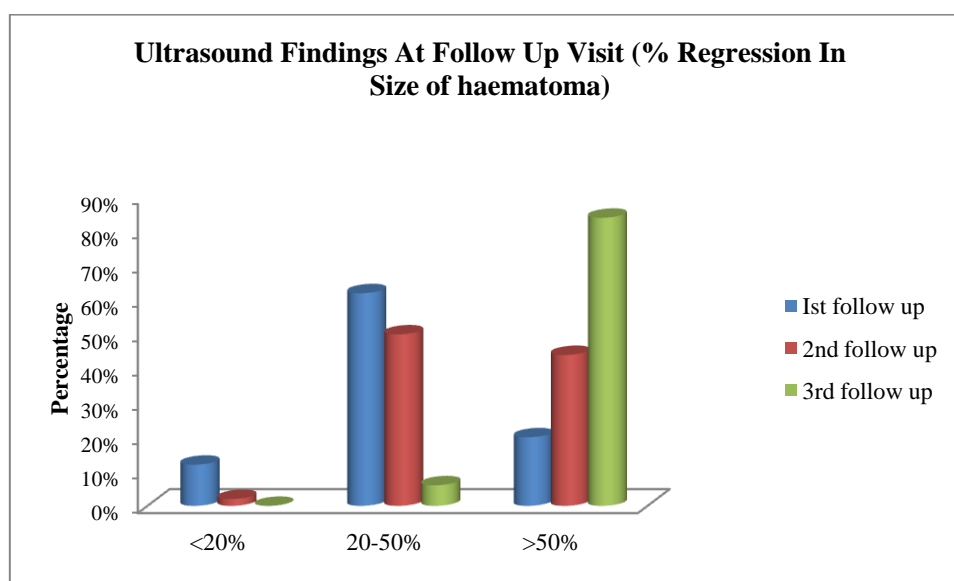
P value= 0.22

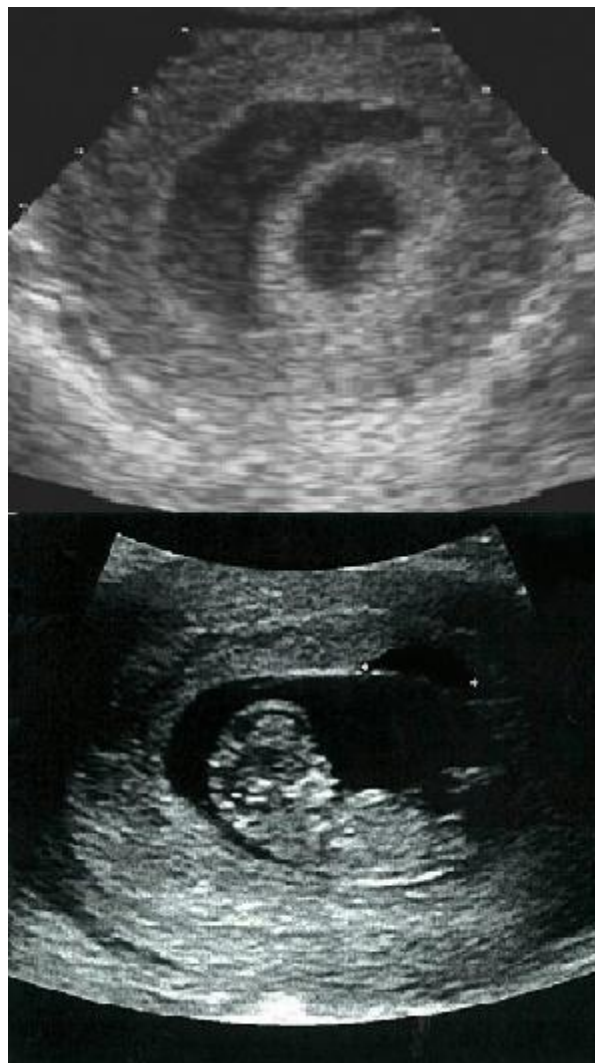Table-3 Distribution of Cases According to Characteristics of Gestational Sac in the Study Group

Gestational Sac Pattern		Study Group	
		No	%
Turgidity	Good	68	75.5%
	Poor	22	24.5%
Regularity of sac	Regular	68	75.5%
	Irregular	22	24.5%
Yolk sac	Normal	64	71.1%
	Condensed or ill defined	18	20%
	very large	8	8.8%

Table 4 Outcome with Respect to size of Subchorionic Haematoma with Relation to Gestational Sac Size, Absolute Volume And Site

		Normal outcome (Pregnancy continued)		Adverse outcome (Abortion)		p-value
		Number	%	Number	%	
Relative size	< 20%	37	82.2%	8	17.8%	>0.5
	20-50%	25	92.6%	2	7.4%	
	>50%	15	83.4%	3	16.6%	
Volume (in cc) of Subchorionic haematoma at first visit	<20 cc	39	84.8%	7	15.2%	0.6
	20-50 cc	27	96.4%	1	3.6%	
	>50 cc	11	68.7%	5	31.3%	
Site	Anterior	46	51.1%	4	4.4%	0.1
	Posterior	13	14.5%	4	4.4%	
	Fundal	6	6.7%	3	3.3%	
	Corpus	12	14.5%	2	1.1%	

**Figure 4** Ultrasound findings at follow up (% Regression in haematoma size)



Ultrasound images showing progressive decrease in haematoma size at follow up from top to bottom at 7 weeks and 12 weeks of gestational age respectively

Discussion

Subchorionic Hematoma: A Review

A subchorionic hematoma is caused by hemorrhage from marginal veins and leads to a separation of the chorionic membrane from the decidua at the edge of the placenta (Donald school textbook of ultrasound in obstetrics and gynecology). Small hematomas on the surface of the placenta (subamniotic hemorrhage) are common at 18 to 20 weeks on ultrasound, but hemorrhages identified beneath the placenta, at the edge of the placenta, or behind an isolated area of the fetal membranes is of greater significance.

Subchorionic hematoma was first described by Mantoni and Pederson in 1981 as “an echo-free area between the membranes and the uterine wall. The echo-free area was found in patients at 11 to 20 weeks gestation who had a live fetus and was believed to represent blood. Seven smaller

hematomas of less than 35 ml gradually disappeared and the pregnancies continued until term. Three patients who had hematomas of more than 50 ml subsequently aborted or had a premature delivery.” Since then innumerable studies have been done on the same till date which focus on it’s clinical significance. Subchorionic bleeds increase the chances of pregnancy complications, particularly miscarriage and preterm delivery, a possibility of fetal growth problems prompting early delivery with potential for adverse neurologic and physical outcomes. It has been suggested that a localized accumulation of blood causes mechanical uterine irritation and therefore stimulates contractions¹⁴⁻¹⁵. Another possible mechanism for the preterm uterine activity is bacterial colonization of the hematoma and endotoxin release with subsequent prostaglandin synthesis.¹⁶

Early studies of subchorionic hemorrhages reported incidences that varied between 4% and 22%. Sandor Nagy et al¹⁷ calculated a net incidence of subchorionic hematoma to be 3.1% in the general obstetric population but this figure is much higher in high risk cases as evidenced by other studies concentrating on patients with threatened abortion, 20 % (Goldstein 1983)¹⁸, 4-48% (Pearlstone 1993)¹⁹ and 18% (Adelusi 1996)²⁰

Possible reasons for the discrepancy in these rates include variable and highly selective patient populations, a wide range of gestational ages, and lack of a standard definition of intrauterine hematomas.

Correlation of Volume of Hematoma with Pregnancy Outcome

Published opinions on the clinical significance of the volume of intrauterine hematomas are controversial. Several authors have attempted to relate the size of the hematoma directly to pregnancy outcome and to determine whether this factor has predictive significance. In most of the studies, including ours, the estimated volume of the hematoma did not correlate with the outcome of the pregnancy. Perhaps it is the presence or absence of a hematoma as a marker of the integrity of placentation and not its size that is important. Adelusi in 1996 described his experience with subchorionic hematoma averaging 20 ml in size, and failed to find a significant relation between hematoma size and abortion rate. Similar findings were echoed by a study by Jouppila P²¹. But in 2012 Kyser et al²² conducted a meta-analysis which, reported a 93 %abortion rate with a hematoma volume greater than 60-ml. Saurbrei and Pham also found that for volumes less than 60 ml the outcomes tended to be favourable, concluding that subchorionic hematoma is a significant factor in abortion with relation to the volume of hematoma.

Correlation of Relative Size of Hematoma to Pregnancy Outcome

The significance of relative volume of the hematoma (volume of hematoma divided by volume of gestational sac) was explored by Sauerbrei and Pham²³ in 1986. For a relative volume less than 0.4, the outcome tended to be favorable. The relative volume of the hematoma was noted to be a major prognostic factor related to pregnancy outcome preceded in significance by the absolute volume of the hematoma.

Correlation of Site of Hematoma to Pregnancy Outcome

Mandrizzato GP²⁴ in 1989 observed that fetal growth retardation seemed to be increased in cases of subchorionic hematoma, especially when the placenta was located on the posterior uterine wall.

Sándor Nagy, in 2003 concluded that the abortion rate with cervical localisation of the hematoma is significantly lower and with posterior localisation of the hematoma is significantly higher.

Lucie Morin *et al*²⁵ in June 2005 noted that most hematomas associated with abortion were found in the corpus or fundus of the uterus, not in the supra cervical area (P = 0.03).

Conclusion

First trimester bleeding is an important predictor of adverse foetal outcomes and a diagnosis of subchorionic haematoma is a cause of much concern both to the mother and the obstetrician.

From the above study the incidence of subchorionic haematoma in population presenting with features of threatened abortion was calculated to be 11.74%. Net rate of spontaneous abortion in haematoma group was found to be much higher than that of control population. We can conclude that presence of subchorionic haemorrhage is significantly associated with increased risk of spontaneous abortion.

Moreover an early gestational age at diagnosis of subchorionic haematoma was associated with higher abortion rate (21.8% versus 16.6%) and may be considered a risk factor for poor

outcomes. However relief in symptoms of threatened abortion is a welcome sign. This was found to be statistically significant on analysis.

Lower haematoma volumes <20 cc are predictive of positive pregnancy outcomes whereas an absolute haematoma volume >60cc was found to be associated with uniformly poor prognosis. This result did not come out to be statistically significant (p-value= 0.6).

Cases with subchorionic haematoma with a relative size of haematoma <50% were found to have a better prognosis compared to those having a relative size of haematoma >50% but the result is statistically insignificant (p-value>0.5).

There was no significant correlation between the site of haematoma and pregnancy outcome.

IVF conceived pregnancies demonstrated a much higher incidence of subchorionic haematoma (22.78%) which is double than that observed in non-IVF pregnancies (9.68%). Frozen-thawed embryo transfer, parity of 1 or greater, and blastocyst transfer may be contributing factors in IVF patients.

But we must acknowledge the limitations of our sample and duration of study and suggest a larger study with more frequent follow up visits with emphasis on follow up till ultimate outcome-abortion or delivery, to refuse and reaffirm effectiveness of subchorionic haematoma as a predictor of outcome in cases presenting with threatened abortion.

Bibliography

1. Juliana Leite, Pamela Ross, A. Cristina Rossi, Philippe Jeanty, Prognosis of Very Large First-Trimester Hematomas, J Ultrasound Med 2006; 25:1441–1445
2. Hertig AT, Livingstone RG. Spontaneous, threatened and habitual abortion: their pathogenesis and treatment. N engl J Med 1944;230-797-806.
3. Jauniaux E, Johns J, Burton GJ, (2005): The role of ultrasound imaging in diagnosing and investigating early pregnancy failure. Ultrasound Obstet Gynaecol; 25:613–624.
4. Pedersen JG, Mantoni M. Large intrauterine hematoma in threatened miscarriage. Frequency and clinical consequences. Br J Obstet Gynaecol 1990;97:75±7. Mantoni M, Pedersen JF. Intrauterine haematoma: An ultrasonic study of threatened abortion. Br J Obstet Gynaecol 1981;88:47–51.
5. Arthur CI, Hyginus UE, Mgbor SO, (2003): Sub-chorionic Haematoma: Has it a prognostic relevance in Pregnancy Outcome? Journal of College Medicine Volume 8, No 1
6. Alijotas J, Izquierdo M, Serra B, Cusido MT, Ribera M, Carrera JM, (2003). Antinuclear autoantibodies, complement level, hypergammaglobulinemia and spontaneous intrauterine hematoma in pregnant women. Am J Reprod Immunol; 50:1– 6.
7. Baxi LV, Pearlstone MM, (1991). Subchorionic hematoma and the presence of autoantibodies. Am J Obstet Gynecol; 165:1423– 4.
8. Heller DS, Rush D, Baergen RN, (2003). Subchorionic hematoma associated with thrombophilia: report of three cases. Pediatr Dev Pathol; 6:261– 4
9. Giobbe M, Fazzio M, Boni T. Current role of bed-rest in threatened abortion. Minerva Gynecol 2001;53:337-40
10. Igor Hudic, Zlatan Fatusic. Progesterone induced blocking factor (PIBF) and Th1/Th2 cytokine in women with threatened spontaneous abortion. J. Perinat. Med. 2009;37:338-42.
11. Sanchez-Ramos L, Kaunitz AM, Delke I. Progestational agents to prevent preterm birth: a meta analysis of randomized controlled trials. Obstet Gynecol. 2005; 105: 273-9.
12. Choi BC, Polgar K. Xiao L, Hill JA. Progesterone inhibits in vitro embryotoxic

- Thi cytokine production to trophoblast in women with recurrent pregnancy loss. Hum Reprod. 2000;15:46-59.
13. Sfakianki A, Norwitz M. Mechanisms of progesterone action in inhibiting prematurity. J Matern Fetal Neonatal Med. 2006. P;19:763- 72.
 14. Kaufman AJ, Fleischer AC, Thieme GA, Shah DM, James AE. Separated chorioamnion and elevated chorion; sonographic features and clinical significance. J Ultrasound Med 1985;4:119-125
 15. Chasen,S.:Prognostic factors associated with antenatal subchorionic echolucencies. American Journal of Obstetrics and Gynecology 2003;1989;994-6.
 16. Stabile I, Campbell S, Grudzinskas JG. Ultrasonic assessment of complications during first trimester of pregnancy.Lancet 1987;2(8570):1237–40.
 17. Nagy S, Bush MC, Stone J, Lapinski RH, Gardó S. Clinical significance of subchorionic and retroplacental hematomas detected in the first trimester of pregnancy. Obstet Gynecol 2003; 102: 94-100
 18. Goldstein SR, Subramanyam BR, Raghavendra BN, Horii SC, Hilton S. Subchorionic bleeding in threatened abortion: Sonographic findings and significance. AJR Am J Roentgenol 1983;141:975–8.
 19. Pearlstone M, Baxi L. Subchorionic hematoma: A review. Obstet Gynecol Surv 1993;48:65–8
 20. Babatunde Adelusi, Borlum KG, Thomsen A, Clausen I, Eriksen G. Longterm prognosis of pregnancies in women with intrauterine hematomas. Obstet Gynecol 1996; 74:231–3.
 21. Morgan, Jouppila P. Clinical consequences after ultrasonic diagnosis of intrauterine hematoma in threatened abortion. J Clin Ultrasound 1985;13:107–11.
 22. Kyser, K L. ‘Meta-analysis of subchorionic hemorrhage and adverse pregnancy outcomes’ Proc Obstet Gynecol. 2012
 23. Sauerbei EE, Pham DH. Placental abruption and subchorionic hemorrhage in the first half of pregnancy: US appearance and clinical outcome. Radiology 1986;160:109–12
 24. Mandruzzato GP, D’Ottavio G, Rustico MA, Fontana A, Bogatti P. The intrauterine hematoma: Diagnostic and clinical aspects. J Clin Ultrasound 1989;17:503–10.
 25. Morin L, Van den Hof MC. Diagnostic Imaging Committee, Society of Obstetricians and Gynaecologists of Canada. Ultrasound Evaluation of First Trimester Pregnancy Complications. J Obstet Gynaecol Can.2005;27:581–91.