



A Clinical study on Benign Breast Diseases

Authors

Dr Jayvarmaa. R¹, Dr J. Kabalimurthy², Dr C. P. Mohan³

^{1,3}Post Graduate, Department of General Surgery, Rajah Muthiah Medical College, Chidambaram

²Professor, Department of General Surgery, Rajah Muthiah Medical College, Chidambaram

Corresponding Author

Dr Jayvarmaa. R

No. 218, PG Men's Hostel, Annamalai Nagar, Annamalai University, Chidambaram – 608002

Ph No: 9976813400. Email: drjai92@gmail.com

Abstract

Background: *The need for study is to analyze the spectrum of benign breast disease with respect to age, sex, mode of presentation, clinical features and management.*

Methods: *The study was conducted among 150 patients who were diagnosed to have various forms of Breast Diseases that are found to be benign in nature and admitted at Rajah Muthiah Medical College Hospital, Chidambaram from October 2016 to September 2018. Diagnosis is made by doing careful clinical assessment, FNAC or core biopsy and ultrasonography or mammography. Surgery was done whenever necessary. The incidence of variable benign breast diseases and clinical features were compared and evaluated.*

Results: *Out of the 150 patients who were studied, 142 patients who presented with breast lumps and fibroadenoma, accounted for 60% of the cases, which was the highest number of patients. Fibroadenosis accounted 19.3% of the cases. Fibrocystic changes and breast abscesses made 1.3% and 4.6% cases respectively. Most patients presented with complaints of a lump in the breast (56%), pain (16%), or a combination of both (38.6%). 82 patients had a right sided lesion and 48 has left side lesion. Bilateral disease was present in 20 patients. The upper outer quadrant was more involved and lower medial quadrants were least commonly affected. Of 90 cases of fibroadenoma, 86 were operated upon by excision. 15 patients with fibroadenosis, where the diagnosis was doubtful were operated.*

Conclusion: *Benign breast diseases are common in female patients and fibroadenoma is the commonest of them all. Triple assessment gave a firm diagnosis and it eliminates unnecessary anxiety from the patients about breast cancer or any other serious illness.*

Keywords: *Breast lump, Fibroadenoma, Fibroadenosis, Fibrocystic disease, Breast abscess, FNAC, Mammogram.*

Introduction

Most breast complaints are benign in nature. They have been known to affect both males and females. Unlike breast cancer, benign breast diseases have often been difficult to understand, in

part due to variety of names that have been used to describe the various conditions. Up to 30% of women will suffer from a benign conditions requiring treatment at some time in their lives.

There are many types of benign breast diseases, these can be classified according to the predominant symptoms – pain, lumps, nipple problems and infections. The pathogenesis involves disturbance in breast physiology extending from an extreme normality to well defined disease process. This includes ANDI, Duct ectasia, Galactocele, Gynaecomastia.^[1-8]

The main problem from women's patient of view is fear that such a lump may be a cancer. It is now easier to exclude cancer with the development of diagnostic aids such as mammography, ultrasonography and fine needle aspiration cytology.^[9]

So, the need for study is to analyze the spectrum of benign breast disease with respect to age, sex, mode of presentation, clinical features and management.

Materials and Methods

The study was done in our hospital under the department of general surgery during the period between October 2016 and September 2018. This study was a prospective and retrospective study which involved newly admitted patients and also from the records. Totally 150 patients were studied during this period. Patients who presented with lump or pain in the breast along with additional symptoms related to benign breast diseases were evaluated with various investigations and studied. From the records, the patients diagnosed with various types of benign breast diseases were studied. Mostly the patients between age group 16 – 60 years were studied. Male patients with lump in the chest suggestive of gynaecomastia were also studied.

The patients admitted were evaluated with detailed clinical history, thorough examination. Then it was proceed with routine investigations which included hemogram, random blood sugar, renal function test, HbsAg, HIV, fasting lipid profile. Mammogram, USG breast and Fine needle aspiration cytology were done for required situations. Surgery was advised as and when necessary and proceed with mostly excision

biopsy. Then the specimens were sent to histopathological examination and the results were documented.

Results and Discussions

Benign breast disease had been a frequent encounter among the general surgery department. The lack of knowledge among the patients about the disease and increased frequency of the occurrence of the disease makes the disease a serious entity. So, the need for study was to analyze the spectrum of benign breast disease with respect to age, sex, mode of presentation, clinical features and its management.

Incidence

The study group was comprised of 150 patients with benign breast disease. A spectrum of lesion was indentified with the commonest, being fibroadenomas followed by fibroadenosis. Fibroadenomas formed 60% of the cases, the firboadenosis 19.3%. The other benign lesions observed were cystosarcoma phyllodes, acute abscess, chronic abscess, tuberculous mastitis, antibioma, cysts, galactocele, gynaecomastia, traumatic fat necrosis, duct papilloma and mastalgia. Inflammatory conditions of the breast constituted 5.8% of the cases, and were in the form of 6 cases of acute abscess, 1 of chronicabscess, 1 case of granulomatous mastitis and 1 antibioma.

Table 1: Incidence

Diagnosis	Patients
Fibroadenoma	90
Fibroadenosis	29
Cystosarcomaphyllodes	4
Acute abscess	6
Chronic abscess	1
Granulomatous mastitis	1
Antibioma	1
Cysts	2
Galactocele	2
Gynaecomastia	5
Traumatic fat necrosis	-
Duct papilloma	2
Mastalgia	7

Age distribution

Fibroadenomas were of the most common benign lesion, forming 60% of the cases. They occurred in the age group of 15-25 years with the average age of incidence being 20 years. Fibroadenosis was the next common, with 19.3% incident, in the age group 30-40 years. Average age of incidence was 35 years. Of the 150 cases, the youngest patient was 15 years old, with a fibroadenoma. The oldest, a 66 years old woman hold fibroadenosis of the breast.

Table 2: Based on side

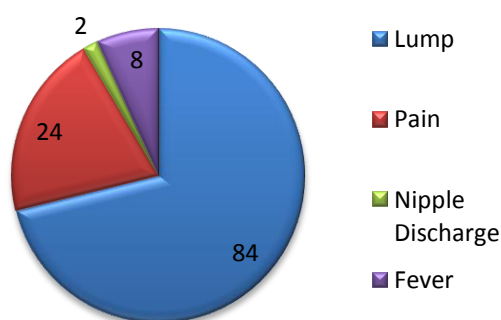
Side	Patients	%
Right	82	54.6
Left	48	32.0
Bilateral	20	13.3

Clinical presentation

Most patients presented with complaints of a lump in the breast, pain, or a combination of both. 84 of patients presented with a lump without any other complaint, 24 patients complained of pain alone and 40 patients complained of a lump with associated pain. 2 patients diagnosed later with duct papilloma presented with complaints of discharge from the nipple. Fever was present in patients with abscess and mastitis accounting for 8 patients.

82 patients had a right sided lesion and 48 has left side lesion. Bilateral disease was present in 20 patients. Quadrants involved varied, with the outer being more commonly involved than the inner quadrant. The upper quadrant was more involved similarly than the lower quadrant. The lower medial quadrants were least commonly affected.

Graph 1: Clinical presentation



Investigations

Investigations proved necessary for the diagnosis in 122 cases, while clinical examination alone proved sufficient in 28 cases. Mammography was done in 120 patients with lump in the breast of which 98 patients had benign diseases, mostly fibroadenoma and fibroadenosis. Reports for 4 patients suggested malignancy. For many patients, FNAC was suggested. FNAC was carried out in 92 cases, of which the results were confirmed to be similar to the histopathologic examination in 70 cases. Ultrasound was carried out in 21 patients where FNAC results were a cellular, inconclusive, or could not be relied on due to insufficient material and in patients with nonpalpable lesions. These patients were as follows -5 cases with fibroadenosis, 4 cases with mastalgia and 2 cases of breast cyst. Core needle biopsy was resorted to in patients where all investigations were inconclusive, as in cystosarcoma phyllodes, a patient with chronic abscess, Gnanulomatous mastitis and antibioma. The aim was to rule out malignancy

Treatment

Of 90 cases of fibroadenoma, 86 were operated upon by excision. 15 patients with fibroadenosis, where the diagnosis was doubtful were operated upon. Abscesses were incised and drained under antibiotic cover. 2 Duct papilloma cases, 2 cases of breast cyst were managed surgically.

Gynaecomastia patients were subjected to Websters operation. TB mastitis was confirmed by excisional biopsy and followed up by anti-tuberculous therapy with regular follow up after 6months. Healed lesions were found to be associated with improved general conditions of the patients.

Table 3: Surgeries Done

Surgery Done For	Patients	%
Fibroadenoma	86	57.3
Fibroadenosis	15	10.0
Breast Abscess	6	4
Duct Papilloma	2	1.33
Gynaecomastia	4	2.67

Benign breast diseases are at least 10 times more common than breast cancer in hospital clinics (Mansel 1992)^[10]. Currently malignant to benign ratios of 1:10 are seen in breast clinics (Barclay et al 1991). At the King's College Hospital Breast Clinic, a study was conducted on breast conditions and 80% of patients with breast symptoms, had benign diseases. In a case control study of benign breast diseases in Greater Boston in 1968-69, fibroadenoma was commonest and found during the second decade of life commonly in married nulliparae.

In India, however, although benign breast diseases have a high incidence, they have always been overshadowed clinically by breast cancer. In one series of 1031 benign breast disease cases, 971 were females and 60 males. Of the female patients, 752 had tumors and tumorous conditions, while 219 patients had infective lesions.

In the present study 150 patients were included, of whom 121 patients had tumors and 12 patients had infective conditions. Fibroadenomas were the commonest tumor accounting for 90 patients. Fibroadenosis was the next common lesion, making up 29 cases. There is a parallel to the study conducted by Khanna where 396 cases were fibroadenomas and 135 cases were of fibroadenosis. The Rangabashyam study conducted over 5 years also demonstrated fibroadenomas to be the commonest followed by fibroadenosis and inflammatory disease.^[11]

As far as inflammatory conditions were concerned, the present study involved 9 patients- 6 acute abscesses, 1 chronic abscess and 1 case of tuberculous granulomatous mastitis and 1 case of anti-bioma. The tuberculous mastitis patients had been diagnosed only after performing excisional biopsy, with clinical examination and other investigative procedure proving inconclusive. In the Khanna series, nonspecific mastitis, tuberculous mastitis, plasma cell mastitis and parasitic infections like Cysticercosis, were documented.^[12]

The results of the present study parallel the Rangabashyam series carried out in the same

region in 1983 where tuberculous mastitis, filariasis, and chronic abscess were recorded. Over the past decade, the pattern appears to have changed only with regard to filariasis which is less prevalent. Tuberculous mastitis remains relatively common. The incidence of fibroadenoma and fibroadenosis in the present study were similar to that of Rangabashyam et al.

Presenting complaints of the patients were mostly of lump alone, followed by lump and pain, with a minimal number complaining of pain alone. These varying attitudes of the patients to breast pain may explain the lower number of patients with mastalgia diagnosed in the Indian studies performed compared to Western studies, where the commonest breast symptom as such is mastalgia (Maddox 1989, Hughes 1989, Dixon et al 1994).

With respect to investigation, FNAC was the initial procedure of choice and was carried out in 126 of the study group. Contemporary evidence from a number of studies shows FNAC to be highly sensitive and even more specific in the diagnosis of benign lesions of the breast.

USG and Mammography

USG of the breast is valuable in differentiating solid from cystic lesions. In this study, ultrasound proved useful in confirming the diagnosis made of a cyst after FNAC produced fluid aspirate. Conservative management was then adopted. In patients below 30 years, where mammography is not useful where the FNAC has proved inconclusive, ultrasound can be used. Clinically suspicious cystic lesions can also be evaluated for features of malignancy.

The patients underwent mammography in this study, its usefulness was evaluated. Other studies though have reported mammography to be of value in women over 35 years where malignancy is suspected and women where no palpable lesion is present despite persistent breast complaints.

Conclusion

- 1) The age of the patients influenced the nature of benign lesions
- 2) Fibroadenoma (60%) was the most common, in the agegroup 15-25 years followed by fibroadenosis(19.3%) in the age group 25-35 years. Inflammatory lesions formed 5.8%.
- 3) Tuberculous mastitis, although very low in rates of incidence, continues to occur. Antituberculous therapy remains the mainstay of treatment, with surgery being the last resort.
- 4) The majority of patients presented with a lump about 56%; Next common was lump associated with pain 38.6%; only a minority complained of pain alone 16%. Fever contributed 5.3 %
- 5) The right breast was more commonly involved (54.6%), and the upper lateral quadrant most often involved.
- 6) FNAC was the most useful and cost effective investigation. Sensitivity= 89.6%, specificity = 87.8% and accuracy=94.2%
- 7) Ultrasound and mammography were additional tools to fine needle aspiration cytology and clinical.

Source: None

Reference

1. Gadd MA, Souba WW. Evolution and treatment of benign breast disorders. In: Bland KI, Copeland EM, editors. The breast: The comprehensive management of benign and malignant disease Vol. 1. 2nd ed. Philadelphia: Saunders WB; 1998; p 233-244.
2. Page DL, Simpson JF. Benign, high-risk and premalignant lesions of the breast. In: Bland KI, Copeland EM, editors. The breast. The comprehensive management of benign and malignant disease vol. 1. 2nd ed. Philadelphia: Saunders WB: 1998. p.191-210.
3. William DL. Common benign conditions of the breast, In: William DL, Spratt JS, eds. Cancer of the breast. 4th Ed. Philadelphia: W.B. Saunders company: 1995; p 87-115.
4. Management of Benign and malignant disease. In. Kirby BI, Copeland EM eds. The breast –comprehensive management of benign and malignant disease. Vol 2. 2nd ed Philadelphia: WB Saunders company; 1998; p 233-246.
5. Hughes LE, Mansel RE, Webster DJT, aberrations of normal development and involution (ANDI) a new perspective of pathogenesis and nomenclature of human breast disorders. *Lancet* 1987; 2: 1316-1319.
6. Goodwin PJ, Neelam M, Boyed NF, Cyclical mastopathy; a critical review of therapy, *Br J Surg* 2005; 75:837-844
7. Wechselberger G, Sechoellr T, Piazza-Katzer H. Juvenile fibroadenoma of the breast, *Surgery* 2002; 132: 106-107
8. Haagesen CD: Abnormalities of breast growth, secretion and lactation In: Haagesen CD Editor, Diseases of the breast 3rd ed. Philadelphia: W.B. Saunders company : 1986; p .56
9. Beyer T, Moonka R. Normal Mammography and ultrasonography in the setting of palpable breast cancer. *Am J surg* 2003; 185: 416-419
10. Mansel RE, Singal H. Development abnormalities and benign breast diseases 4th ed. London; W.B. Saunders company; 1997; p 197
11. Rangabashyam. Spectrum of benign breast lesions in Madras. *J Roy Coll. Surg* 1998; 28:369-373
12. Khanna SNC, Aryya, Kahnnan NN. Spectrum of Benign breast disease. *Ind J surg* 1998; 28: 369-373.