



Effectiveness of Intralesional Bleomycin Sclerotherapy for Lymphangioma in Children

Authors

Dr. Mudassar Fiaz¹, Dr. Adnan Bashir Bhatti, MD², Dr. Irfan ullah²

¹Assistant Professor, Department of Neonatal & Paediatric Surgery, Children Hospital PIMS, Islamabad

²Department of Neonatal & Paediatric Surgery, Children Hospital PIMS, Islamabad, Pakistan

Corresponding Author

Dr Adnan Bashir Bhatti, MD

Department of Neonatal & Paediatric Surgery, Children Hospital PIMS, Islamabad, Pakistan

Email: dr.adnanbashir@gmail.com

Abstract

Introduction: Lymphangiomas are congenital lymphatic malformations. The treatment of choice is surgical excision, but it has a high rate of complications and recurrences. Many investigators have assessed numerous alternative approaches. Local injection of bleomycin has been found to be an efficacious therapy without opting for surgery. This study assesses the effectiveness of Intralesional Bleomycin Sclerotherapy (IBS) in treating children for lymphangiomas, primarily in terms of reduction in size.

Methods: This prospective interventional study was conducted at the Pediatric Surgery Department, Children Hospital PIMS, Islamabad, from July 1st, 2013 to March 31st, 2014. Sixty children with cystic hygroma were included in this study. Bleomycin aqueous solution was injected into the lesion post-aspiration, and patients were hospitalized for 24 hours post-procedure. The final assessment was made after 3 months post-injection sclerotherapy with Bleomycin to see the effect on the size of the lesion.

Results: The average age of the studied patients was 35.3 ± 25.4 months. There were 23 (38.3%) males and 37 (61.7%) females. The most frequent site was the neck in 38 (63.3%) children, other sites included face 8 (13.3%), axilla 8 (13.3%), and trunk 6 (10%). A single injection was effective in 3 (5%) patients, two injections were required in 21 (35%) and three injections were given in 36 (60%). Forty-three (71.7%) patients showed an excellent response, 12 (20%) patients showed a good response, and 5 (8.3%) showed a poor response to intralesional Bleomycin sclerotherapy.

Conclusion: Intralesional injection of bleomycin in children with lymphangioma is an effective method of achieving excellent to good results in more than 90% patients over three months.

Keywords: lymphangioma, cystic hygroma, bleomycin, sclerotherapy.

Introduction

Lymphangiomas are benign hamartomatous lymphatic tumors, also referred to as congenital deformities of the lymphatic structures^[1]. The most common and frequent type of lymphangioma

is cystic hygroma which may compose of one or more macrocytic lesions with reduced communication to the lymphatic channels^[1]. They are slow growing tumors and may manifest in any part of the body or anywhere in the soft tissues.

The most commonly affected sites are the head and neck, and also the mediastinum and axilla^[2]. These tumors most often occur in children, although they may occur in adults as well. They are also often evident at birth in 65% and may present by two years of age in 80-90% of the cases. The reported incidence of lymphangiomas is 1.5 to 2.8 per 1000, and it is not specific to any gender or race^[2]. Inflammation and cosmetic defects are the baseline symptoms. In the neck area, they may lead to compression symptoms when they compress important surrounding structures and may cause respiratory problems, dysphagia, and compression of nerves^[3].

There are different modes of treatment for cystic hygromas. These therapies include radiotherapy, incision and drainage, and surgical excision (which is the mainstay of therapy)^[2,4-6]. However, these procedures have variable findings which investigators find unsatisfactory. In many patients, a complete surgical resection is often not possible because of the nature of the lesion which encircles the crucial neurovascular system and also infiltrates across tissue planes^[2]. Post-surgical recurrence of tumors and injury to nerves are commonly observed complications, in addition to other issues such as disfigurement, and dreadful scar formation^[1,2]. In recent times, intralesional sclerotherapy has become increasingly accepted as an effective method for the treatment of the children with lymphangiomas^[1, 2, 4]. It involves the use of a sclerosing agent which irritates the endothelial lining of the lymphangioma leading to swelling, involution, and fibrosis^[2]. In the past, boiling water, 50% dextrose water, hypertonic saline, or absolute alcohol have been used with results that have not been very encouraging^[2]. Many centers are beginning to use sclerosing agents like Bleomycin, acetic acid, OK-432, and Doxycycline as first-line therapy with satisfactory results^[1,3,7,8]. Unlike surgical excision, this modality of treatment is particularly useful for lesions enveloping vital structures^[8].

In the past, bleomycin has been used as an antibacterial agent mainly due to its effects on

DNA, later on, it was also used as a chemotherapeutic agent^[2, 3]. Bleomycin has an excellent safety profile and has been utilized with confidence in the management of pediatric lymphatic malformations^[9]. A study conducted by Kumar et al. found complete regression in 20% to 74% of the cases^[1]. Many national and international studies, for instance, have mentioned the benefits of using intralesional bleomycin sclerotherapy (IBS) in lymphatic malformations in children^[1, 2]. This study was conducted to assess and emphasize the use of IBS for the non-surgical management of cystic hygromas in children.

Methodology

Using a prospective study design the study sample was selected for nine months between 1st July 2013 and 31st March 2014 in patients who presented at the Pediatric Surgical Department of the Children Hospital PIMS, Islamabad with features suggestive of lymphangioma. The study sample was composed of 60 cases of lymphangioma. Hospital record showed an average of 10 suspected cases presenting to the unit per month. All children between the ages of 1 month to 12 years who presented with lymphangioma were included in the study. Those with cysts less than 1cm, with diffuse lymphatic malformations and associated predominant hemangiomatous components, were excluded from the study. Patients with mediastinal, spinal or retroperitoneal extensions, visceral lymphatic malformations (challenging to reach locally), and those with infections were also excluded.

The following criteria were used to diagnose the cases of cystic hygroma:

- a) History was suggesting the presence of irregular swelling since birth which has gradually increased in size and present at the locations mentioned above.
- b) Presence of irregular soft swelling, non-tender and brilliantly transilluminant at the locations mentioned above.
- c) Ultrasound findings of the cystic lesion with or without loculations, and without hemangiomatous

elements. An absence of blood flow was confirmed on color Doppler (to rule out the presence of the blood vessels).

The response was assessed three months post-IBS as follows:

a) Excellent response – which is defined as 100% resolution (assessed on the basis of clinical examination, in which size was measured in centimeters; and ultrasound findings, in which reduction in the amount of fluid and reduction in the size was observed).

b) Good response – which is defined as more than 50% decrease in the size (assessed as above).

c) Poor response – which is defined as less than 50% reduction in the size.

Data collection was started after obtaining an ethical approval to conduct the study. The aim, procedures, benefits, and any risks were explained to the parents/guardians of the children, and consent obtained for children's examination and intervention according to the guidelines of the Helsinki Declaration [10]. The lesion measured in two dimensions and the largest dimension was used in the study to document the size of the lesion. The procedure included local or general anesthesia in the operation room. If required, children were also given chloral hydrate sedation. After applying aseptic measures, the lesion was excised using a hypodermic needle, after which bleomycin aqueous solution was infused into the lesion at a dose of up to 0.5mg/kg of the body weight. For decompressing the lesion, the multilocular lesions were aspirated at more than one site before injecting bleomycin solution. The needle tip used for aspiration was kept inside the lumen of the cyst.

Patients were admitted for up to 24 hours after the procedure. During this period, they were closely monitored for probable early and delayed side effects of Bleomycin administration. Additional data were obtained during the follow-up visit on the 30th day and 3 months post-IBS.

The data obtained were entered into and analyzed with the Statistical Package for the Social

Sciences (SPSS), version 16, for descriptive statistics. Descriptive statistics were used to analyze frequency and percentages from discrete variables whereas mean and standard deviations were calculated for continuous variables.

Results

In this study, 60 children with lymphangioma were included. The mean age of patients was 35.3 ± 25.4 months. There were 23 (38.3%) males and 37 (61.7%) females. The most frequent site of the lesion was the neck in 38 (63.3%), followed by the face in 8 (13.3%), axilla in 8 (13.3%), and trunk 6 (10%).

The size of lymphangioma at baseline ranged from 4 to 23cm in longest dimensions with a mean length of 11.4 ± 3.8 cm. The size of the lymphangioma at one month ranged from 0 to 18cm in longest dimensions with a mean length of 6.2 ± 3.3 cm. The size of the lymphangioma at two months ranged from 0 to 16 cm in longest dimensions with a mean length of 2.9 ± 3.3 cm. The size of the lymphangioma at three months ranged from 0 to 14 cm in longest dimensions with a mean length of 1.5 ± 2.9 cm (Table 2; Fig. 1). A single injection was effective in 3 (5%) patients, two injections were given in 21 (35%), and three injections were given in 36 (60%) patients (Table 1). A significant response was observed in 43 (71.7%) patients. They showed an excellent response to IBS resulting in the complete disappearance of the lesion. Moreover, 12 (20%) showed good response and achieved $>50\%$ reduction in the lesion size, whereas 5 (8.3%) patients showed a poor response and did not achieve 50% reduction in the lesion swelling. The swelling of these patients that exhibited a poor response was excised surgically (Fig 2).

Table 1: Demographic characteristics and presentation of lymphangioma (n=60)

	No of patients	%age
Age (months)		
Mean \pm SD	35.3 \pm 25.4	
Gender		
Male	23	38.3%
Female	37	61.7%
Ratio (male : female)	0.6 : 1	
Size of lymphangioma		
Neck	38	63.3%
Axilla	8	13.3%
Face	8	13.3%
Trunk	6	10.0%
No. of bleomycin doses required		
One	3	5.0%
Two	21	35.0%
Three	36	60.0%

Table 2: Reduction in the size of lymphangioma on each follow-up visit over 3 months (n=60)

Size of lymphangioma	Baseline (cm)	1 month (cm)	2 months (cm)	3 months (cm)	p-value (cm)
Mean \pm SD	11.4 \pm 3.8	6.2 \pm 3.2	2.9 \pm 3.3	1.5 \pm 2.9	<0.001

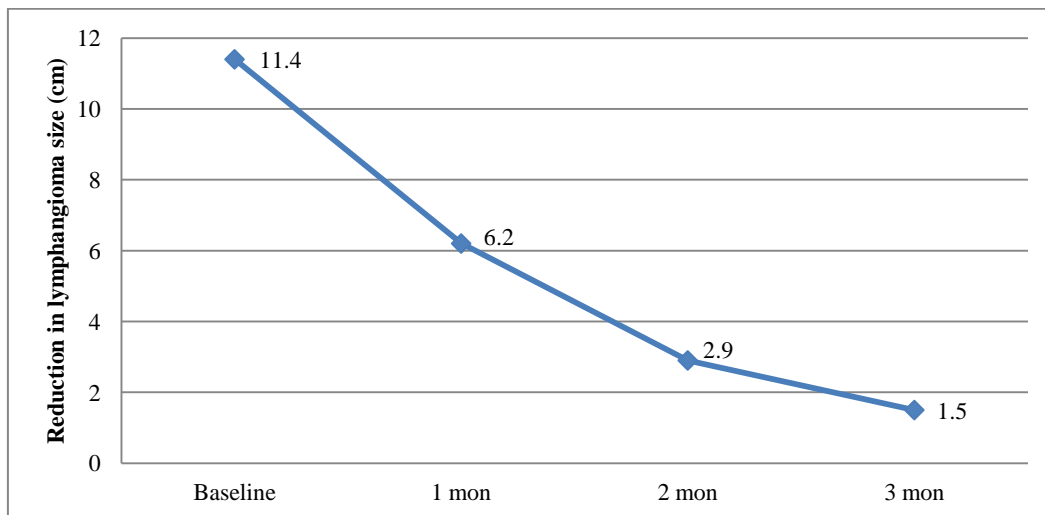


Figure 1: Gradual decrease in the size of lymphangioma (n=60)

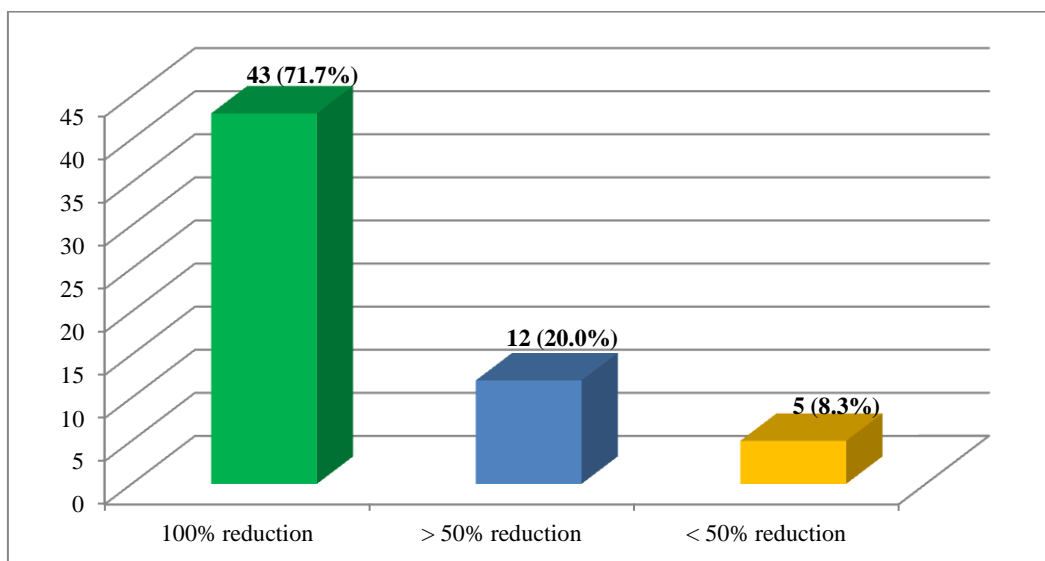


Figure 2: Final response to intralesional Bleomycin sclerotherapy (IBS) after 3 months

Discussion

Lymphangiomas are some of the most common hamartomatous congenital malformations affecting the lymphatic system^[1]. Although the lesions are benign, they cause enormous morbidity because of their large size and resultant mortality ranges from 3.4% to 5.7%^[11]. There has been a search for an effective and safe method of treatment besides surgical excision (due to the enormous risks of neurovascular damage associated with the surgical procedure). This study examined the efficacy of the use of bleomycin aqueous solution as a sclerosing agent for peripheral cystic hygromas. In this descriptive case series study, 60 children were treated with Bleomycin aqueous solution into their existing lymphangiomas after aspiration and then observation for 24 hours post-procedure. The final assessment was made after 3 months post-IBS in terms of the size of the lesion. Sclerotherapy has been long used as a substitute for surgery and agents such as bleomycin and OK-432 have commonly been used in lymphangioma^[2,3,7,8]. In these patients, it was expected that the lesions would be resolved entirely or reduce in size by the end of three months post-IBS.

In this study, the observed mean age for the children was 35.3 months, with females constituting more than two-thirds of the total population. Majority of the children had lymphangioma on the neck, followed by the face, axilla, and trunk sites. Neeraj et al. had earlier presented the outcome of a study on bleomycin therapy conducted on 10 subjects, out of which nine had a deformity in the cervical region and one in the parotid area^[12]. The observation of neck as the most common lymphangioma site is comparable with what has been reported in other studies^[2,3].

In our study, most of the children (72%) got an excellent response to bleomycin, and their lymphangiomas reduced 100% in size. Many previous studies have found excellent and good results in at least 60% of the cases^[2,13]. Sanlialp et al. also witnessed results similar to the findings in

this study^[6]. Similarly, Mahajan et al. found a significant reduction in (86.7%) patients, and (53.3%) of them showed complete disappearance^[14]. Also in the study by Sandlas et al.^[15] where 15 children with cystic hygroma were treated with IBS, an excellent response was seen in 53.3% of the patients, and 33.3% showed a good response to IBS, whereas 13.3% of the patients showed poor response. From these findings and the response of the study participants to IBS, it is clear that IBS has many benefits for patients with lymphangiomas.

Again, to reduce the swelling and inducing sclerosis, an intralesional injection of bleomycin was used in this study. This is in line with widely used protocols of bleomycin administration, particularly to produce sclerosis^[1-3,14,15]. As seen in the results of this study, there is evidence to support the use of IBS as a first-line therapy in the patients with lymphangiomas. Besides the excellent response recorded in the majority of cases, there are very low risks of significant side effects. Although there has been limited evidence on the use of bleomycin in managing children with lymphangioma, no major complication or mortality was encountered in this study. This could be due to the bleomycin regimens used in this study – between 1 mg/kg and 3 mg/kg doses in each patient. In cases of no response to the first IBS treatment, a second IBS treatment has been recommended after 6 weeks of intervention^[6]. For the participants in this study, they were simply observed and the second injection was considered not necessary as the sizes of cysts decreased. Therefore, a wait-and-see policy was applied as suggested in other studies^[6,16].

Side effects of IBS therapy such as erythema and induration of overlying skin were encountered in about 30% of cases in this study. These side effects appear common and have been recorded in previous studies^[17,18]. These side effects were mostly reported after patients had been discharged from the study. In a few cases, the lesions even enlarged after some weeks post-IBS probably as a result of edema, as recurrences are much rare

according to previous studies ^[1, 2]. Inflammation in terms of erythema and edema tend to occur more frequently probably because of the use of bleomycin sclerotherapy^[19]. However, since most of the studies reviewed do not carry out long-term evaluation of patients, it is possible that recurrence rates may be higher, and which may not be accounted for merely by inflammation arising as a result of the use of bleomycin.

Limited scientific evidence on the management of lymphangiomas, restricts us to conduct an in-depth analysis of the topic ^[20,21]. The majority of published studies are retrospective, and most merely describe the response to treatment with no comparison between treatment options. As a result of this, suggesting the ideal or superior therapy for lymphangiomas is relatively difficult. Some base evidence suggests that lymphangiomas can be effectively treated through either surgery or sclerotherapy, but more comparative studies are mandated to know which form of therapy is better. On this basis, it becomes necessary to compare intralesional bleomycin sclerotherapy against other suitable treatment options, especially surgery, in future studies.

Conclusion

Intralesional Bleomycin Sclerotherapy (IBS) for lymphangioma in the children is an effective treatment. This study achieved an excellent to good results in more than 90% of the patients over 3 months. In most of the cases, complete healing can be achieved with one to three injections. Further comparative interventional studies with rigorous research methodologies on the topic are mandated.

Conflict of Interest

The author finds no conflict of interest.

References

1. Kumar V, Kumar P, Pandey A, Gupta DK, Shukla RC, Sharma SP, et al. Intralesional bleomycin in lymphangioma: an effective and safe non-operative modality of treatment. *J Cutan Aesthet Surg.* 2012;5: 133–6.
2. Mirza B, Ijaz L, Saleem M, Sharif M, Shaikh A. Cystic hygroma: an overview. *J Cutan Aesthet Surg.* 2010;3:139-44.
3. Rozman Z, Thambidorai RR, Zaleha AM, ZZakaria, ZulfiqarMA. Lymphangioma: is intralesional bleomycin sclerotherapy effective? *Biomed Imaging Interv J.* 2011;7:18.
4. Manikoth P, Mangalore G P, Megha V. Axillary Cystic Hygroma. *J Postgrad Med* 2004;50:215-6.
5. Okada A, Kubota A, Fukuzawa M, Imura K, Kamata S. Injection of bleomycin as a primary therapy for cystic lymphangioma. *J Pediatr Surg.* 1992 Apr;27(4):440-3.
6. Sanlialp I, Karnak I, Tanyel FC, Senocak ME, Buyukpamukcu N. Sclerotherapy for lymphangioma in children. *Int J Pediatr Otorhinolaryngol.* 2003;67:795–800.
7. Erikçi V, Hoşgör M, Yıldız M, Örnek Y, Aksoy N, Okur Ö, Demircan Y, Genişol İ. Intralesional bleomycin sclerotherapy in childhood lymphangioma. *Turk J Pediatr.* 2013 Jul-Aug;55(4):396-400.
8. Yetiser S, Karaman K. Treatment of lymphangioma of the face with intralesional bleomycin: case discussion and literature review. *J Maxillofac Oral Surg.* 2011;10:152–4.
9. Albanese G, Kondo K L. Pharmacology of sclerotherapy. *Semin Intervent Radiol.* 2010;27:391–9.
10. World Medical Association. World Medical Association Declaration of Helsinki Ethical Principles for Medical Research Involving Human Subjects. *JAMA.* 2013;310(20):2191–2194. doi:10.1001/jama.2013.281053.
11. Bhattacharyya NC, Yadav K, Mitra SK, Pathak IC. Lymphangiomas in children. *Aust. N. Z. J. Surg.* 1981;51: 296-300.
12. Rana I, Bothra R, Dhawan R, Kathuria G, Pradhan T. Bleomycin sclerotherapy in

- congenital lymphatic and vascular malformations of head and neck. *International Journal of Pediatric Otorhinolaryngology*. 2005;69:75—80.
13. Orford J. Bleomycin therapy for cystic hygroma. *J Pediatr Surg*.1995;30:1282-87.
 14. Mahajan JK, Bharathi SK Chowdhary R. Bleomycin as intralesional sclerosant for cystic hygromas. *J Indian AssocPediatr Surg*. 2004;9:3-7.
 15. Sandlas G, Kothari P, Karkera P, Gupta A. Bleomycin: A worthy alternative. *Indian Journal of Plastic Surgery*. 2011;1:50-3.
 16. Seigal RD, Schiffman FJ. Systemic toxicity following intracavitary administration of bleomycin. *Chest*. 1990;98:507.
 17. Dorr RT, von Hoff DD. Drug monographs, bleomycin sulfate. In: Dorr RT, von Hoff DD (eds). *Cancer Chemotherapy Handbook*. 2 nd ed. Norwalk, Connecticut: Appleton & Lange, 1994:227–35.
 18. Roje Z, Roje Ž, Matić D, Librenjak D, Dokuzović S, Varvodić J. Necrotizing fasciitis: literature review of contemporary strategies for diagnosing and management with three case reports: torso, abdominal wall, upper and lower limbs. *World Journal of Emergency Surgery: WJES* 2011; 6: 46.
 19. Luís U, Diana M, Catarina P, João PF, Manuel MG et al. Cutaneous manifestations of systemic lupus erythematosus. *Autoimmune Diseases*. 2012; Article ID 834291: 15 pages, 2012. doi:10.1155/2012/834291.
 20. Prashant K. Minocha, LakhanRoop, Rambachan Persad. Cases of atypical lymphangiomas in children. *Case Reports in Pediatrics*. 2014: Article ID 626198: 6 pages, 2014. doi:10.1155/2014/626198.
 21. TN Son, NT Liem. Laparoscopic management of abdominal lymphatic cyst in children. *J Laparoendoscopic & Adv Surg Techniq*. 2012; 22 (5): 505–7.