



Results of Repeated Aspiration in Pancreatic Ascitis – A Study in 11 Cases

Authors

Dr Debananda Tudu¹, Dr Bana Bihari Mishra², Dr Bhupesh Kumar Nayak³

¹Assoc. Professor, ²Professor, ³Senior Resident

Department of General Surgery, VSS Institute of Medical Sciences and Research, Burla, Odisha

Email: dntudu7@gmail.com, 9437060477

Abstract

Pancreatic ascitis is a rare entity. Usually it is seen in alcoholics without any history of severe pain abdomen but with all the features of malnutrition and progressive ascitis which makes the diagnosis difficult. The diagnosis is settled by peritoneal fluid analysis for amylase, lipase and protein contents. The cause is usually established by ERCP. Most of the time the cause is trauma, rupture of pseudopancreatic cyst and ductal disruption in chronic pancreatitis. The conventional treatment includes repeated paracentesis, TPN, Octreotides, ERCP & stenting. Surgery may be needed in terms of cystogastrostomy, cystoduodenostomy, cystojejunostomy or distal pancreatectomy. Majority of the patients improved with conservative treatment for nearly 4 weeks and if no improvement planned for ERCP/Surgery. 11 cases of pancreatic ascitis were studied over a span of 3 years in the Dept. of General Surgery, VIMSAR, Burla from December 2014 to November 2017.

Introduction

Pancreatic ascitis is a rare complication and should be suspected in patients with chronic alcoholism and pancreatitis presenting with ascitis. The aetiology is likely from a pancreatic pseudocyst leakage or ductal disruption. Pancreatic ascitis resulting from trauma is due to traumatic injury to the duct and usually missed. The clinical features, timing of presentation are entirely different from that of pseudocyst and chronic pancreatitis. The treatment of this is purely surgical.

The diagnosis is difficult and mostly based on suspicion. Patients of known alcoholism, features of pancreatitis presenting with ascitis are investigated to diagnose pancreatic ascitis. The hallmark of diagnosis is peritoneal fluid amylase,

lipase and protein estimation. The cause is best evaluated by ERCP. In all places the facility for ERCP is not available, hence peritoneal fluid assessment is only the best way to confirm diagnosis.

The treatment is controversial but includes conservative medical therapy, endoscopic transpapillary pancreatic duct stenting, or surgery. Conservative treatment includes antibiotics, TPN, octreotides to reduce pancreatic secretion, repeated paracentesis or tube drainage of peritoneum. The conservative treatment is continued over a span of 3-4 weeks. Response is evaluated by clinical and USG evaluation.

Patients with good response are treated as chronic pancreatitis and followed up later on for any specific treatment. Patients who did not respond

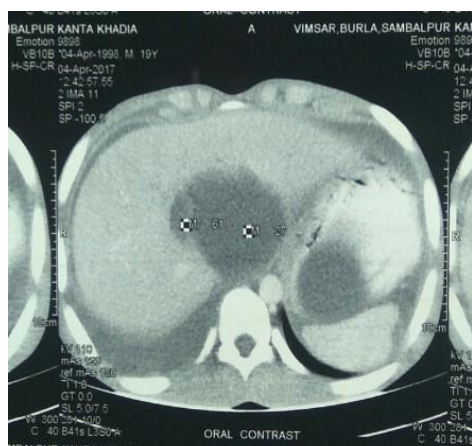
beyond 4-6 weeks were referred for ERCP and further therapy.

Material and Methods

11 cases of pancreatic ascitis were studied over a span of 3 years in the Dept. of General Surgery, VIMSAR, Burla from December 2014 to November 2017. Cases of traumatic pancreatic ascitis were excluded from this study.

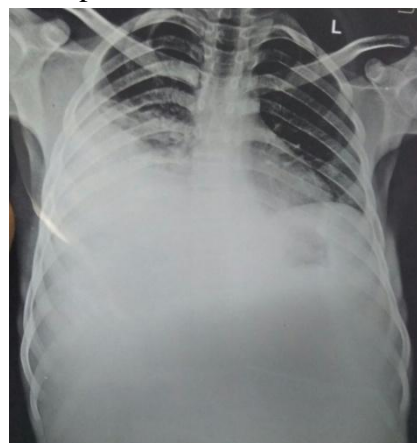On admission they were subjected for through clinical history, examination and investigated with CBC, Blood Sugar, Renal Function Test, LFT including serum protein and coagulation profile. USG of abdomen, upper G.I. endoscopy, CECT Abdomen and pelvis, peritoneal/pleural fluid analysis for amylase, lipase and protein contents were done.

In most cases there was leucocytosis with rise in neutrophils. 2 cases were found to be diabetic who were earlier diagnosed as chronic pancreatitis. In all of our cases the renal function test was within normal limit. 7 cases had alteration in liver enzymes but none had hyper bilirubinaemia. Serum protein level was low in all cases. X-ray chest revealed left sided pleural effusion in 2 cases and 1 in right side. USG abdomen exhibited gross peritoneal collections in all cases and associated pleural effusion in 3 cases. The imaging of the pancreas in USG abdomen was unclear. CECT clearly showed, the peritoneal collection, atrophy of the pancreatic parenchyma in 9 cases, presence of calculi in MPD (Main Pancreatic Duct) in 2 cases and MPD diameter was 5-7mm.



[CECT showing massive ascitis]

Peritoneal fluid analysis showed amylase level more than 1000 IU/dl with high lipase level and protein more than 3 gm/dl in all cases, which confirmed the pancreatic ascitis.



[Photo showing right sided pleural effusion]

Age of the patients

Total no. of cases = 11

Age in years	No. of cases
10-20	1
20-30	2
30-40	2
>40	6

Clinical Presentation

Variable abdominal pain	11
Increased abdominal girth	11
Weight loss	11
Shortness of breath	3
Pedal edema	11

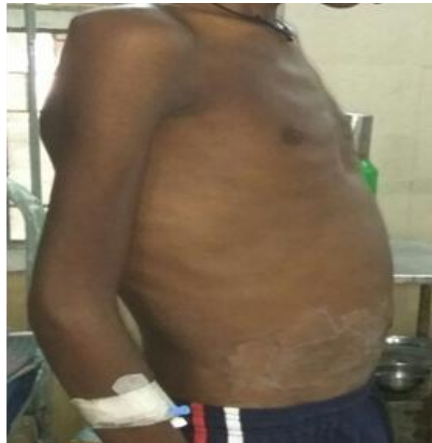Basing on the principle that serous cavities should be emptied to promote approximation of surfaces by aspiration or drainage. All 11 cases were subjected to repeated paracentesis over a span of 4 weeks. Two cases who did not respond to paracentesis tube peritoneal drainage was done. One case who did not respond to these was referred for ERCP and stenting. All cases were kept on NPO/Nasojejunal feeding, TPN and Octreotides to decrease pancreatic secretions.

Results

Treatment- Total cases = 11

Conservative	11
Repeated paracentesis	11
Tube peritoneal drainage	2
ERCP & stenting	1

Eleven cases were managed conservatively with similar protocol. Nine cases improved fully and were discharged with a follow up schedules (USG abdomen and CECT abdomen). Two cases not responding to repeated paracentesis were subjected for tube peritoneal drainage, one of them improved after 2 weeks of drainage and the other patient who did not responded (drain output remained high) was referred for ERCP and stenting.

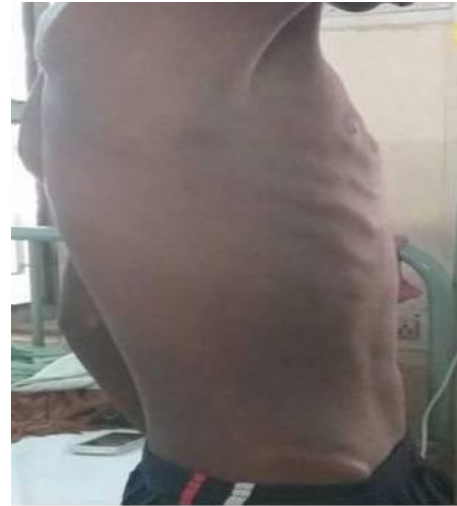

[Photo showing increased abdominal girth]

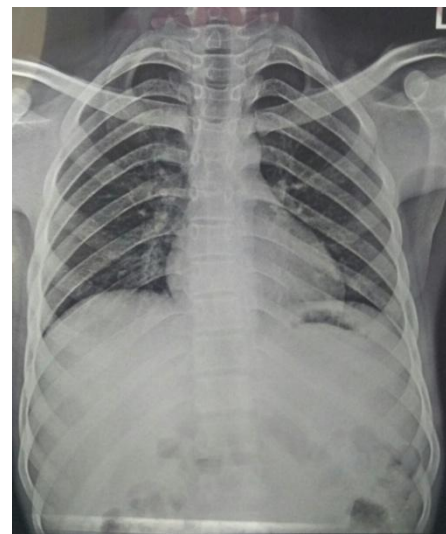
Discussion

Pancreatic ascitis patients present with ascitis, malnutrition and low general condition. They need minimal intervention which will give a result better than ERCP/Surgery, which has morbidity and mortality.

Out of 11 cases 9 cases (82%) had complete remission of symptoms with paracentesis alone. One case which improved after tube peritoneal drainage is probably because of very thick exudation which was not helped by aspiration. The case which needed an ERCP procedure had a large ductal disruption which did not improve with this treatment. Conservative treatment in the form of TPN & octreotides therapy is the mainstay of treatment in all procedures –like repeated paracentesis, tube drainage, ERCP & stenting, or surgery.



[Photo showing decreased abdominal girth]



[X-Ray showing decreased right sided pleural effusion]

Summary

The treatment of pancreatic ascitis is mostly conservative followed by ERCP & stenting or surgery. The ERCP facility may not be available everywhere and is associated with fatal complications many times particularly in such low condition patients. Surgical procedures in such cases carry high morbidity and mortality. Repeated peritoneal aspiration along with conservative treatment is a simpler procedure with better outcome and avoids the complications of ERCP or surgery. In patients who needs ERCP/Surgery prior conservative treatment with paracentesis adds to the result.

References

1. Kalian kanneganti, et.al, Successful Management of pancreatic ascitis. Gastroenteronoly Res. 2009 Aug; 2(4): 245-247.
2. Closset J, et.al, Management of pancreatic ascites and pancraticopleural effusion. Acta Gastroenterol Belg. 2000; 63(3):269.
3. Cabrera J. Ascitis de origen pancreatico. Med Clin [Barc] 1986;86:369-372
4. Fernandez-Cruz L, et.al, Pancreatic ascitis. Hepatogastroenterolog. 1993; 40(2):150-154.
5. Parekh D, et.al, Pancreatic ascitis and effusion. Risk factors for failure of conservative therapy and role of octreotide. Arch Surg. 1992; 127(6):707-712.
6. Gomez-Cerezo J, et.al, Pancreatic ascitis: study of therapeutic options by analysis of case reports and case series between the years 1975 and 2000. Am J Gastroenterol. 2003;98(3):568-577.
7. Bracher GA, et.al, Endoscopic pancreatic duct stenting to treat pancreatic ascites. Gastrointest Endosc. 1999; 49(6):710-715.
8. Chebli JM, et.al. Internal pancreatic fistulas:proposal of management algorithm based on a case series analysis. J Clin Gastroenterol. 2004; 38(9):795-800.
9. Kozarek RA, Jiranek GC, et.al. Endoscopic treatment of pancreatic ascites. Am J Surg. 1994; 168(3):223-226.