



## Validity of Magnetic Resonance Imaging in the evaluation of bone tumours using surgical and pathological findings as reference standard

Authors

**Dr Safi Salim, Dr Suma Job, Dr Josey Verghese, Dr Harikumaran Nair GS**

Department of Radiodiagnosis, Government T.D. Medical College, Alappuzha, Kerala, India

Corresponding Author

**Dr Suma Job**

Email: [sumajob@yahoo.com](mailto:sumajob@yahoo.com)

### Abstract

**Introduction:** Conventional teaching identifies that the ultimate responsibility for definitive diagnosis of bone tumour resides with the pathologist. But the radiologist has the added advantage of viewing the lesion in a bigger canvas using the different imaging modalities. Despite newer imaging techniques, radiograph is the preliminary and single most important imaging investigation. MR imaging helps to confirm the diagnosis, determine the focal extent and local staging of the tumour for its effective treatment and follow up. However false positive diagnosis may lead to over staging of tumour and result in unnecessarily radical surgical procedures. This study is meant to assess the sensitivity, specificity, positive predictive value and negative predictive value of MRI findings in bone tumours using surgical and pathological findings as reference standard.

**Methodology:** The study was a descriptive study with diagnostic test evaluation. The study population included all patients clinically suspected of bone tumour referred for MRI evaluation from orthopaedics department to Department of Radiodiagnosis, Govt. T.D. Medical College, Alappuzha. MRI findings were evaluated to look for marrow, soft tissue, joint, neurovascular bundle, and cortical involvement. The obtained data from MRI findings were compared with surgical and pathological findings by statistical analysis.

**Results:** MRI shows high sensitivity of 100% in detection of marrow, soft tissue, joint and neurovascular bundle involvement and 97.4% in the detection of cortical involvement and specificity of 87.5%, 70.6%, 95%, 98.2% and 100% respectively in detection of marrow, soft tissue, joint, neurovascular bundle and cortical involvement; in comparison with surgical and pathological findings.

**Conclusion:** MR imaging is highly sensitive and specific in assessing the extent of involvement of bone tumour and thus aids in its treatment.

**Keywords:** MR imaging; bone tumour.

### Introduction

Conventional teaching identifies that the ultimate responsibility for definitive diagnosis of bone tumour resides with the pathologist<sup>1</sup>. But the radiologist has the added advantage of viewing the lesion in a bigger canvas using the different imaging modalities. Despite newer imaging

techniques, radiograph is the preliminary and single most important imaging investigation. They provide critical information regarding lesion location, margin, matrix mineralization, cortical involvement and adjacent periosteal reaction.

MR imaging rapidly became established as an imaging modality in the detection,

characterization, staging, post-therapy assessment and surveillance of bone tumours, since its introduction into clinical practice in the 1980s.

The excellent contrast resolution and ability of MRI to image directly in three orthogonal planes lead to improved evaluation of both intra compartmental and extra compartmental extent of lesion, invasion of muscle, neurovascular structures and adjacent fat planes and degree of marrow involvement. Multiplanar capabilities make it extremely important in the staging, evaluation of effectiveness and follow up of treatment<sup>2</sup>.

The lack of ionizing radiation makes it possible to image a larger area and hence MRI is the best technique to detect skip lesions (small metastasis separated from primary tumour by healthy tissue) which are often missed by other imaging methods. MR imaging helps to confirm the diagnosis, determine the focal extent and local staging of the tumour for its effective treatment and follow up.

However false positive diagnosis may lead to over staging of tumour and result in unnecessarily radical surgical procedures. This study is meant to assess the sensitivity, specificity, positive predictive value and negative predictive value of MRI findings in bone tumours using surgical and pathological findings as reference standard.

#### Magnetic Resonance Imaging

In bone and joint disease, it is sometimes difficult to distinguish a benign from a malignant bone lesion. To avoid this, it is necessary to know the typical semiology of certain tumours and tumour like lesions which do not require histological confirmation. Most common "leave me alone" lesions<sup>3</sup> are nonossifying fibroma/ fibrous cortical defect/cortical desmoid, fibrous dysplasia, exostosis, solitary bone island (osteoma) and enchondroma. MRI helps to confirm the diagnosis of leave me alone lesions and thereby enable prompt diagnosis and avoid a high number of unnecessary biopsies.

MRI helps in the evaluation of extent of the lesion by assessing the extent of marrow involvement, soft tissue extension, joint involvement,

neurovascular bundle invasion and cortical involvement. MRI is a sensitive method in detecting areas of malignancy within the bone marrow towards which biopsy could be directed. The extent of marrow involvement is best shown by T1W images and STIR coronal or sagittal sequence<sup>4</sup>. T2W axial images best demonstrate extra osseous involvement.

MRI is highly sensitive for detecting joint involvement in malignant tumours. However false positive diagnosis may lead to overstaging of tumour and result in unnecessary radical surgical procedures.<sup>5</sup> When MR imaging is used, the presence of peritumorous inflammatory changes may lead to false positive diagnosis of joint involvement, which may be followed by unnecessarily radical en-bloc resection of joint.

Radiologic depiction of soft tissue mass with respect to neurovascular bundle is important in planning surgical approaches for local control of tumour. Tumour with deviation of neurovascular bundle may be considered for amputation instead of a limb salvage procedure because the ability to obtain adequate surgical margins around the tumour may be compromised. The relationship of NV bundle to the tumour is best shown on T2W axial images and T1W post contrast axial sections. Fat saturated T1 weighted post contrast images are superior to T2 weighted images in defining the proximity of soft tissue tumour mass to neurovascular bundle.

MR angiography provides good visualization of peripheral vascular branches and tumour neovascularity in patients with primary bone tumours. MR angiography demonstrates encroachment onto and encasement of major vessels by the tumour mass and appears to be useful for assessing response to chemotherapy in osteogenic sarcoma and possibly other primary bone tumours by detecting treatment induced changes in tumour neovascularity.<sup>6</sup>

Value of MR imaging in specific histological diagnosis is low. There are certain specific diagnoses that have a relatively characteristic MR

appearance. Cohen et al<sup>7</sup> observed a distinctive MR appearance in chondroid lesions.

MR imaging is the method of choice in staging musculo-skeletal neoplasms. MR images are read in conjunction with radiographs. MRI evaluation of intra- and extraosseous extent, joint invasion, neurovascular bundle involvement, skip metastases, and local adenopathy as well as distant metastases is important for accurate staging and subsequent therapy. FDG-PET may be considered for staging and evaluation of treatment response in selected cases<sup>8</sup>. There are two systems currently used for staging musculoskeletal neoplasms: the Musculoskeletal Tumour Society (MSTS) system and the American Joint Committee on Cancer (AJCC) system. The Enneking surgical staging system is reliable, reproducible and has prognostic importance for musculoskeletal sarcomas, especially for those originating in the axial skeleton.

Local extent for any neoplasm refers to its containment in anatomic boundaries of a compartment. Anatomic compartments have inherent barriers to tumour spread like fascial planes and bone structures. Thus local extent determines the approach for surgical procedure and feasibility for desired surgical margins. A high-grade lesion is more likely to invade surrounding tissues. This places the patient at greater risk of local recurrence and metastasis. The use of neoadjuvant therapy will reduce the tumour bulk. Adjuvant therapy is also indicated to eradicate tumour cells that would remain after surgical resection.

### Advances in bone tumour imaging

#### Use of Higher Magnetic Field Strengths

1.5 T is considered effective for clinical practice and use of higher field strength shows no substantial benefit in routine clinical imaging of bone tumours. Higher field strengths using 3.0-T magnets have improved SNR, more homogeneous fat suppression, and increased separation of various spectral peaks at MR spectroscopy. Use of 3.0 T, allows shorter scan times and reduced energy deposition<sup>9</sup>. There are many technical

challenges of higher magnetic field strengths, like changes in tissue contrast, increase in amount of chemical shift and magnetic susceptibility effects, and larger amounts of energy deposited in the patient<sup>10</sup>.

#### Quantitative dynamic MR imaging

It estimates the amount of necrosis in bone tumours based on the principle that viable tumour enhances faster than nonviable tumour and post-treatment changes. This technique has been shown to correlate reasonably well with results obtained at histopathologic analysis in osteogenic sarcoma and Ewing sarcoma<sup>11</sup>.

#### Diffusion-weighted imaging

DWI of tumours is based on the principle that the diffusion of water is more restricted in a tumour than in normal tissue, manifesting as less loss of signal on DWI. Malignant bone tumours show restricted diffusion. Infection mimics malignant tumour as it also shows restricted diffusion. DWI is also useful in assessing the response of bone tumours to therapy<sup>12</sup>.

### Methodology

It was a descriptive study with diagnostic test evaluation for 18 months, starting from the date of acceptance of protocol of the thesis. Study was conducted in Orthopaedics department and Department of Radiodiagnosis, Government. T.D. Medical College Alappuzha, Kerala. Study population included all suspected cases of bone tumours referred for MRI evaluation from orthopaedics department to Department of Radiodiagnosis of T.D. Medical College, Alappuzha.

#### Inclusion Criteria

- All patients suspected of bone tumour referred for MRI evaluation from orthopaedics department to Department of Radiodiagnosis of Govt. T.D. Medical College, Alappuzha.

#### Exclusion Criteria

- Patients who had undergone recent biopsy.

- Patients in whom MRI is contraindicated or MRI is not successful.
- Patients who are not willing to participate in the study.
- Patients in whom surgical or pathological diagnosis is not obtained on follow up.

### Sample Size

Sample size would include all patients suspected of bone tumour referred for MRI evaluation from orthopaedics department to Department of Radiodiagnosis of T.D. Medical College, Alappuzha, during a period of 18 months.

By using the formula-  $(Z\alpha)^2 \times pq/d^2$  one would get the total number of positive cases which is required for the study. Where,

$Z\alpha$  is 1.96 at 95% confidence interval.  $p$  is expected sensitivity

$q$  is  $(100-p)$

$d$  is precision, which can be 5 to 20% of  $p$ .

Hence the total number of positive cases  $(1.96^2 \times 95 \times 5)/10.45^2 = 16.7$ ; rounded to 17 cases.

Hence sample size would be equal to total number of positive cases ( $n$ ) required for the study divided by prevalence ( $P$ ).

Sample size =  $n/P = 17 \times 100/27 = 62.96$ ; Rounded to 65 cases.

We used a pretested semi-structured proforma for data collection using plain film, MRI, surgical and histopathological findings.

The study was commenced after the approval of the ethical committee of the institute. The subjects were explained about benefits of the study and written informed consent was taken from all the study subjects.

The study population included all patients suspected of bone tumour referred for MRI evaluation. The proforma was filled up with emphasis on age, presenting complaints, history of any known malignancy or chronic systemic illnesses and family history. All patients were first evaluated with plain film examination in at least 2 planes.

MRI was performed on a 1.5 Tesla General Electronics System (Signa HDXT). TR (time to

repeat) is the time interval between two successive pulse cycles. TE (time to echo) is the time interval from one pulse to the measurement of MR signals. For a T1Weighted image, short TR (250 to 600ms) and short TE (10 to 25ms) is used. For a T2 Weighted image, long TR (>2000 ms) and long TE (>60ms) is used. STIR (Short tau inversion-recovery) sequence produces heavily T1 weighted image with fat suppression to demonstrate anatomical details. STIR sequence was the most reliable in showing intramedullary tumour extent.

Initially a large field of view T1W SE and STIR SE sequence was obtained of the area of interest in coronal plane using body coil to ensure that the extent of tumour and skip lesions were identified. This was followed by T1 and T2 weighted TSE sequences in axial plane supplemented by sagittal and coronal planes using surface coil. Second plane of imaging included a STIR sequence. Post contrast fat saturated T1 weighted images were obtained after giving 10ml of IV Gadolinium, if indicated.

MRI findings were evaluated to look for marrow and soft tissue involvement. The relationship of the tumour to adjacent joint and involvement of the intrasynovial joint space is to be presumed where T1W images show a contrast enhancing mass extending into the joint space, either by disruption of joint capsule or by intraarticular destruction of cortical bone and the articular cartilage. Joint involvement should also to be presumed in cases of tumour extension into the cruciate ligaments which are intracapsular but extrasynovial. On MRI, neurovascular bundle involvement was considered when tumour is surrounding these structures or containing at least one half the circumference and obliterating the associated fat plane. The signal intensity pattern should be assessed to look for any specific appearance of the tumour.

The patients were followed up and those patients who underwent surgery were taken into consideration for analysis. A subjective intra-operative assessment of lesion regarding the

presence or absence of each of the 5 variables (marrow, soft tissue, joint, NVB and cortical involvement) evaluated in MRI was done. The final histopathology reports were also analysed.

Data was entered in Microsoft excel. Analysis of the data was done in SPSS version 17.0 and DAG\_ Stat (Diagnostic & Agreement Statistics analysis package).

Frequencies of variables, comparison between variables, sensitivity, specificity, positive predictive value, negative predictive value and accuracy were calculated.

**Results**

Out of the 65 patients studied, 70.7% (46) were benign and 29.3 % ( 19) were malignant. Plain film detected cortical break with sensitivity, specificity, positive predictive value and negative predictive value of 91%, 84%, 86% and 90% respectively; using surgical and pathological findings as reference standard. The results obtained had high sensitivity and negative predictive value with lower specificity and positive predictive value in comparison with the results of study by Baweja S et al<sup>5</sup> which had a sensitivity, specificity, positive predictive value and negative predictive value of 61.5%, 100%, 100% and 50% respectively.

Plain film detected soft tissue involvement with sensitivity, specificity, positive predictive value and negative predictive value of 85%, 68%, 81% and 73.9% respectively; using surgical and pathological findings as reference standard.

**MRI findings in bone tumours**

**Marrow Involvement:**

T1W images and STIR coronal or sagittal sequences demonstrated very well the extent of marrow involvement. MRI detected marrow involvement with sensitivity, specificity, positive predictive value and negative predictive value of 100%, 87.5%, 96.08% and 100% respectively; in comparison with surgical and pathological findings.

**Soft tissue involvement:**

Best detected in T1 W post contrast images and T2 W axial images. MRI detected soft tissue involvement with sensitivity, specificity, positive predictive value and negative predictive value of 100%, 70.6%, 90.6% and 100% respectively in comparison with surgical and pathological findings.

**Joint involvement:**

T1 W longitudinal (coronal and sagittal) post contrast images best demonstrated the enhancing mass within the joint space. MRI detected joint involvement with sensitivity, specificity, positive predictive value and negative predictive value of 100%, 97.8%, 95% and 100% respectively in comparison with surgical and pathological findings.

**Neurovascular bundle involvement:**

MRI detected neurovascular bundle involvement with 100% sensitivity, 98.2% specificity, 88.9% positive predictive value and 100% negative predictive value in comparison with surgical and pathological findings.

**Cortical involvement:**

It was best demonstrated on T1 W images. The sensitivity, specificity, positive predictive value and negative predictive value of MRI in detecting cortical involvement in comparison with surgical and pathological findings in our study were 97.4%, 100%, 100% and 96.4% respectively.

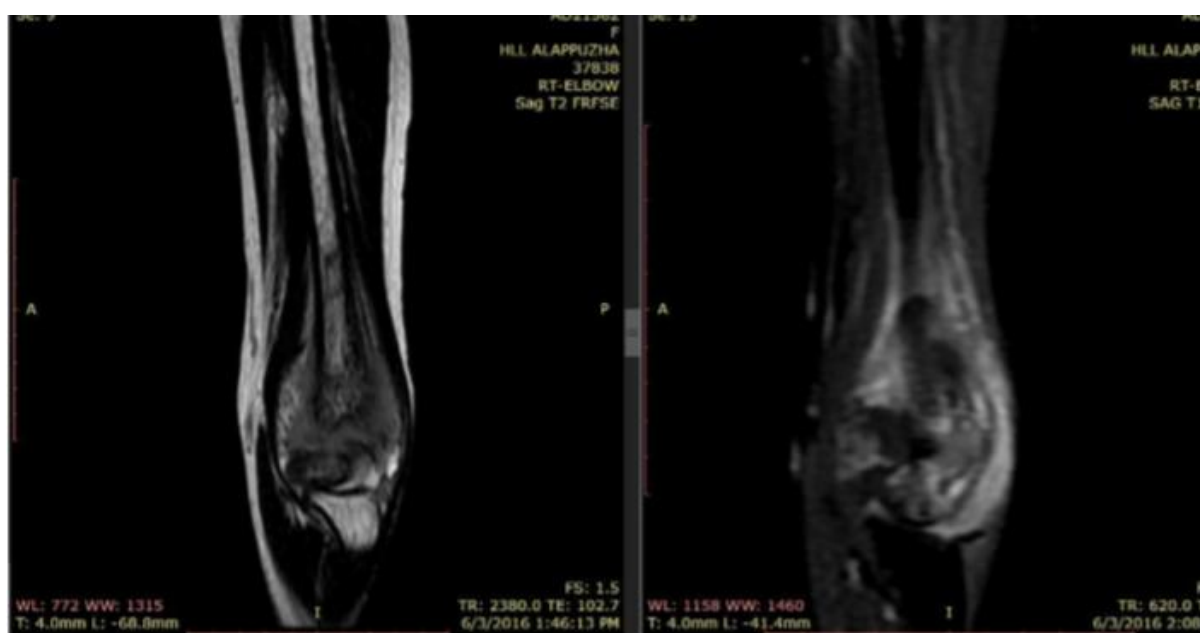
**Table 1:** Comparison of soft tissue involvement in plain radiograph with its presence or absence in surgical and pathological findings

Soft tissue involvement	Surgical and pathological findings of soft tissue involvement		Total No: (%)
	Present No: (%)	Absent No: (%)	
Present	34 (85.0)	8 (32)	42 (64.6)
Absent	6 (15.0)	17 (68)	23 (35.4)
Total	40 (100)	25 (100)	65 (100)

**Table 2:** Comparison of MRI findings with corresponding surgical and pathological findings

Study variables in MRI	Sensitivity (%)	Specificity (%)	PPV (%)	NPV (%)
<b>Marrow involvement</b>	89.5	26.1	33.3	85.7
<b>Soft tissue involvement</b>	94.7	23.9	34.0	91.7
<b>Joint involvement</b>	52.6	78.3	50	80
<b>NVB involvement</b>	31.6	93.5	66.7	76.7
<b>Cortical involvement</b>	89.5	56.5	46	92.9

**Fig 1:** 16 year old female with pain and swelling right elbow; Sagittal T2-WI and T1 FS post contrast images show diffuse ill defined abnormal marrow signal involving entire distal humerus with soft tissue involvement and infiltration into right elbow joint- suggestive of malignant etiology possibly Ewing’s sarcoma



**Discussion**

The sensitivity of MRI in detection of marrow, soft tissue, joint and NVB involvement was 100%, while the sensitivity of detection of cortical involvement was 97.4%. Thus, MRI is a highly sensitive investigation in the evaluation of bone tumours in comparison with surgical and pathological findings. This is consistent with the 100% sensitivity of MRI in the studies of S. Baweja<sup>5</sup> et al, Daffner<sup>3</sup> et al in marrow involvement, Bloem<sup>13</sup> et al in NVB involvement and Van Trommel<sup>14</sup> et al in joint involvement.

The specificity of MRI in detection of marrow, soft tissue, joint, NVB and cortical involvement were 87.5%, 70.6%, 95%, 98.2% and 100

respectively. The specificity obtained in the study is comparable with specificity of MRI in the studies of S.Baweja<sup>5</sup> et al , Daffner<sup>3</sup> et al in marrow involvement (100%), Bloem<sup>13</sup> et al in NVB involvement (98%) and Van Trommel<sup>14</sup> et al in joint involvement (70%).

**Signal characteristics:**

Majority of the malignant lesions were hypointense on T1WI and heterogeneously hyperintense on T2WI. MRI was done to assess the thickness of cartilaginous cap in cases of suspicion of chondrosarcoma. Lesions of chondrosarcoma show high T2 signal due to its increased water content. T2 WI was used to assess the thickness of cartilaginous cap. All 11 cases

diagnosed histologically as osteochondroma were diagnosed correctly as osteochondroma by MRI. All 11 cases had cartilaginous cap thickness of less than 1cm. 2 of them had diaphyseal aclasia which has a greater predilection for malignant transformation. One case of suspected osteochondroma was diagnosed correctly as chondrosarcoma in MRI. MR imaging helps in detection of intra-tumoural necrosis and haemorrhage; thus enables choosing the appropriate site for biopsy.

### Conclusion

MR imaging is highly sensitive and specific in assessing extent of involvement of bone lesion, accurate staging and thus aids in its treatment. The sensitivity of MRI in detection of marrow, soft tissue, joint and neurovascular bundle involvement was 100%, while the sensitivity of detection of cortical involvement was 97.4%; in comparison with surgical and pathological findings. The specificity of MRI in detection of marrow, soft tissue, joint, neurovascular bundle and cortical involvement were 87.5%, 70.6%, 95%, 98.2% and 100 respectively; in comparison with surgical and pathological findings.

**Funding:** Nil.

**Conflict of interest:** None

**Permission of IRB:** Yes

### References

1. van der Woude HJ, Bloem JL, Hogendoorn PC. Preoperative evaluation and monitoring chemotherapy in patients with high-grade osteogenic and Ewing's sarcoma: review of current imaging modalities. *Skeletal Radiol* 1998; 27:57–71
2. Moser RP, Madewell JE. An approach to primary bone tumors. *Radiol Clin North Am* 1987; 25:1049–1093.
3. Daffner RH, Lupetin AR, Dash N, Deeb ZL, Sefczek RJ, Schapiro RL. MRI in the detection of malignant infiltration of bone marrow. *AJR Am J Roentgenol*. 1986 Feb;146(2):353-8.
4. Wolfgang Schima, Gabriele Amann. Preoperative staging of osteosarcoma Efficacy of MR imaging in detecting joint involvement *AJR* 1994 ;163 :1171-1175.
5. Baweja S, Arora R, Singh S, Sharma A, Narang P, Ghuman S, Kapoor S K, Puri S. Evaluation of bone tumors with magnetic resonance imaging and correlation with surgical and gross pathological findings. *Indian J Radiol Imaging* 2006 ;16:611-8.
6. Lang P, Grampp S, Vahlensieck M, et al. Primary bone tumors: value of MR angiography for preoperative planning and monitoring response to chemotherapy. *AJR Am J Roentgenol* 1995;165:135–142.
7. Thomas H Berquist. Magnetic resonance Imaging of Primary skeletal neoplasms, *Radiologic clinics of North America* March 1993 31;2 :411423.
8. Gregory S. Stacy, Ravinder S. Mahal, and Terrance D. Peabody; Staging of Bone Tumors: A Review with Illustrative Examples ; *American Journal of Roentgenology* 2006 186:4, 967-976.
9. Ladd ME. High-field-strength magnetic resonance: potential and limits. *Top Magn Reson Imaging* 2007;18:139–152.
10. Gold GE, Han E, Stainsby J, Wright G, Brittain J, Beaulieu C. Musculoskeletal MRI at 3.0 T: relaxation times and image contrast. *Am J Roentgenol*2004; 183:343–351.
11. Baur A, Reiser MF. Diffusion-weighted imaging of the musculoskeletal system in humans. *Skeletal Radiol* 2000; 29:555–562.
12. Hayashida Y, Yakushiji T, Awai K, Katahira K, Nakayama Y, Shimomura O, Kitajima M, Hirai T, Yamashita Y, Mizuta H. Monitoring therapeutic responses of primary bone tumors by diffusionweighted image: initial results. *Eur Radiol* 2006,16:2637–264.

13. JL Bloem, HJ vander woude, Does magnetic resonance imaging make a difference for patients with musculoskeletal sarcoma? *The British Journal of Radiology* 1997;70:327-337.
14. Michiel F Van Trommel, Herman M Kroon, MR imaging based strategies in limb salvage surgery for osteosarcoma of the distal femur, *Skeletal Radiology* 1997;26:636-64.