



## Coronary Artery Ectasia, its Clinical Profile and Angiographic Characteristics, Single Centre Experience (Rajarajeswari Cardiology Department)

Authors

**Dr Rajiv Girdhar<sup>1</sup>, Dr Ram Anil Raj<sup>2</sup>, Dr Yogesh Kothari<sup>3</sup>, Dr Kumar Kenchappa<sup>4</sup>,  
Dr Nararyana Raju<sup>5</sup>, Dr Ashwin Kumar K.C<sup>6</sup>**

<sup>1</sup>PG in Dm Cardiology Dept, Rajarajeswari Medical College & Hospital, Mysore Road, Bangalore -560074

<sup>2</sup>Associate Professor in Cardiology Dept, Rajarajeswari Medical College & Hospital, Mysore Road, Bangalore -560074

<sup>3</sup>HOD & Associate Professor in Cardiology Dept, Rajarajeswari Medical College & Hospital, Mysore Road, Bangalore -560074

<sup>4,5</sup>Assistant Professor in Cardiology Dept, Rajarajeswari Medical College & Hospital, Mysore Road, Bangalore -560074

<sup>6</sup>Internship in Cardiology Dept, Rajarajeswari Medical College & Hospital, Mysore Road, Bangalore -560074 INDIA

### Abstract

**Objective:** To evaluate the incidence of coronary ectasia and its clinical profile and angiographic characteristics in our Rural area population.

**Methods:** A Descriptive analysis was carried out in the Department of Cardiology in Rajarajeswari Medical college and Hospital, Bangalore from January 2015 to November 2017 on all patients undergoing coronary angiographies and Data were collected from catheterization films, and medical records.

**Results:** In a total of 869 coronary angiograms were performed during the period of the study. A total of 139 (15.99%) angiograms showed coronary ectasia of both mixed and pure types. Pure ectasia with no coronary obstructive lesions was seen in 36 (25.89%). Type 4 was most common 61 pts. (43.88%), as per the Markis classification. Right coronary artery (RCA) was the most commonly affected vessel 100 (72%) followed by left anterior descending artery (LAD) 45 (33.78%) and 23 patients (16.54%) patients had circumflex artery involvement. 83 patients (59.71%) had good left ventricular (LV) systolic function.

**Conclusion:** Prevalence of Coronary ectasia in the population presenting in the Department of Cardiology in Rajarajeswari Medical college and Hospital, Bangalore during the study period was 15.99%. Majority of patients were males, associated with, hypertension and diabetes mellitus. CAE was associated with obstructive coronary artery disease in about 74.22% of cases. RCA was the most commonly affected vessel.

**Keywords:** Coronary artery disease, Ectasia, Aneurysm, coronary artery angiography.

### Introduction

Coronary artery ectasia (CAE) is defined as the dilatation of the coronary artery of 1.5 times the reference range for that vessel<sup>1,2</sup>. They represent

the direct result of inappropriate coronary dilatation. Angiographic signs of turbulent and stagnant flow include delayed antegrade flow, segmental backflow and local deposition of dye in

the dilated coronary segment.<sup>3,4</sup> It is graded according to Markis into four grades based on the extent of ectasia in decreasing order of severity. Type 1 is diffuse ectasia of two or three vessels, Type 2 is diffuse disease in one vessel and localized disease in one vessel, Type 3 is diffuse ectasia in one vessel while Type 4 is localized or segmental ectasia.<sup>3</sup> This major group of angiographic findings in the absence of flow with significant coronary events and lead to morbidity among these patients. It has been underreported and undertreated and could lead to recurrent hospitalizations. Various studies have found the incidence of CAE between 1% -16%.<sup>3,5-9</sup> The maximum reported incidence of CAE by Waly et al in an Egyptian study in 1997 was 16.4% of all patients undergoing coronary angiograms.<sup>9</sup> In various Indian studies the incidence has been reported to vary between 2%-10%.<sup>7,8</sup> Various modalities have been used to identify CAE however coronary angiography is the gold standard for detection of cases.<sup>10</sup>

The other methods utilized include intravascular ultrasound (IVUS), which is an excellent tool for assessing luminal size and characterizing arterial wall changes.<sup>11,12</sup> CAE commonly affects isolated vessels, however all three vessels are also affected in a substantial proportion.<sup>2</sup> Of interest is the diffuse fusiform type of CAE that tends to have more frequently bilateral distribution and association with abdominal aortic aneurysms. It usually coexists with underlying coronary artery stenosis and in patients where it occurs in the absence of stenotic lesions it tends to be diffuse.<sup>2,4,13</sup>

All three coronary vessels can be affected by CAE, but in 75% of patients an isolated artery is ectatic. In patients with concomitant coronary artery disease, the proximal and mid-segments of the right coronary artery are the most frequently involved, followed by the left anterior descending artery and the circum-flex artery.<sup>14</sup>

The specific causative mechanisms of abnormal dilatation of the lumen in CAE are essentially unknown. Elevated C-reactive protein levels may suggest an inflammatory process as a cause.<sup>1</sup> The

co-existence of CAE with obstructive coronary lesions in the great majority of patients and the isolated coronary ectasias have led to the generalised administration of aspirin in all patients with CAE.<sup>15</sup> Current literature suggests that ectatic coronary arteries, even without the presence of coronary stenosis, are subject to thrombus formation, vasospasm, and spontaneous dissection.

This study was done to evaluate the incidence of coronary ectasia and its clinical profile and angiographic characteristics in our Rural area population.

### Patients and Methods

We retrospectively analyzed 869 patients who underwent coronary angiogram at the catheterization laboratory of Department of Cardiology in Rajarajeswari Medical college and Hospital, Bangalore from 1<sup>st</sup> January 2015 to 31<sup>st</sup> November 2017.

### Inclusion criteria

A detailed protocol was filled for each patient which included their name, address, phone number, age sex, hospital number and date of admission. The presenting complaints were noted and risk factors with duration recorded.

Their presenting blood pressures, pulse rate and ECG s were noted. A detailed 2 dimensional echocardiography was also done.

The laboratory parameters, cardiac enzymes (CPK, CPK-MB, TROP-T) were recorded on admission and after 24 hrs, the baseline lipid profile and fasting and post prandial sugars were recorded. The treatment administered to the patient on admission was noted.

All patients underwent conventional coronary angiograms on the SEIMENS ARTIS ZEE cath lab till 31<sup>st</sup> November 2017.

All angiograms were done via the femoral and radial approach using Judkins left and right catheters and Tiger catheters except in special situations where the Amplatz catheters, multipurpose catheters, and LIMA catheter were

used. All conventional views were recorded, (RAO caudal, LAO cranial, LAO caudal, plain LAO, lateral, AP cranial, plain AP, AP caudal, RAO cranial, plain RAO, and a detailed description of the angiography was noted.

They were classified into single vessel disease (SVD), double vessel disease (DVD) and triple vessel disease (TVD) based on the number of vessels affected. Further they were classified according to the vessel affected and the segments with the severity of disease noted according to the segments. Presence of calcification and thrombus was noted

Data were collected from catheterization films, and medical records. Demographic data was collected. Conventional risk factors like hypertension, DM, smoking, and dyslipidemia were noted. The continuous variables were presented as means  $\pm$  standard deviation, and the categorical variables as percentages.

The reasons for catheterisation of these patients were history of angina, previous or an acute myocardial infarction, positive treadmill test and / or presence of multiple coronary risk factors.

#### **Exclusion criteria**

Patients with valvular or congenital heart disease and cardiomyopathies were excluded.

Coronary ectasia was defined by CASS criteria as: Diameter of a vessel in the coronarography up to one and half times the diameter of a adjacent normal branch. Discrete ectasia was defined when the ectatic segment was less than 1 cm and diffuse when it was more than or equal to 1 cm in length. In cases of diffuse ectasia, the diameter of the corresponding artery in a normal angiogram was taken as the reference. Ectasia was classified according to the *Markis classification* (Table 1).<sup>7</sup>

In decreasing order of severity, diffuse ectasia of two or three vessels was classified as Type I; diffuse disease in one vessel and localised disease in another vessel as Type II; diffuse ectasia of one vessel only as Type III, and localized segmental ectasia as Type IV.

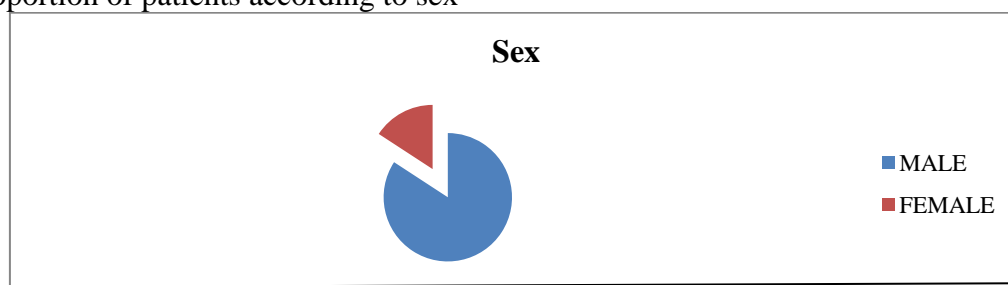
This involved finding the major coronary vessels involved and classifying the ectasia in each vessel involved as diffuse or focal. Assessment of the severity of ectasia and CAD was done visually by experienced cardiologists. Co-existing coronary artery disease with luminal narrowing  $< 50\%$  were considered pure type and patients with  $>50\%$  arterial narrowing were considered as mixed type.

#### **Results**

During the study period, 869 coronary angiograms were performed. There were a total of 576 males (66.3%) and 293 females (33.7%) in the study. One hundred and thirty nine (15.99%) showed coronary ectasia. Most of the patients were in the 51 to 60 years age group followed by the 61 to 70 years and 41 to 50 year age group. The mean age group was 55.75 years with a minimum age of 30 years and a maximum age of 73 years.

A predominance of the male sex was seen 117 (84.20%). And females were 22 (15.80%). 84 (60%) patients were hypertensive, 56 (40.28%) were smoker and 32 (23.02%) were diabetic. Lipid abnormalities were detected in 62 (44.60%) patients with low HDL being the most common abnormality, seen in 76 (55%) patients.

Out of one hundred and thirty nine (15.99%) patients, thirty eight angiograms (27.33%) showed pure and one hundred one angiograms (72.66%) showed mixed type of ectasia. The right coronary artery (RCA) was the commonest affected vessel by ectasia 100 (72%), followed by left anterior descending artery (LAD) in 45 (32.37%) of the patients. Left circumflex coronary artery (LCX) was involved in 22 (15.88%) (Table 1). The distribution of vessels involved as per the Markis classification; type 4 was most common 61 patients (43.88%), followed by Type 1, 44 patients (31.65%). Rest of 24 patients (17.26%) and 10 patients (7.19%) were in type 2 and 3 respectively (Table 2). In a total of 83 patients (59.71%) had good left ventricular (LV) function, 42 patients (30.21%) had moderate left ventricular (LV) function while 14 (10.07%) had severe LV dysfunction.

**Figure :-1** Proportion of patients according to sex**Table:-1** Involvement of Coronary Vessels

Vessels	No of Patients	Percentage of Patients
LAD	45	32.37%
LCX	22	15.88%
RCA	100	72%

**Table 2** Distribution of vessels involved as per the MARKIS Classification

Types	Vessels Involvement Pattern	No. of Patients	Percentage of Patients
Type 1	Diffuse ectasia of two or three vessels	44	31.65%
Type 2	Diffuse disease in one vessel and localized disease in another	24	17.26%
Type 3	Diffuse ectasia of one vessel only	10	7.19%
Type 4	Localized segmental ectasia	61	43.88%

## Discussion

Coronary artery ectasia is considered an uncommon angiographic finding with varying patterns of presentation and prevalence. A number of studies and analysis have been conducted with a view to understand this entity and try to establish an effective line of management.

Tunick et al., found that discrete ectasia develops only in the presence of tight stenosis<sup>16</sup>.

but in our study, however, we identified patients with isolated discrete ectasia without significant co-existing stenosis.

Lipid abnormalities have been incriminated in the genesis of ectasia with one study showing increased prevalence in patients with Familial Hypercholesterolemia and a strong inverse association between High Density Lipoproteins and ectasia<sup>17</sup>. In our study, we also noted that o have low HDL levels is the most common lipid abnormality.

There is no documented influence of age on ectasia according to Sharma et al.<sup>7</sup> Our study also supported that there is no specific difference in the pattern of ectasia between the various age groups. Harikrishnan<sup>8</sup> Demopoulos<sup>2</sup> and found the RCA to be the most commonly involved vessel

followed by the LCX and later the LAD. RCA was the most common vessel involved in our study followed by LAD and Lcx.

The limitations of our study was lack of angiographic follow-up. Furthermore, estimation of stenosis in the presence of ectasia was done visually, not by the quantitative computerised analysis.

**In conclusion**, our study showed a relatively high angiographic prevalence of obstructive coronary artery disease in about 72.66% with a predominant involvement of the RCA (72%) and male population (84.20%). Type 4 was most common type (43.88%) and 59.71% patients had good LV systolic function.

## Future Directions

To identify risk factors that were not looked at in the development of CAE eg racial, dietary, familial etc. We also need to follow up the sepatrients with CAE and look at their long-term (>1 year, 5 years, 10 years) outcomes by conducting non-invasive studies eg. CT Coronary angiographies to identify the changes occurring in the coronary anatomy after few years in patients with CAE.

**References**

1. Swaye PS, Fisher LD, Litwin P, Vignola PA, Judkins MP, Kemp HG et al. Aneurysmal coronary artery disease. *Circulation* 1983; 67:134–8.
2. Demopoulos V, Olympios C, Fakiolas C, Pissimissis E, Economides N, Adamopoulou E, Foussas S, Cokkinos DV. The natural history of aneurysmal coronary artery disease. *Heart* 1997; 78:136–41.
3. Markis JE, Joffe CD, Cohn PF, Feen DJ, Herman MV, Gorlin R. Clinical significance of coronary arterial ectasia. *Am J Cardiol* 1976; 37:217-22.
4. Krueger D, Stierle U, Herrmann G, Simon R, Sheikhzadeh A. Exercise-induced myocardial ischaemia in isolated coronary artery ectasias and aneurysms(‘Dilated Coronaropathy’). *J Am Coll Cardiol* 1999; 34:1461–70.
5. Swanton RH, Thomas MC, Coltart DJ, Jenkins BS, Webb Peploe MM, Williams BT. Coronary artery ectasias: a variant of occlusive arteriosclerosis. *Br Heart J* 1978; 40:393-400.
6. Hartnell GG, Parnell BM, Pridie RB. Coronary artery ectasia – its prevalence and clinical significance in 4993 patients. *Br Heart Journal* 1985; 54:392–5.
7. Sharma SN, Kaul U, Sharma S, Wasiv HS, Manchanda SC, Behl VK et al. Coronary angiographic profile in young and old Indian patients with ischemic heart disease: a comparative study. *Indian Heart J* 1990; 42:365-9.
8. Harikrishnan S, Sunder KR, Tharakan J, Titus T, Bhat A, Shivasankaran S, Francis B. Coronary artery ectasia: angiographic, clinical profile and follow –up. *Indian Heart J* 2000; 52:547-53.
9. Waly MH, Elayda Mac Arthur A, Lee Vei-Vei, El-Said Galal, Reul GJ, Hall RJ. Coronary Artery Ectasia in Egyptian patients with Coronary Artery Disease. *Texas Heart Institute Journal* 1997; 24:349-52.
10. Daoud AS, Pankin D, Tulgan H, Florentin RA. Aneurysms of the coronary artery. Report of ten cases and review of literature. *Am J Cardiol* 1963; 11:228-37.
11. Sanidas EA, Vavuranakis M, Papaioannou TG et al. Study of atheromatous plaque using intravascular ultrasound. *Hellenic J Cardiol* 2008; 49:415-21.
12. Ge J, Liu F, Kearney P, George G, Haude M, Baumgart D et al. Intravascular ultrasound approach to the diagnosis of coronary artery aneurysms. *Am Heart J* 1995; 130:765-71.
13. Swanton RH, Thomas MC, Coltart DJ, Jenkins BS, Webb – Peploe MM, Williams B T. Coronary artery ectasia – a variant of occlusive coronary arteriosclerosis. *British Heart J* 1978; 40: 393–400.
14. Takahashi K Ohyanagi M, Ikeoka K, Tateishi J, Iwa-saki T. Clinical course of patients with coronary ectasia. *Cardiology* 1999; 91: 145–9.
15. Farto e Abreu P, Mesquita A, Silva JA, Seabra – Go-mes R. Coronary artery ectasia: clinical and angiographic characteristics and prognosis. *Rev Port Cardiol* 1993; 12: 305–310.
16. Tunick PA, Slater J, Kronzon I, Glassman E. Discrete atherosclerotic coronary artery aneurysms: a study of 20 patients. *J Am Coll Cardiol* 1990; 15: 279–82.
17. Sudhir K, Ports TA, Amidon TM, Goldberger JJ, Bhu-shan V, Kane JP et al. Increased prevalence of coronary ectasiain heterozygous familial hypercholesterolemia. *Circulation* 1995; 91: 1375–80.