



Granuloma Annulare and Dupuytren Contracture as First Clinical Manifestation of Diabetes Mellitus: A Case Report

Authors

Amandeep Raghuvanshi¹, Sujaya Manvi², Rajni Sharma³

¹Senior Resident, Department of Medicine, DR RPGMC, Tanda (at Kangra), Himachal Pradesh

Email: adraghuvanshi@gmail.com

²Dermatologist, Civil Hospital Palampur, District Kangra, Himachal Pradesh

³Dermatologist, Civil Hospital Solan, District Solan, Himachal Pradesh

Email: dr.rajni07@gmail.com

Corresponding Author

Dr Sujaya Manvi

Dermatologist, Civil Hospital Palampur, District Kangra, Himachal Pradesh

Email: drsujaya23@gmail.com, Contact No- 9418028669

Abstract

Granuloma annulare (GA) is a relatively common idiopathic disorder of the dermis and subcutaneous tissue. The lesions typically appear as papules and plaques with annular margins most commonly on dorsal surfaces of hands, arms and feet. GA has been associated with a variety of comorbidities including diabetes mellitus. Dupuytren's disease (DD) is a common progressive fibrotic condition affecting the palmar and digital fascia. The association of Dupuytren's disease with diabetes mellitus (DM) is well recorded, with a reported prevalence of between 3% and 32%. Here we present a patient who presented with granuloma annulare, on examination had bilateral Dupuytren contractures and was later found to be diabetic.

Keywords- *Granuloma annulare, Dupuytren's disease, annular plaque.*

Introduction

Granuloma annulare is a benign inflammatory disease of the skin. Associations of granuloma annulare with systemic diseases have been described but not consistently confirmed¹. Dupuytren's disease is a fibro proliferative disorder of unknown origin causing palmar nodules and flexion contracture of the digits² and is commonly seen by doctors as an incidental finding. In many cases it is believed to be associated with other medical conditions. It is rare to find these both conditions as presenting complaints of diabetes.

Here we present a case who presented with granuloma annulare, on examination had bilateral Dupuytren's contractures and was later found to be diabetic.

Case Report

A 70-year-old male came with history of skin colored to reddish circular lesions over body from past 5 months. Lesions were asymptomatic and there were no other systemic complaints. On examination, multiple discrete skin colored to erythematous annular lesions were seen over both

upper and lower limbs with no surface changes. On examination of his hands there was flexion deformity involving the ring finger with a band of fibrotic tissue extending from base of the ring finger up to the mid palm in both palms. Biopsy of skin lesions showed infiltrate of histiocytes and lymphocytes scattered between the collagen bundles with separation of collagen fibers by mucin along with sparse perivascular lymphocytic infiltrate and unremarkable epidermis. Patient's investigations revealed increased blood sugar (Fasting blood sugar 173mg/dl) and HbA1C of 7.2%. Patient was diagnosed as Type 2 DM with granuloma annulare with dupuytren contractures and was started on antidiabetic treatment, along with topical clobetasol ointment for granuloma annulare and intralesional triamcinolone for dupuytren contractures.

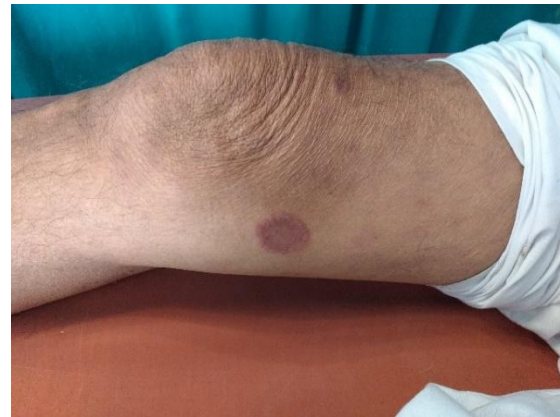

Figure 1-4 showing lesions of granuloma annulare

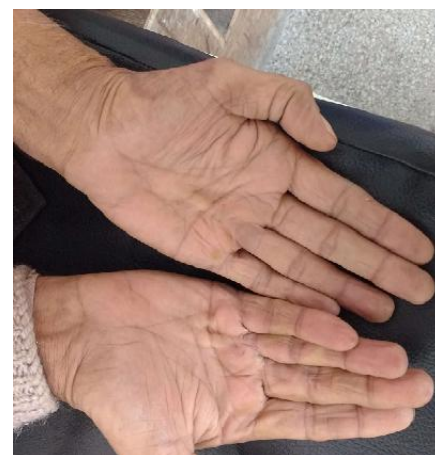
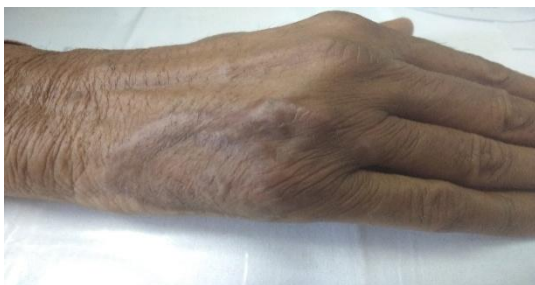
Figure showing bilateral dupuytren's contracture

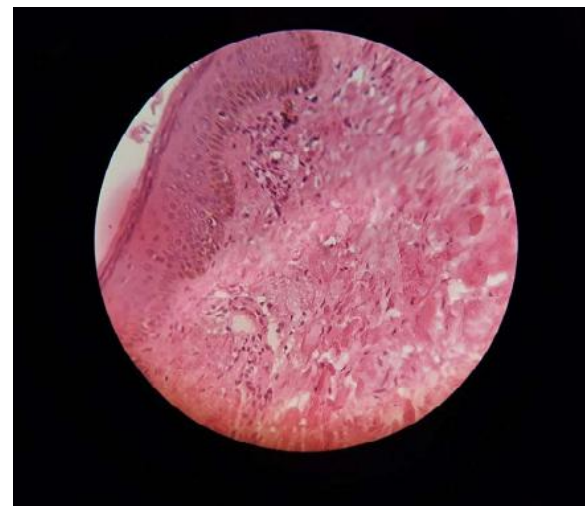
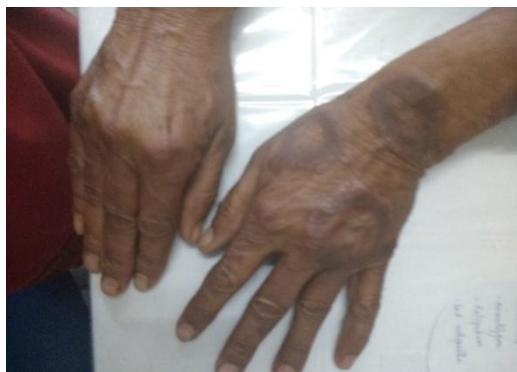
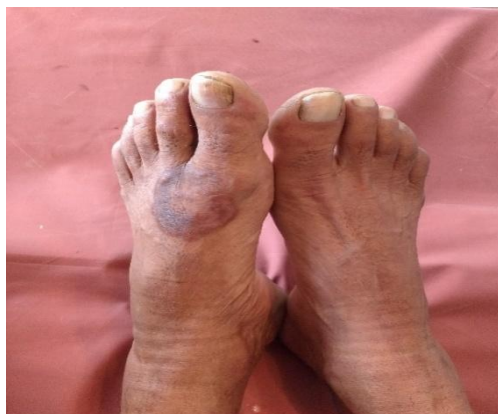
Figure showing histopathology from granuloma annulare lesion.



Discussion

Granuloma annulare (GA) is a relatively common idiopathic disorder of the dermis and subcutaneous tissue with an estimated incidence of 0.1- 0.4%. The lesions typically appear as papules and plaques with annular margins most commonly on dorsal surfaces

of hands, arms and feet¹. The exact cause of the disease is not yet known. Recent studies have pointed to a delayed-type hypersensitivity reaction to an unknown antigen as the probable mechanism underlying the development of GA lesions^{3,4}. GA has been associated with a variety of comorbidities, including diabetes mellitus, thyroid disorders, dyslipidemia, underlying malignancies and tuberculosis^{1,5}. Muehleman and William found a strong association between localized GA and diabetes mellitus in a large population study. Davison et al proposed that early onset and transient nature of granuloma annulare might be responsible for apparent weak association with diabetes mellitus. In spite of these findings, the relationship between GA and diabetes mellitus is still a matter of debate¹. It has been proposed that prolonged exposure to high blood glucose levels may contribute to development of GA. Diabetic patients with GA suffer from persistent and relapsing course with poor treatment outcome⁶. New cases of GA should be screened for diabetes.

Dupuytren's disease (DD) is a common progressive fibrotic condition affecting the palmar and digital fascia and is commonly seen by doctors as an incidental finding. The ring finger is the most frequently involved, followed by the little finger, and then middle finger; the index finger and thumb are rarely involved⁷. Histologically, the cords of DD consist of a dense collagenous matrix containing fibroblasts, arranged along the longitudinal lines of stress. Nodules, which occur within the cords, contain myofibroblasts in bundles of collagen⁸. A genetic susceptibility to the disease is the only generally agreed etiological factor. The incidence of DD also increases with concurrent clinical conditions such as diabetes, smoking, chronic alcoholism, seizures, and infection⁹. The association with diabetes mellitus (DM) is well recorded, with a reported prevalence of between 3% and 32% and an average of around 20%¹⁰. It is common in both type 1 and type 2 diabetes, although it occurs at a younger age in patients with type 1 diabetes¹¹. DD occurring in diabetic patients is different from the condition in non-diabetic patients. There is a lower

incidence of contractures, and fewer cases require surgery. Exact relation of DD and diabetes is not known but both conditions are common and increase in prevalence with age. As a result, DD has been considered as early warning sign of diabetes or a late complication. There is no relation between diabetic control and the severity of contractures. This suggests that diabetes may only be a triggering factor. It may be that microvascular changes in DM encourage local hypoxia, and this could elicit DD in those who would otherwise not have been affected¹².

Conclusion

Granuloma annulare and Dupuytren contracture are rare first presentations of diabetes mellitus and patients presenting with these conditions should be screened for diabetes.

References

1. Alirezaei P, Farshchian M. Granuloma annulare: relationship to diabetes mellitus, thyroid disorders and tuberculin skin test. *Clin Cosmet Investig Dermatol*. 2017; 10: 141–45.
2. Saraf S. Dupuytren's disease. *Indian J Dermatol Venereol Leprol* 2010; 76: 291-93.
3. Fayyazi A, Schweyer S, Eichmeyer B, et al. Expression of IFN gamma, coexpression of TNF alpha and matrix metalloproteinases and apoptosis of T lymphocytes and macrophages in granuloma annulare. *Arch Dermatol Res*. 2000;292(8):384–90.
4. Mempel M, Musette P, Flageul B, et al. T-cell receptor repertoire and cytokine pattern in granuloma annulare defining a particular type of cutaneous granulomatous inflammation. *J Invest Dermatol*. 2002;118(6):957–66.
5. Cyr PR. Diagnosis and Management of Granuloma Annulare. *Am Fam Physician*. 2006;74(10):1729-34.
6. Chutorian BM, Han G, Cohen SR. Dermatological Manifestations of Diabetes Mellitus: A Review. *Endocrinology and*

Metabolism Clinics of North America 2013;
42(4):869-99.

7. Bayat A, McGrouther DA. Management of Dupuytren's disease – clear advice for an elusive condition. *Ann R Coll Surg Engl* 2006;88:3-8.
8. Murrell GA, Hueston JT. Aetiology of Dupuytren's contracture. *Aust N Z J Surg* 1990;60:247–52.
9. Geoghegan JM, Forbes J, Clark DI, et al. Dupuytren's disease risk factors. *J Hand Surg [Br]* 2004;29:423-6.
10. Noble J, Heathcote JG, Cohen H. Diabetes mellitus in the aetiology of Dupuytren's disease. *J Bone Joint Surg* 1984;66:322–5.
11. Arkkila PE, Kantola IM, Viikari JS. Dupuytren's disease: association with chronic diabetic complications. *J Rheumatol* 1997;24: 153–9.
12. Hart MG, Hooper G. Clinical associations of Dupuytren's disease. *Postgrad Med J* 2005;81:425–28.