



## A Study of Variations in the Origin of Obturator Artery in the Human Cadavers (South Indian Population)

Authors

A.Senthamizhchelvan<sup>1</sup>, V.Muniyappan<sup>2</sup>, P.K.Venkadachalam<sup>3</sup>, R.Shanthakumar<sup>4</sup>

<sup>1</sup>Junior Resident, <sup>2</sup>HOD, <sup>3,4</sup>Assistant Professor

Department of Anatomy, Raja Muthiah Medical College, Chidambaram, Tamilnadu, India

### ABSTRACT

Obturator artery is usually a Branch of Anterior division of internal iliac artery. Its frequent variations in its origin and course has drawn attention of Anatomists, pelvic surgeons and Interventional Radiologists. The present study was conducted on Fifty (Formalin fixed) hemi sections of human cadaveric pelvic specimens, which were collected from the cadavers allotted to undergraduate students at department of anatomy, Raja Muthiah medical college, Chidambaram Tamilnadu, during 2015-2017. The pelvis was carefully dissected to study the origin, relations, within the pelvis. The findings were observed and recorded. Origin of obturator artery was from the Anterior trunk of Internal iliac in 64% of specimen and was variable in 36% of specimen. The variations in obturator artery may lead to surgical complications during pelvic surgeries.

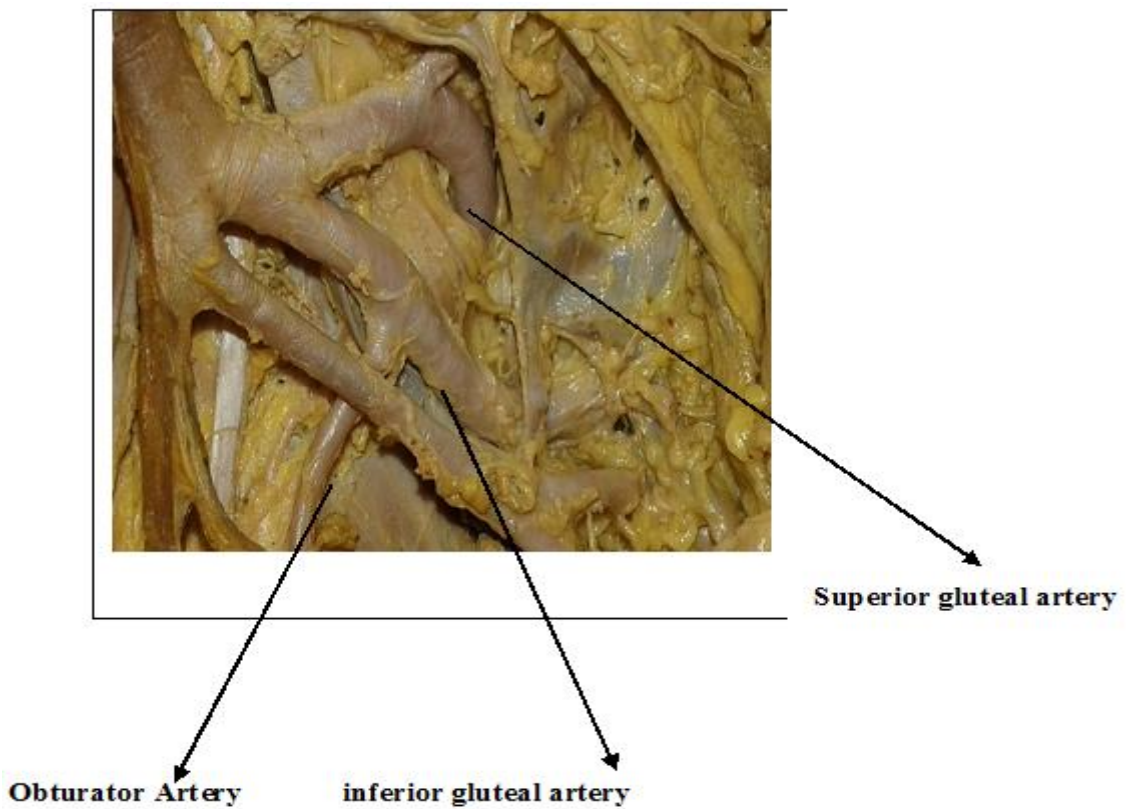
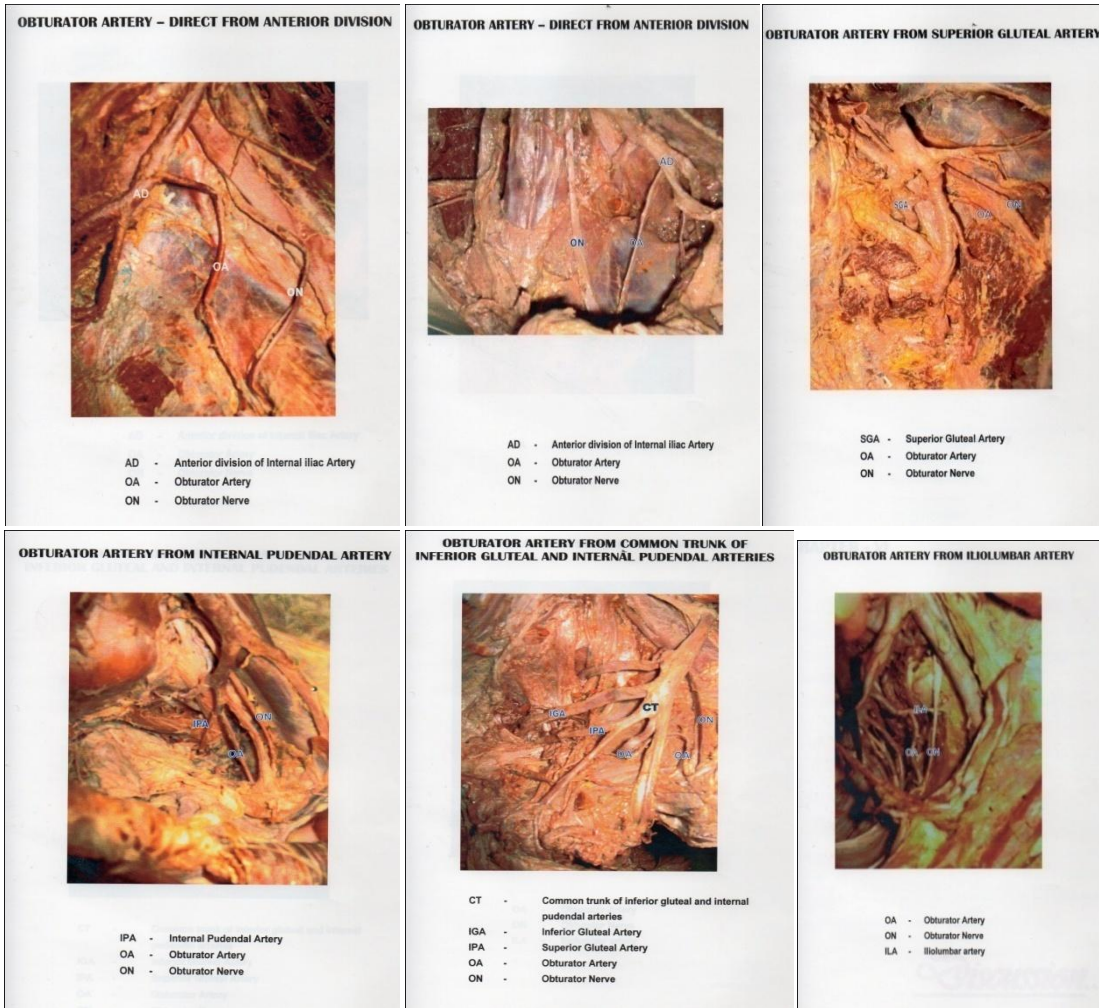
**Keywords:** obturator artery, origins, variations.

### Introduction

Variations in the branching pattern and its practical importance necessary for the surgeon to thoroughly orient himself.<sup>1</sup>In 1963 Lane and alderman reported that haemorrhage was one of the major causes of maternal mortality in the united states.<sup>2</sup>

Obturator artery is one of the branches of Anterior division of Internal iliac artery. It runs forward along the lateral wall of pelvis with the obturator nerve and leaves the pelvis through the obturator canal. The obturator artery runs anteroinferiorly from the anterior trunk on the lateral pelvic wall to the upper part of obturator foramen. It leaves the pelvis through the obturator canal and divides into Anterior and posterior branches. In the pelvis it is related laterally to fascia over obturator internus and is crossed on its medial aspect by the ureter and in the male by the vas deferens. The obturator

nerve is above the artery, the obturator vein below it.<sup>3</sup>Although the obturator artery is considered the branch of the anterior division of internal iliac artery, it shows numerous variations in its origin in about 30% of cases the accessory or abnormal obturator artery replacing the normal branch from the internal iliac in latter instance.<sup>4</sup>such an artery in its passage from inferior epigastric to the obturator foramen usually passes on the lateral side of the femoral ring ie adjacent to the external iliac vein. When it lies at the medial side of the ring, along side of the edge of the lacunar ligament, it is vulnerable to injury or division if the ligament has to be incised to release a strangulated femoral hernia.<sup>5</sup> Because of high prevalence of variations in origin of obturator artery and its association with important structures study on origin of obturator artery is essential.



## Materials and Methods

The present study was carried out on 50 (formalin fixed) hemisections of human cadaveric pelvic specimens, which were collected from the cadavers allotted to under graduate students at department of anatomy, Raja Muthaiya medical college, Chidambaram, Tamilnadu during 2015-2017. They were labeled from 1 to 50 left and Rtside origin of obturator artery was studied and variations in its origin were observed.

## Observations

**Table1:** Origin of Obturator artery.

S.No.	Origin of Obturaorartery	Frequency	Percentage
1.	Separate from the Anterior division	33%	66%
2.	Superior gluteal artery	6	12%
3.	Inferior gluteal artery	3	6%
4.	Internal pudendal artery	2	4%
5.	Common trunk of Inferior gluteal and internal pudendal	4	8%
6.	Iliolumbar artery	2	4%

In this present study commonest source of origin of obturator artery was normal pattern ie separate branch from the Anterior division of internal iliac artery. It was seen 33hemipelvis (66%) specimens out of the 50 specimens studied. Next commoner source of origin of obturator artery was as a branch from superior gluteal artery it was seen in 6hemipelvis (12%) of specimens. other types of variation in the origin of obturator artery are depicted in the table.

## Discussion

Because of variation seen in the iliac arteries many studies are conducted on this by various authors Braithwite<sup>6</sup> (1940) Jastschinski.<sup>7</sup> (1891) Adachi .<sup>8</sup>(1928) Reid J (1836) is credited with the first report on the variations in the origins of the obturator artery. He observed that obturator artery runs a greater risk of being injured during the operation for strangulated femoral hernia .<sup>9</sup>parsons FG and keith A(1897) studied the variations in the origin of obturator artery.<sup>10</sup> In a series of 55 observation, it was observed that obturator artery arouse asa separate trunk from the

Anterior division of internal iliac artery in 20 cases (36.4%) from inferior epigastricarterey in 10 (18.1%) separately from the hypogastric trunk of internal iliac artery in 9(16.4%) from the posterior division of internal iliac artery in 8 (14.5%) from the internal iliac before its division in 5 (9.11%) and in common with middle rectal in 3 cases.

Dubreuil – chambardell (1925) in an extensive study of 440 cases, observed that the obturator artery was a branch of internal iliac artery in 310 cases (70.5%) and a branch of Inferior epigasric artery in 130 cases (29.5%).<sup>11</sup> PickJ. Anason BJ and Ashely FL (1942) in a study of 640 halves, observed an origin of obturator artery from internal iliac in 41.4%, inferior expigastric in 25%, superior gluteal in 10% inferior gluteal in 47%, internal pudendal in 3.8% and external iliac in 1.1% of cases.<sup>12</sup>

Jakubowiaz m (1996) in study of 75 Cases observed that of obturator artery arose from the internal iliac artery at different levels in 92%, from inferior epigastric artery in 2.6% and external iliac artery in 1.3% of cases.<sup>13</sup>

Hong HX et al (2004) OKCUG etal (2004) pongpapongsu etal (2005) and darmanis et al (2007) all observed the importance of “Coronamortis” – anomalous vascular connection between the obturator system and external iliac or inferior epigastric systems, which may be present over the superior pubic ramus in high incidence and which may be prone to Injury and bleeding during an anterior approach to acetabulumor pelvis.<sup>14</sup>

The present study confirms that fact artery shows variations in respect toit source of origin.

The finding of our present study confirms. with those of previous workers on the subject and depicted in table no.2.

Normal origin varies from 25% to 70%.variations can range from 30% to as high as 75%.In our study origin of obturator artery from anterior division is seen in66% of the specimens. the present study is in agreement with Pai et al<sup>15</sup>(2009) and Sharma(2012) et al study<sup>16</sup>.

However the frequency of variation varies in most of the worker study, the inferior epigastric artery is the most frequent source of anobuturaor artery. In sumathilatha et al study variation is observed as high was 31%.<sup>17</sup> and in our study it is nil.

The next common variation of obturator artery is origin from superior gluteal artery and origin of common trunk with inferior gluteal internal pudendal. In our study origin from superior gluteal artery is 12% and from the common trunk is 8%. In our study origin of the obturator artery from inferior gluteal artery is reported 6%, origin from internal pudendal artery is seen in 4% of the specimens and rarely origin of obturator artery from ilolumbar artery 4% reported.

### Conclusion

Approximately 25% - 60% of the population of any part of the world, show variation in origin of obturator artery. In our study obturator artery taking origin from anterior division of internal iliac artery is 66% which is closely corresponds with Sharma et al study report. Among 34% of variant obturator artery, origin for superior gluteal artery is 12%, origin from common trunk of internal pudendal and inferior gluteal is 8%, origin from inferior gluteal artery is 6% origin from internal pudendal artery is 4% and from iliolumbar artery is 4%. with proper knowledge of these variations the operating surgeon, can avoid complications during pelvic surgical procedures.

### References

- Lipschutz B. A composite study of the hypogastric artery and its branches. *Ann surg.* 1918;67(5):584-608.
- Lane R.E. Andleman sl. Maternal Mortality In Chicago. 1956 Through 1960 Preventable Factors And Cause Of death *Am J Obstec Gynecol* 1963 ;85; 61-9.
- Standaring S. *Grays Anatomy.* 40<sup>th</sup> Ed. New York; Elsevier Churchill Livingstone:
- Hollinshed HW (1958) Blood vessels in the elvis in *Anatomy for Surgeons Hoeber-Harper II*: 681-686.
- Romanes GJ (2000) *Cunningham's Manual of Practical Anatomy* New York: Oxford university Press 15: 142-153.
- Braithwaite JL. Variations in origin of the parietal branches of the internal iliac artery. *J AnatSoc of India.* 1952; 86:423-30.
- Jastschinski S. Die typischen Verzweigung formen der Arteria Hypogastrica. *Int J Anat Physiol.* 1891;8: 111-127.
- Adachi B. *Das Arteriensystem der Japaner,* Bd II. Kyoto. Supp. to *Acta Scholae Medicinalis Universitatis Imperialis in Kyoto.* 1928; 9: 1926-1927.
- Reid J 1836 on the varieties of obturator artery *E dinburg med and surg J* 45;65-70.
- Parsons FG, Keith A (1896) Sixth Annual Report of the Committee of Collective investigation of the Anatomical Society of Great Britain and Ireland, 1895-96. *J AnatPhysiol* 31:31-44.
- Dubreil -chambardel L(1925) *Traite des variations du system Arterial variations des Arteries du pelvis et du Membre interieur* masson cie paris.
- Ashley FL. Anson BJ. The hypogastric artery in American whites and Negroes. *Amer JPhys Anthrop.* 1941; 28:381-
- Jakubowicz m, czarniawaka-GRZSISKA m (1996) Variability in origin and topography of the obturator and inferior epigastric arteries. *Folia Morphol(Warsz)* 55(2);121-6
- Hong HX et al (2004) An Anatomical study of corona mortis and its significance *chin J traumatol* 7930;165-9
- Pai MM, Krishnamurthy A, Prabhu LV, Pai MV, Kumar SA and Hadimani GA. Variability in the origin of the obturator artery. *Clinics basic research.* 2009; 64 (9): 897 – 901.

16. Sharma M, Sharma T, Richhpal S, Kaur AA. Variations of obturator artery in Man. Anat physiol. 2012; 2:105.
17. Sumathilatha S, Aristotle S, Sakthivelavan D, Sendiladibban, Jebakkani CF. Variability of the obturator artery and its surgical implications in as south Indian population. Eur J Anat. 2013;17(3) : 159-165.