



Clinicopathological Study of Ectopic Pregnancy

Authors

Medha Pradeep Kulkarni, Kalpana Ranjitsingh Sulhyan, Akshata Jaywant Parab

Corresponding Author

Akshata Jaywant Parab

Department of Pathology, Government Medical College and Hospital, Miraj Maharashtra, India

Contact no: 9975178751, Email: akshuparaba88@gmail.com

Abstract

Pregnancy is a God given boon to any woman but when it gets complicated by means of an ectopic it can be a bane to the conceiving mother with its varied complications to the mother as well as the developing fetus. Ectopic pregnancy (EP) is a major cause of maternal mortality during the first trimester of pregnancy accounting for 10-15% of all maternal deaths globally^[1]. Early diagnosis of ectopic pregnancy reduces the risk of tubal rupture and allows for conservative medical management^[2]. The histopathological examination of the ectopic pregnancy specimen serves two purposes, first it confirms the diagnosis of EP and second it aids in the diagnosis of other findings predisposing to EP like chronic salpingitis and salpingitis isthmica nodosa. Hence the present study was undertaken to study the histopathological findings of EP, correlate these with clinical features and determine the prevalence of pelvic inflammatory disease (PID) in our patients.

The study included 55 cases of EP. Clinical and radiological findings were correlated with the microscopic features in every case.

The study period was 2.5 years from January 2015 to June 2017. 54 out of 55 cases were tubal EP while one was ovarian EP. Common site in the tube was ampulla (49 cases, 89.1%). 31 (57.4%) cases presented with rupture. Chronic salpingitis including follicular salpingitis accounted for 36 cases (62.70%).

Keywords: *ectopic pregnancy, tubal, pelvic inflammatory disease.*

Introduction

Implantation of the blastocyst anywhere outside the uterine cavity is termed as Ectopic Pregnancy (EP). It is derived from the greek word 'ektos' – out of place. It is one of the most life threatening emergency in pregnancy. Clinical presentation of the ruptured EP is with acute abdomen, while in unruptured ectopic pregnancy, there is a triad of abdominal pain, vomiting and amenorrhoea^[3]. Histopathology is necessary to confirm the diagnosis of EP. Also, it allows to identify risk

factors for EP like chronic salpingitis which can be treated and subsequent EP can be prevented. We report the findings of 55 cases of EP in this study.

Material and Methods

The study includes the retrospective and prospective analysis of EPs over the period of 2.5 years from January 2015 to June 2017. The clinical details including the presenting symptoms, parity, age, previous ectopic, previous

surgery, history of use of Intra uterine device (IUCD) were recorded. Radiological findings like the site of the ectopic gestational sac, laterality in case of tubal or ovarian pregnancy and evidence of rupture were correlated with the gross findings. The specimens were fixed in 10% formalin. Sections were taken from dilated portion of the tube, blood clots and segment of the tube medial to the ectopic. Hematoxylin and eosin stained tissue sections were studied microscopically.

Inclusion criteria: All cases of ectopic pregnancy.

Exclusion criteria: All intrauterine pregnancies.

Results

Our study included 55 ectopic pregnancies. Maximum number of patients i.e.21 (38.8%) were in the age group of 26-30 years.

Table no.1 Distribution of patients according to their age.

Age group in years	Cases
15-20	04(7.3%)
21-25	17(30.9%)
26-30	21(38.2%)
31-35	07(12.7%)
36-40	04(7.3%)
>40	02(3.6%)

Table no. 2 Clinical presentation of cases

Symptoms	No. of cases
Acute abdomen	31(57.4%)
PV bleeding	20(37.3%)
PV discharge	05(9.1%)
Amenorrhoea	40(72.7%)
Vomiting	15(27.27%)
Vague pain in abdomen	18(32.72%)

All 31 cases of ruptured EP presented with acute abdomen while vague abdominal pain was the chief complaint in unruptured EP cases.

37 patients were multiparous (parity 2 or more), 10 patients were second gravida and 8 patients were nulliparous.

Table no 3. Risk factors for ectopic pregnancy

Risk factors	Cases
Pelvic inflammatory disease(PID)	24 (43.63%)
PID + Tubal ligation	12(21.8%)
Tubal Ligation	09(16.4%)
Infertility treatment	02(3.6%)
Previous caesarean section	04(7.3%)
Previous ectopic pregnancy	-
IUCD use	-
Congenital abnormalities of the uterus	-
No risk factor	05(0.9%)

36 patients had PID while 21 patients had history of tubal ligation.

Table no 4 Showing site wise distribution of cases

Site	Cases
FALLOPIAN TUBE	54 (98.14%)
Ampulla	49 (89.1%)
Fimbrial end	04(7.3%)
Cornual/interstitial	01(1.8%)
OVARY	01(1.8%)

Fallopian tube was the most common site (54 i.e.98.14%) of EP. Right fallopian tube was involved in 29 cases while left was involved in 25 cases. On gross examination, the involved tube showed localized dilatation with congested blood vessels on the external surface. In unruptured EPs the tube was intact. In 2 such cases the tubal lumen showed gestational sac containing embryo (Fig.1)

In cases of ruptured EPs, the external surface of the tube was hemorrhagic and contents were seen protruding through the rupture site.

Microscopic findings in sections at the site of EP included dilatation of the tube due to gestational sac, decidua, chorionic villi, variable trophoblastic proliferation and intraluminal hemorrhage (fig 2). Many of the villi showed hydropic change or fibrosis. In two cases additionally embryo was seen.

Invasion of the wall of the tube by trophoblast leads to hemorrhagic necrosis resulting in rupture of the tube. This was seen in all the 31 cases of ruptured EPs in our study.

In our case of ovarian ectopic pregnancy, the right ovary was enlarged measuring 3.5x2x 1.6 cm.

External surface was hemorrhagic. Right fallopian tube was unremarkable. Microscopic examination showed chorionic villi and trophoblast admixed with ovarian tissue.

Table no 5 Pathological findings in ectopic pregnancy

Findings	No. of Cases
Chronic salpingitis	31(56.30%)
Follicular salpingitis	05(09.09%)
Mesothelial hyperplasia	05(09.10%)

Sections of the tube medial to the site of EP showed dense and diffuse infiltration of the wall and plicae by lymphocytes and plasma cells in 36 cases. Variable number of mast cells were also seen. The inflammatory infiltrate extended to the parametrium and serosa thus constituting pelvic inflammatory disease (PID). In 5 out of these 36 cases there was plical fusion dividing the tubal lumen into multiple epithelium lined channels – follicular salpingitis (Fig. 3). Five cases showed mesothelial hyperplasia.

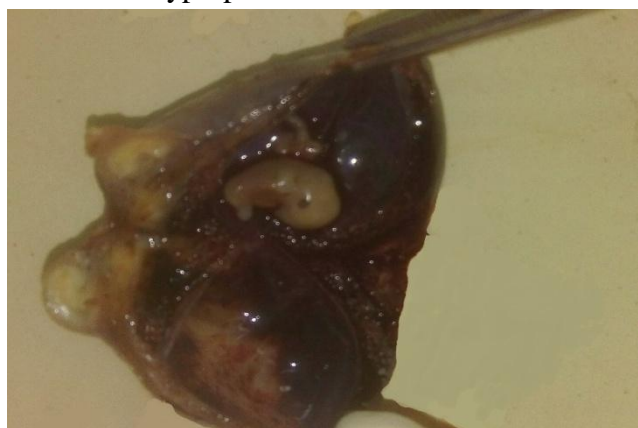

Fig. 1 Gross photograph showing dilated fallopian tube with an embryo.

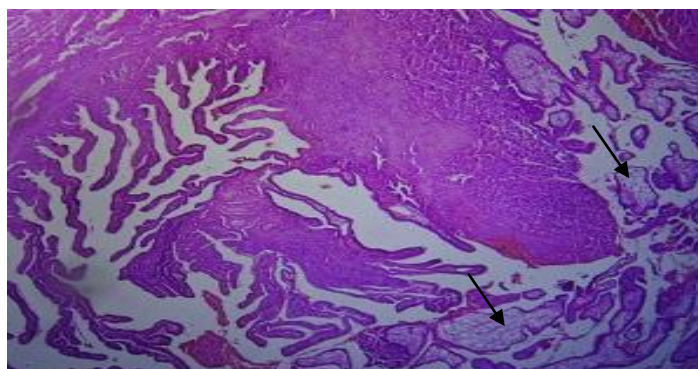


Fig.2 Microphotograph showing chorionic villi in the lumen of fallopian tube (arrow) Left side shows plicae (H&E x 40)

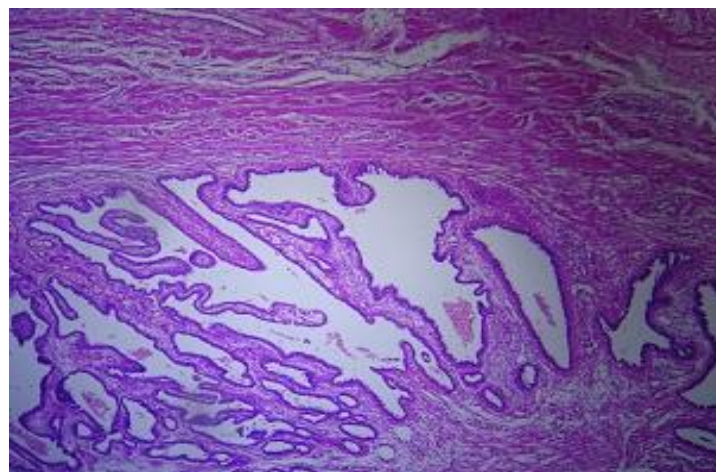


Fig. 3 Photomicrograph showing fallopian tube with fusion of plicae {follicular salpingitis} (H&Ex40)

Discussion

Ectopic pregnancy is a common obstetrical disorder in early pregnancy and remains an important cause of maternal morbidity and mortality.

The common age group involved was 26-30 years (38.8%) which is similar to the observations by Sindhura M et al (40.50%)^[5] Samiya Mufti et al (55.25%)^[6] and Gorva A et al (60.86%)^[7]. However maternal age is not an independent risk factor for ectopic.

Table no 6 Comparison of age of patients in our study v/s other studies.

Age group in years	Present study	Sindhura M et al (2017)	Yadav DP et al (2016)	Samiya Mutli et al (2012)
15-20	04 (7.3)	04 (5.06)	09 (11.25)	
21-25	17 (30.9)	18 (22.78)	29 (36.25)	23 (20.17)
26-30	21 (38.2)	32 (40.50)	22 (27.25)	63 (55.25)
31-35	07 (12.7)	20 (25.31)	14 (17.5)	19 (16.66)
36-40	04 (7.3)	05 (06.32)	06 (7.5)	07 (06.14)
>40	02 (3.6)	-	-	02 (1.75)

(Figures in brackets indicate percentage.)

The classical triad of ectopic is abdominal pain, PV discharge and amenorrhoea^[4]. In our study all cases of ruptured EP presented with acute abdomen. Unruptured EPs presented with vague abdominal pain. Yadav DP et al^[8] reported 69 cases with pain in abdomen.

Majority of the cases in the study were multiparous, 37 out of 55 (85.1%). Similar results have been reported by Yadav DP et al (72.5%)^[8], Chate MT^[9] and Sindhura M et al^[5]. Pantl et al^[11] and Majhi AK et al^[10] however, have reported maximum incidence of EP in nulliparous women.

In our study 54 out of 55 cases of ectopic pregnancy involved the fallopian tube and one case of ovarian ectopic was encountered.

Implantation in case of tubal EP occurs most commonly in the ampulla^[4]. In our study, 49 cases (88.88%) involved the ampulla followed by the fimbrial end in 4 cases (7.3%) and cornua in one case (02%). Similar findings have been reported in other studies also^[5,6,8,12]. In a study of 80 cases of EP, Yadav DP et al^[8] have reported 75 cases of tubal EP out of which 41 were ampullary, 20 isthmic, 13 infundibular/fimbrial and one cornual/interstitial. Remaining 5 included, 2 cases each of ovarian pregnancy and rudimentary horn pregnancy along with a case of secondary abdominal pregnancy.

Table no. 7 Comparison of sites of ectopic pregnancy

Site	Present study	Sindhura M et al (2017)	Bouyer J et al (2002)
Fallopian Tube	54 (98.14)	75 (96.15)	1603 (95.4)
Ampulla	49 (89.1)	59 (74.68)	1175 (69.9)
Fimbrial end	04 (7.3)	06 (7.59)	186 (11.07)
Cornual	01 (1.8)	03 (3.79)	41 (2.4)
Isthmus	-	07 (8.86)	201 (11.9)
Ovary	01 (1.8)	03 (3.79)	54 (3.2)
Abdominal	-	-	22 (1.3)

(Figures in brackets indicate percentage.)

The right fallopian tube was involved in 29/55 (52.7%) cases similar to the observations by Sindhura M et al (69.62%)^[5]

The outcome of the tubal ectopic varies from tubal abortion with expulsion of embryo from fimbrial end, tubal hemorrhage and tubal rupture^[4]. Tubal hemorrhage is an invariable accompaniment of tubal EP and results from destructive invasion of

the trophoblast in the vessels and muscle of the tubal wall which lacks the buffering of decidualized endometrium in uterine pregnancy. In the present study, all 55 cases showed tubal hemorrhage. Tubal rupture is a consequence of hemorrhagic necrosis of the tubal wall^[4] which was noted in all the 31 cases of ruptured EP.

Ovarian EP constitutes 3% of all EPs. It may be subclinical or may present with acute abdomen. Diagnosis of ovarian EP is based on Spiegelberg's criteria. Ovarian EP can be primary or secondary. Primary results from fertilization of the ovum within the follicle and this is postulated to be a consequence of ovulatory dysfunction. Secondary ovarian EP occurs when fertilization occurs in the tube and the conceptus is expelled out, to be implanted in the ovarian stroma^[13]. Review reports reveal that majority of ovarian EPs get terminated in the first trimester. Only one case of ovarian EP that progressed to full term has been reported^[14]. We had one case of ruptured ectopic right ovarian pregnancy.

Risk factors for tubal pregnancy are pelvic inflammatory disease, history of smoking, prior tubal surgery, salpingitis isthmica nodosa, history of infertility treatment, age and parity of the patient^[4]. These factors were evaluated in all cases. Detailed gross and microscopic examination of every specimen was done. The term PID implies chronic salpingitis with involvement of the surrounding structures including ovary and parametrium^[4]. We had 36(65.45%) cases with PID including 31 cases of chronic salpingitis and 5 cases of follicular salpingitis. Yadav DP et al also found PID as the most common risk factor for ectopic tubal pregnancy^[8]. Salpingitis is usually bilateral and a second ectopic in the contralateral tube is more likely in such patients.

We found mesothelial hyperplasia in 5 cases. Deciliation of epithelium of the fallopian tube was not seen in any of our cases contrary to the findings by Sharma R and Biligi D^[15].

Ectopic pregnancy can be a complication of failed tubal ligation. The 10 year cumulative probability

of ectopic pregnancy for all methods of tubal sterilization was 7.3 per 1000 procedures which varied according to method of sterilization and age of the women^[16]. We had 21 cases of EP with history of tubal ligation.

Recurrence rate of EP with history of salpingostomy ranges from 15-20% depending on the integrity of the contralateral tube. Two previous EPs increase risk of recurrence to 32%^[17,18]. Our study did not have previous history of ectopic pregnancy in any of the cases.

Although IUCD was implicated as one of the risk factors for EP in the past, current studies have reported no association between IUCD and EP^[4]. None of the patients in our study gave history of contraceptive usage.

We had two cases with history of previous cesarean section but cesarean section is not an independent risk factor for ectopic tubal pregnancy^[20].

Conclusion

Histopathology plays a crucial role in confirming the EP and identification of risk factors especially PID which could be the cause of present EP and potential source of subsequent EP on account of its frequent bilaterality. Early diagnosis of EP can prevent rupture and unruptured EP can be treated conservatively. Hence, EP must be considered in the differential diagnosis of acute abdomen especially in women of reproductive age group.

Bibliography

1. Mahboob U, Mazhar SB. Management of ectopic pregnancy: a two year study. *J Ayub Med Coll Abbottabad*. 2006;18:34-7
2. Barnhart KT. Ectopic pregnancy. *N Engl J Medicine*. 2009;361:379-87.
3. Ectopic Pregnancy. In William's Obstetrics. Cunningham GF, Leveno KJ, Bloom SL, Spong CY, Hoffman BL, Dashe JS, Casey BM, Sheffield JS (eds). 24th edition 2014 McGraw-Hill, USA pp377-386.
4. Zheng W, Robboy SJ. Fallopian Tube. In Robboy's Pathology of the Female Reproductive Tract. Robboy SJ, Muttler GL, Prat J, Bentley RC, Russel P, Anderson MC (eds). 2nd Edition 2009, Churchill Livingstone. Elsevier, China. pp487-498.
5. Sindhura M, Sailatha R, Famida AM, Vijayalakshmi K, Sathiya S, Renuka S. Trends in ectopic pregnancy: a retrospective clinical study of 79 cases. *Int J Reprod Contracept Obstet Gynecol* 2017;6:3009-13.
6. Mufti S, Rather S, Mufti S, Rangrez RA, Wasiqa, Ectopic pregnancy :An analysis of 114 cases. *JK-Practitioner* 2012;17:20-23.
7. Gorva A, Karre S, Veergandham S. Histopathological Study of Ectopic Pregnancies – A Rare case of Bilateral Ectopic Pregnancy *IOSR-JDMS* 2015;14:42-45
8. Yadav DP, Bhati I, Bhati BS. Ectopic pregnancy: a comprehensive analysis of risk factors and management. *Int J Reprod Contracept Obstet Gynecol* 2016;5:2723-7.
9. Chate MT, Chate B, Chate. Clinical study of ectopic pregnancy. *Int J Reprod Contracept Obstet Gynecol* 2017;6:3498-3501.
10. Panti A, Ikechukwu NE, Lukman OO, Yakubu A, Egundu SC, Tanko BA. Ectopic pregnancy at Usmanu Danfodiyo University teaching hospital Sokoto: a ten year review. *Annals of Nigerian Medicine*. 2012;6:87-91
11. Majhi AK, Roy N, Karmarkar RS, Banerjee PK. Ectopic pregnancy -5 year experience. *J Obstet Gynecol Ind*. 2002;52:55-8.
12. Bouyer J, Coste J, Fernandez H, Pouly JL, Spira NJ. Sites of ectopic pregnancy : a 10 year population based study of 1800 cases. *Human Reproduction* 2002; 17: 3224-3230.
13. Das S, Kalyani V, Lakshmi V, Harendra kumar ML. Ovarian pregnancy. *IJPM* 2008;51: 37-38.
14. William PC, Malvar TC, Icnest JR. Term ovarian pregnancy with delivery of live

- female infant. *Am J Obstet Gynecol*; 1978;10:132-4.
15. Sharma R, Biligi D. A study of histopathological changes in fallopian tubes in ectopic pregnancy. *Int J Cur Rev* 2015;7:54-8.
 16. Peterson HB, Xia Z, Hughes JM, Wilcox LS, Taylor LR, B.S, Trussel J. The risk of ectopic pregnancy after tubal sterilization. *N Eng J Med* 1997;336:762-767.
 17. Hankins GD, Clark SL, Cunningham FG, Gilstrap LC. Ectopic pregnancy. In: *operative obstetrics*. Norwalk, Conn: Appleton & Lange, 1995:437-56
 18. Clausen I. Conservative versus radical surgery for tubal pregnancy. A review. *Acta Obstet Gynecol Scand*. 1996;75:8-12.
 19. Edelman DA, Porter CW. The intrauterine device and ectopic pregnancy: Contraception Jul;36:85-96
 20. O'Neill SM, Khashan AS, Kenny LC, Geene RA, Henriksen TB, Lutomski JE, Kearney PM. Cesarean section and subsequent ectopic pregnancy: a systematic review and meta-analysis. *BJOG Int J Obstet Gynecol* 2013;120:671-680.