



## Clinical Presentation, Evaluation and Management of Liver Abscess

Author

**Dr Rajiv Srivastava**

Govt Medical College Haldwani

### Abstract

*Liver abscess is a major tropical disease of the gastrointestinal system. The liver abscess is mainly classified into amebic and pyogenic. Pyogenic liver abscess which used to be mainly tropical in location is now more common due to increased biliary interventions, stenting, A total of 88 patients who were diagnosed to have liver abscess were included in my study after thorough clinical evaluation and ultrasonographic study. In our study most common age group effected with this disease is between 16-45years almost 67% of the total. Male prepondence with 68.1%. of cases. Right lobe of the liver was found to be involved in 62,2% of cases and both lobe was involved in 12,5% of cases..It was single abscess cavity that superseded multiple cavities with its presence in 64.7% of cases and the size of largest cavity in largest diamension was found to be less that 5cm in 60.2% cases, between 6-10cm in 27.7%cases and size more than 15cm in3.4% cases. Patients with size less than 5cm responded well to conservative management. Mortality was 3.4% inpatient who did not respond to any treatment..51.1% of cases could be managed conservatively and did not need any aspiration. In 37.03% of cases ultrasonographic aspiration was done either in one sitting or multiple sitting and these patients responded well and duration of stay in hospital could be reduced. Average patients required admission between 5 to 10 days for symptomatic relief either conservatively or USG guided aspiration but few patients who showed slow response or needed multiple aspiration had to stay between 11-15 days (21.5%) of cases. We also found that it was non vegetarians who had more incidence of liver abscess 56.18% of cases. History of alcohol intake was found in 35% of cases.*

**Keywords:** liver abscess, pyogenic liver abscess, amebic liver abscess, ultrasonography, ultrasonographic guided aspiration, surgical drainage.

### Introduction

Liver abscess is collection of pus in any lobe of the liver, two commonest cause of liver abscess are Ameobic and pyogenic liver abscess, ameobic liver abscess is more common than pyogenic liver abscess and is third most common cause of death worldwide after Malaria and schistosomiais<sup>1</sup>. With recent developments of more advance techniques of ultrasonography it has become more easy to diagnose and do therapeutic interventions and hence there is decrease in morbidity and mortality and helps in early recovery.<sup>2</sup>

The three major forms of liver abscess, classified by etiology, are as follows:

1. Pyogenic abscess, which is most often polymicrobial,
2. Amebic abscess due to *Entamoeba histolytica*
3. Fungal abscess, most often due to *Candida* species,

### Pyogenic liver abscess-

There are many potential causes of pyogenic liver abscesses,<sup>3</sup> including

- Biliary system-cholangitis, biliary obstruction
- Portal circulation-intra abdominal infection
- Arterial circulation-bacteraemia, systemic infection
- Trauma-Direct exposure, perforated ulcer
- Cryptogenic-unknown

The most common bacteria that cause liver abscesses are:

- Bacteroides
- Enterococcus
- *Escherichia coli*
- *Klebsiella pneumoniae*
- *Staphylococcus aureus*
- Streptococcus

In most cases, more than one type of bacteria is found.

#### **Amoebic Liver abscess-**

Amoebic liver abscess is an uncommon but potentially life-threatening complication of infection with the protozoan parasite *Entamoeba histolytica*. *E. histolytica* is widely distributed throughout the tropics and subtropics,<sup>4</sup>. The parasite is transmitted via the fecal-oral route, and once it establishes itself in the colon, it has the propensity to invade the mucosa, leading to ulceration and colitis, and to disseminate to distant extra intestinal sites, the most common of which is the liver.

*Life cycle of E. histolytica*. Infection occurs when mature cysts are ingested, typically through fecally contaminated water or food, most frequently in the developing world. When the parasite reaches the small intestine, excystation occurs, releasing trophozoites (the 'feeding stage' of the parasite which then penetrate the colonic mucosa. There they can cause flask-shaped colonic ulcerations and gain access to the portal venous system to infect the liver, brain, lungs, pericardium and other metastatic sites. In the liver, the amoebae generate an inflammatory reaction and cause necrosis of hepatocytes, producing an abscess. Interestingly, there is a relative paucity of inflammatory cells from biopsy specimens, which

is believed to be due to lysis of cells by *E. histolytica*

#### **Clinical presentation**

##### **Sign and symptom of liver abscess**

Stabbing pain over upper right hypochondrium

Fever

Nausea

Vomiting

Chills

Sweating

Diarrhea

Clay colored stool

Dark urine

Generalized Malaise

Lethargy

Breathlessness

Cough

Jaundice

Loss of appetite

Wt loss

#### **In complicated case**

Mental changes such as confusion, delirium, hallucinations, delusions

High grade fever

Seizures

Trachycardia

Dyspnoea

Severe pain abdomen

Peritonitis.

#### **Diagnosis**

##### **Various tools used in diagnosis-**

Ultrasonography

Ct scan/MRI

Complete blood count

Liver abscess aspirate for routine and culture and sensitivity

Fibroscan of liver

Liver function test

Stool examination

#### **Role of radiological investigations-**

**Ultrasonography-(USG)** is an excellent imaging modality for the initial evaluation of hepatic abscess with sensitivities reported between 85-95%, Ultrasonography often is used as a preliminary screen to confirm the presence of a suspected

space occupying lesion in liver. The appearance on USG varies according to the stage of evolution of the abscess. Initially the abscess is hyperechoic and indistinct, but with maturation and pus formation, it becomes hypoechoic with a distinct margin. When the pus is very thick, a fluid-containing lesion may be confused with a solid lesion on USG.<sup>5</sup>

**CT scan**-This is procedure of choice for the initial assessment of a suspected pyogenic liver abscess and should be performed in all cases of liver abscess as diagnosed in ultrasonography. Ct scan can detect ulcers even smaller than 0.5 cm which is difficult in (UGS) if contrast is used its sensitivity is approaching 95% in comparison to USG it can delineate small lesions which are near diaphragm and abscess in fatty liver, finally CT also visualize co existing intra abdominal pathology including pancreatic mass, colon cancer, diverticulitis, appendicitis and intraperitoneal abscess

**MRI**- Can be used in few cases it can identify abscess less than 0.3 cm and can well delineate hepatic venous anatomy, so this can prove useful in patients that require hepatic resection to treat hepatic abscess.

### Treatment options

#### Pyogenic liver abscess

Although the identification of the specific microorganism involved in the pyogenic liver abscess requires appropriate culture information, initial empiric treatment with antibiotics is prudent in most cases. If appropriate culture sensitivity is available then suitable antibiotic cover can be initiated or else a broad spectrum coverage with a antibiotics effective against gram negative rods, streptococcal species and anaerobes shall be initiated and continued until definitive organism have been isolated and there sensitivity established. Antifungal therapy shall be started in those patients with positive fungal identification under microscopic examinations. Ideal is to start with regimen containing combination of penicillin (ampicillin), an aminoglycoside (gentamicin/amikacin/tobramycin) and metronidazole these

will cover majority of the organism found in culture report. Few recently used combinations are cephalosporines, ticarcillin salbactam. Piperacillin/clavulanate. Conventionally a prolonged course of antibiotics lasting for 4 to 6 weeks is required for patients with a pyogenic liver abscess, with adequately drained abscess only two weeks of therapy is found to be sufficient.

**Amoebicidal agents**

1. Metronidazole 750 mg orally three times a day for 5–10 days; 500 mg IV every 6 hours for 5–10 days 30–50 mg/kg/d for 5–10 days orally in three divided doses; 15 mg/kg IV load followed by 7.5 mg/kg every 6 hours (maximum, 2250 mg/d) side effects -Psychosis, seizures, Peripheral neuropathy and a metallic taste
2. Chloroquine (base) (used as an alternative or adjuvant) 600 mg/d orally for 2 days, then 300 mg/d orally for 14 days 10 mg/kg of chloroquine base Diarrhoea, abdominal cramps, cardiotoxicity, seizures and hypotension

3. Tinidazole (Preferable to Chloroquine) 2 gm/day for 3-5 days Luminal agents (Used to eradicate intestinal colonization after Amoebicidal treatment)

4. Paromomycin 25-30 mg/kg/d orally for 7 days in three divided doses 25 mg/kg/d orally for 7 days in three divided doses (maximum, 2 g/d) side effect- Diarrhoea,

5. Iodoquinol 650 mg orally three times a day for 20 days 30–40 mg/kg/d for 20 days in three divided doses (maximum, 2 g/d) Contra indicated in patients with Hepatic insufficiency or hypersensitivity

6. Diloxanide furoate (Indicated in patients who fail to respond to Iodoquinol and Paromomycin) 500 mg orally three times a day for 10 days 20 mg/kg/d in three divided doses

7. Nitroimidazoles including metronidazole are effective in over 90%. Therapy should continue for at least 10 days. Relapses have been reported with this duration and the drug may be administered for up to 3 weeks.

#### Percutaneous drainage

Advances in radiology since 1970's including both imaging and interventional techniques,

resulted in the introduction of radiologically guided aspirations and drainage of intra-abdominal abscess. It has revolutionized the treatment of hepatic abscess and decreased morbidity and mortality. USG /CT guided aspiration has now become gold standard in treatment of liver abscess. The highest success rate is 70-90 %<sup>6-7</sup>. mostly a pig tailed catheter is left in-situ and complete drainage is observed in 10 -14 days. In amoebic liver abscess its helpful in management of its complications aroused due to its rupture in pericardial, pulmonary or peritoneal spaces. There are few contraindications for percutaneous drainage- Absolute contraindications are- associated biliary or intra abdominal pathologies requiring simultaneous operative interventions, coagulopathies and anatomical inaccessibility. Procedure related morbidity and mortality is low found to be around 3-4%., Few complications of drainage are –Sepsis haemorrhage, contamination of pleural or peritoneal cavities and bowel perforation.

**Surgical treatment:** The only indication of primary surgical treatment of liver abscess is in patients with an initial presentation with intraperitoneal rupture or in patients with multiple abscesses above an obstructed system that cannot be negotiated by non-operative means. Open operation is also indicated when there is failure of non-operative treatment and for complications of percutaneous drainage, such as bleeding or intraperitoneal leakage of pus. Surgery is required to treat any underlying causative disease if necessitated, particularly those pertaining to hepatobiliary area<sup>8</sup>.

**Aims and Objective-** To study the presentation, evaluation and management of cases of liver abscess that came to Govt Medical college Haldwani during period of 1 year i.e from June 2016 to June 2017, with special emphasis to the role of ultrasonography in its diagnosis and management.

## Material and Method

Study was conducted in the department of surgery of Govt Medical College Haldwani. Patients with confirmed diagnosis of liver abscesses as diagnosed by ultrasonography were included in my study. A total of 88 patients are included in this study

**Inclusion criteria-** All confirmed cases of liver abscess who were admitted irrespective of age and sex.

Confirmation achieved by clinical evaluation and ultrasonographic studies.

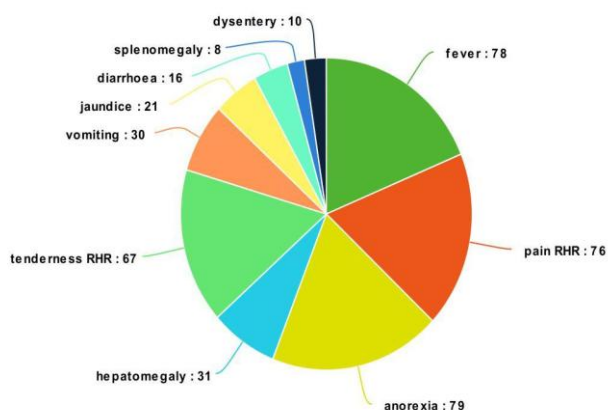
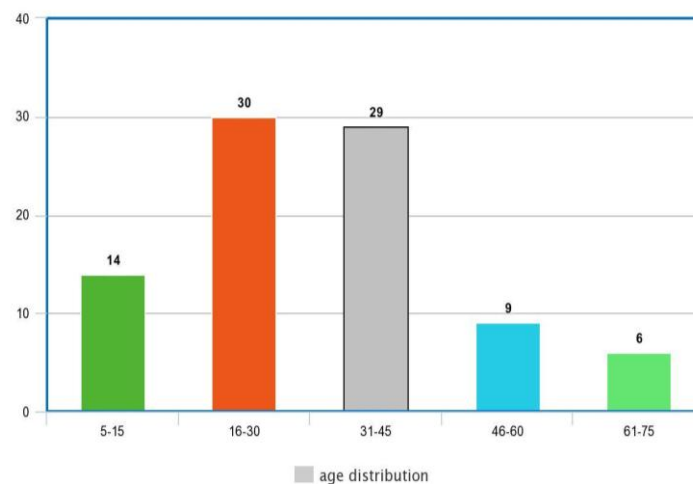
**Exclusion criteria-** patients who had lesions in liver on ultrasonography but confirmation of liver abscess was not given by radiologist

Patients who took discharge on personal request or left against medical advice during treatment

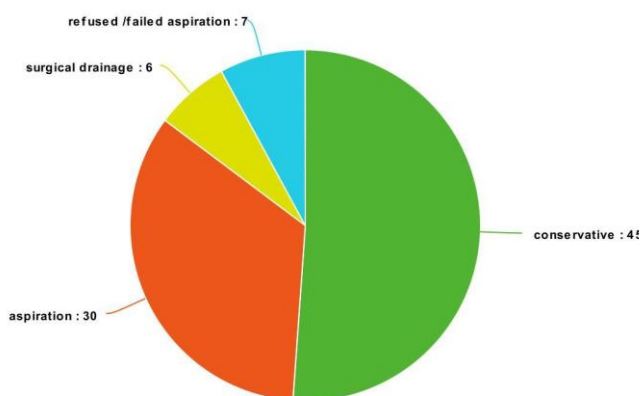
## Results

A total of 88 patients who were diagnosed to have liver abscess were included in my study after thorough clinical evaluation and ultrasonographic study. In our study most common age group effected with this disease is between 16-45 years almost 67% of the total. Male prepondence with 68.1%. of cases .Right lobe of the liver was found to be involved in 62,2% of cases and both lobe was involved in 12,5% of cases..It was single abscess cavity that superseded multiple cavities with its presence in 64.7% of cases and the size of largest cavity in largest dimension was found to be less than 5cm in 60.2% cases, between 6-10cm in 27.7% cases and size more than 15cm in 3.4% cases Patients with size less than 5cm responded well to conservative management. Mortality was 3.4% in patient who did not respond to any treatment. 51.1% of cases could be managed conservatively and did not need any aspiration. In 37.03% of cases ultrasonographic aspiration was done either in one sitting or multiple sitting and these patients responded well and duration of stay in hospital could be reduced .Average patients required admission between 5 to 10 days for symptomatic relief either conservatively or USG guided aspiration but few patients who showed

slow response or needed multiple aspiration had to stay between 11-15 days (21.5%) of cases. We also found that it was non vegetarians who had more incidence of liver abscess 56.18% of cases. History of alcohol intake was found in 35% of cases. Aspirate culture and sensitivity was found to be sterile in 21 cases out of 30 aspirations done (70%)



Signs and symptoms(number of patients out of 88 patients)



Treatment received by patient (88 patients)

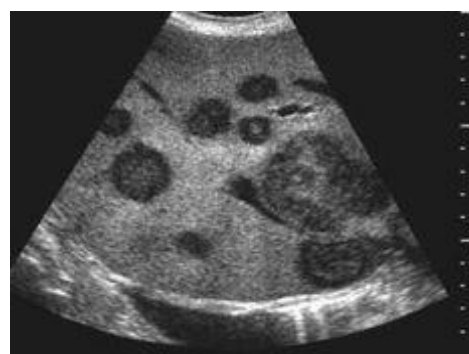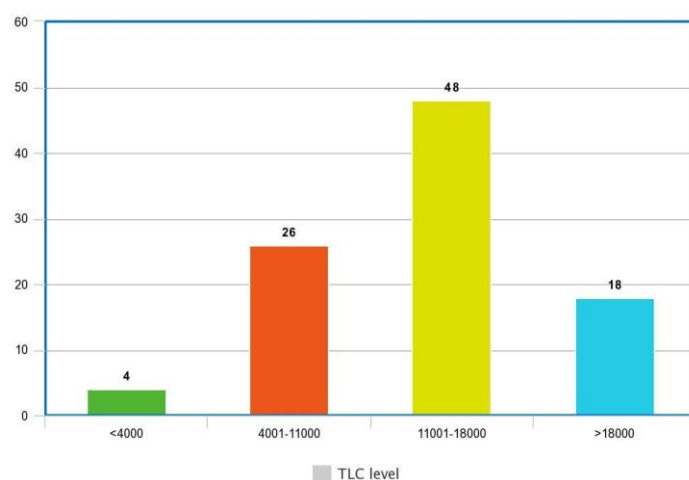
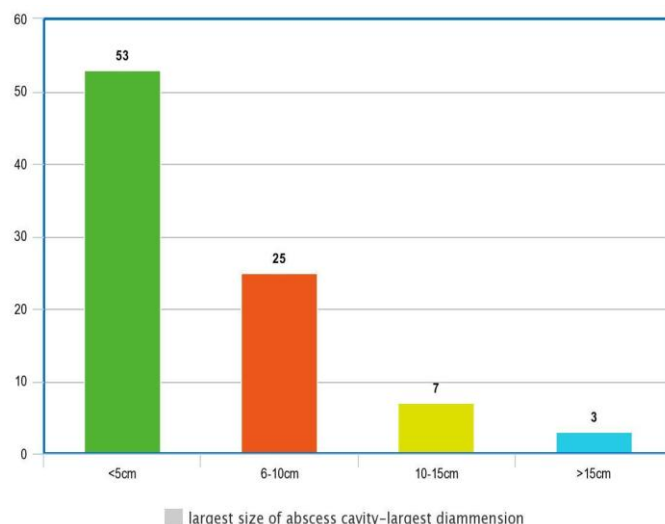


Figure 1 Multiple liver abscess( USG)

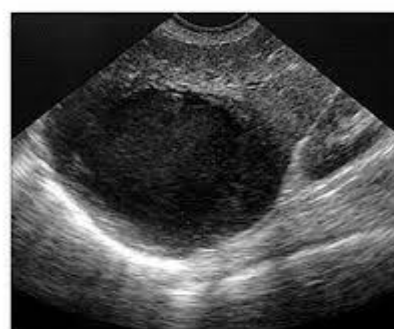

Figure 2 Solitary liver abscess (USG)



## Discussion

The most common cause of hepatic abscess is thought to be from biliary disease. Abscesses can also develop from hematogenous spread where intestinal disease such as inflammatory bowel disease, diverticulitis, and appendicitis can all seed to the liver via the portal venous system. Even trauma, both blunt and penetrating, has been shown to result in hepatic abscesses in some rare cases. The great majority of abscesses however, develop without a source ever being identified. These are known as cryptogenic abscesses.<sup>9-10</sup>

Certain risk factors for abscess development have been described, including recent bowel surgery, diabetes, alcoholism and other immuno-compromised states such as human immunodeficiency virus infections.

The most frequently isolated bacteria on pus culture was *Escherichia coli* (44%) closely followed by *Klebsiella* species (33%). *Escherichia coli* has been reported to be the organism most frequently grown in western series. However, Asian series have reported *Klebsiella* to be the most frequently isolated bacteria.<sup>11</sup> For patients who have recently visited, or immigrated from developing nations, abscess formation with *Entamoeba histolytica* can still be seen secondary to fecal-oral contamination.

Generally, patients with hepatic abscess present with fevers and abdominal pain although symptoms can include a broad range of complaints from nausea and vomiting to malaise and weight loss. In some cases, jaundice may be the first and only clinical manifestation of the disease. Apart from jaundice, physical examination may show hepatomegaly and right upper quadrant pain although this is seen in only about 50% of cases.<sup>12</sup> In some situations hepatic abscess can rupture and spread infection into the thoracic cavity, or even lead to the formation of hepato-bronchial fistulae. The common symptoms and signs of liver abscess in our study were fever (88%), right upper quadrant pain and tenderness (93%) and hepatomegaly (80%). The clinical presentation of the patients studied in our series

was similar to the descriptions in previous reports. The common symptoms and signs of liver abscess in our study were fever (88%), right upper quadrant pain and tenderness (93%) and hepatomegaly (80%).<sup>13-15</sup>

The initial radiologic approach to diagnosis often includes a chest radiograph. A chest radiograph may show an elevated hemi-diaphragm, pleural effusion, atelectasis or right lobar consolidation, but is normal in over half of patients. The diagnosis of hepatic abscess has been aided greatly by the increase in availability of ultrasonography and CT. Both are sensitive tests for the detection of hepatic abscess and have contributed to the trend of reduced morbidity.<sup>12</sup> Contrast-enhanced CT has slightly increased sensitivity compared with ultrasound and may offer benefit in drainage procedures. Ultrasound is ideal in the initial evaluation of the biliary tree.<sup>13</sup> If biliary disease is a suspected source, endoscopic retrograde cholangiopancreatography or magnetic resonance cholangiopancreatography may be indicated. Given these diagnostic options, a multimodal approach is often required for both diagnosis and treatment.<sup>16-19</sup>

Ultrasound has shown a sensitivity range of 86 to 96%.<sup>16</sup> Findings on ultrasound will change depending on the stage of the disease but most commonly include a complex cystic mass with irregular margins and posterior acoustic enhancement. The contents of the structure may take on a more variable echotexture as the untreated abscess progresses where fluid-fluid interfaces and septations become more apparent.

Main treatment goals include drainage of the abscess and antibiotic eradication of the pathogen involved. Initial management should follow a goal-directed sepsis protocol, if indicated. Early broad-spectrum antibiotic therapy aimed at the most commonly responsible organisms should be initiated. While obtaining cultures is ideal, they should not delay therapy. There have been multiple antibiotic regimens described but most often should include an extended spectrum *B*-lactam, or combination of a third generation

cephalosporin or fluoroquinolone and metronidazole<sup>20-22</sup> Of course, local resistance patterns should be considered when initiating antibiotic therapy. Drainage technique may vary depending on surgical expertise and availability of interventional radiology. Some advocate that large abscesses such as those greater than 5cm may benefit from open surgical drainage<sup>23</sup> Percutaneous drainage by either ultrasound or CT guided is ideal for most other abscesses.<sup>24-27</sup>

### Conclusion

Hepatic abscess is mainly pyogenic or amoebic liver abscess. It mainly affects males in their late thirties and more prevalent in non vegetarians and alcoholics. Its right lobe of the liver that is mainly involved and single cavity presentation superseded multiple cavity, most of them were less than 5cm of size on presentation. Ultrasonography have been found to be highly sensitive in diagnosing liver abscess and highly effective tool is USG guided aspiration and percutaneous drainage causing early recovery with very few complications. Broad spectrum antibiotic coverage including penicillin, aminoglycoside and metronidazole shall be initiated till culture sensitivity report is available.

**Conflict of interest-** No conflict of interest

**Financial disclosure-**None-

### Reference

1. Donovan AJ, Yellin AE, Ralls PW. Hepatic abscess. *World J Surg.* 1991;15:162-169.
2. Thompson JE, Jr, Forlenza S, Verma R. Amoebic liver abscess: a therapeutic approach. *Rev Infect Dis.* 1985;7:171-179.
3. Sherlock S, Dooley J. 9th ed. Oxford: Blackwell Sci Pub; 1993. Diseases of the liver and biliary system; pp. 471-502.
4. Theron P. Surgical aspects of amoebiasis. *Br Med J.* 1947;2:123-126.
5. Giorgio A, Tarantino L, Mariniello N, et al. Pyogenic liver abscesses: 13 years of experience in percutaneous needle aspiration with US guidance. *Radiology.* 1995;195:122-124.
6. Gerzof SG, Johnson WC, Robbins AH, Nabseth DC. Intrahepatic pyogenic abscesses: treatment by percutaneous drainage. *Am J Surg.* 1985;149:487-494
7. Attar B, Levendoglu H, Cuasay NS. CT-guided percutaneous aspiration and catheter drainage of pyogenic liver abscesses. *Am J Gastroenterol.* 1986;81:550-555.
8. Bertel CK, van Heerden JA, Sheedy PF., 2nd Treatment of pyogenic hepatic abscesses. Surgical vs percutaneous drainage. *Arch Surg.* 1986;121:554-558.
9. Wang JH, Liu YC, Lee SS, et al. Primary liver abscess due to *Klebsiella pneumoniae* in Taiwan. *Clin Infect Dis.* 1998;26:1434-1438.
10. Seeto R, et al. Pyogenic liver abscess: changes in etiology, management and outcome. *Medicine* 1996; 75:99-113.
11. Yu SC, et al. Treatment of pyogenic liver abscess: prospective randomized comparison of catheter drainage and needle aspiration. *Hepatology* 2004; 39:932-8.
12. Hoffner RJ, Kilagbalian T, Esekogwu VI, Henderson SO. Common presentations of amoebic liver abscess. *Ann Emerg Med.* 1999;34:351-355.
13. Branum GD, Tyson GS, Branum MA, Meyers WC. Hepatic abscess. Changes in etiology, diagnosis, and management. *Ann Surg.* 1990;212:655-662.
14. Sepulveda B, Manzo NTG. Clinical manifestations and diagnosis of amoebiasis. In: Martinez-Palomo A, editor. *Amoebiasis: Human Parasitic Diseases.* No. 2. Amsterdam: Elsevier; 1986. pp. 169-187.
15. Hughes MA, Petri WA., Jr Amoebic liver abscess. *Infect Dis Clin North Am.* 2000;14:565-582. viii.

16. Ralls PW, et al. Sonographic findings in hepatic amoebic abscess. *Radiology* 1982; 145:123-6.
17. Benedetti BS, Desser T, Jeffrey RB. Imaging of Hepatic Infections. *Ultrasound Quarterly*.2008;24:267–278
18. Lin AC, Yeh DY, Hsu YH, et al. Diagnosis of pyogenic liver abscess by abdominal ultrasonography in the emergency department. *Emerg Med J*. 2009;26:273–275.
19. Attar B, Levendoglu H, Cuasay NS. CT-guided percutaneous aspiration and catheter drainage of pyogenic liver abscesses. *Am J Gastroenterol*. 1986;81:550–555.
20. Yu SC, et al. Treatment of pyogenic liver abscess: prospective randomized comparison of catheter drainage and needle aspiration. *Hepatology* 2004; 39:932-8.
21. Balasegaram M. Management of hepatic abscess. *Curr Prob Surg* 1981; 18:282-340.
22. Sharma MP, et al. Management of amoebic liver abscess. *Arch Med Res* 2000; 31:S4-5.
23. Thompson JE Jr, et al. amoebic liver abscess: a therapeutic approach. *Rev Infect Dis* 1985; 7:171-9.
24. Attar B, Levendoglu H, Cuasay NS. CT-guided percutaneous aspiration and catheter drainage of pyogenic liver abscesses. *Am J Gastroenterol*. 1986;81:550–555.
25. Tan YM, Chung AY, Chow PK, et al. An appraisal of surgical and percutaneous drainage for pyogenic liver abscesses larger than 5 cm. *Ann Surg*. 2005;241:485.
26. Rajak CL, Gupta S, Jain S, Chawla Y, Gulati M, Suri S. Percutaneous treatment of liver abscesses: needle aspiration versus catheter drainage. *AJR*. 1998;170:1035–1039
27. Saraswat VA, Agarwal DK, Baijal SS, et al. Percutaneous catheter drainage of amoebic liver abscess. *Clin Radiol*. 1992; 45:187–189.