



Role of 128 Slice MDCT Coronary Angiography in Patients with Ischemic Heart Disease

Authors

Dr Muthu Kumar Sakthivel¹, Dr Dinu Chandran Nair²,

Dr Karunakaran Muthukalathi³, Dr Praveen Kumar Natesan⁴

^{1,2}Radiology Resident, ³Professor & Head of the Department, ⁴Assistant Professor

Department of Radiodiagnosis & Interventional Radiology, KG Hospital & Post Graduate Medical Institute,
No.5, Govt. Arts College Road, Coimbatore, India-641018

Corresponding Author

Dr Muthu Kumar Sakthivel

No:5, Pattammal Nagar, Valatheru, Karaikal -609602

Email: drmuthukumar1985@gmail.com, Fax: 04368 263340, Cell: 8754514605

Abstract

Background: *The purpose of my study is to prospectively assess the diagnostic performance of 128-slice Multidetector computed tomography (CT) for coronary artery disease with conventional coronary angiography as reference standard*

Methods: *128 slice CT coronary angiography was performed in 53 patients prior to conventional coronary angiography. 7 patients had prior surgical intervention.*

Results: *On CT coronary angiography, out of 46 patients - 16 (normal), 10 (insignificant stenosis), 11 (Single vessel disease), 5 (Two vessel disease) & 4 (three vessel disease). Out of the total 53 lesions detected in DSA 14 (mild grade), 22 (moderate grade) & 17 (severe grade).*

Conclusion: *128 slice MDCT is currently the most accurate & non-invasive modality for the detection of coronary artery disease. However in the future, it will not replace coronary angiography as the reference tool. In patients with modest heart rate MDCT is a reliable alternative to catheter angiography.*

Keywords: *MDCT Coronary Angiography, Ischemic Heart Disease.*

INTRODUCTION

Coronary artery disease (CAD) remains the leading cause of death in western countries with increasing prevalence in developing countries. The standard reference for diagnosis of CAD is coronary catheter angiography. The greatest advantage of catheter angiography is its high spatial resolution and option of directly performing intervention, such as balloon dilatation or coronary stenting. Only one third of all coronary catheter examinations in the United

States were performed in conjunction with an interventional procedure (Percutaneous Transluminal Coronary Angioplasty – PTCA), however, whereas the rest were performed for mere diagnostic purposes. The scenario is similar in developing countries. Accordingly, a reliable, non invasive tool for imaging of the coronary arteries and for early diagnosis of CAD is highly desirable. Imaging of the heart has always been technically challenging because of the heart's continuous motion. CT imaging of the heart

moved into the diagnostic realm by the introduction of multi detector row CT (MDCT)^(2,3) and development of ECG-Synchronized scanning and reconstruction techniques⁽⁴⁾. These modalities allow for faster volume coverage and higher spatial and temporal resolution. The introduction of MDCT especially has greatly benefited cardiovascular CT imaging applications. The speed of image acquisition shortens breath hold and examination time for the patient and reduces the amount of contrast media needed for high and consistent vascular enhancement⁽⁴⁻⁸⁾. With the advent of 128-slice MDCT scanners sub millimeter resolution (0.4mm) of substantial anatomic volumes is routinely achieved.

128 slice MDCT was launched studied and researched in 2007, since then various independent studies and researchers have proved its efficacy, sensitivity, specificity and accuracy in detecting CAD.

OBJECTIVES

The purpose of my study is to prospectively assess the diagnostic performance of 128-slice Multi detector computed tomography (CT) for coronary artery disease with conventional coronary angiography as reference standard.

The following criterias are assessed:

1. Detection of occlusion and percentage stenosis of coronary arteries.
2. To study the role of calcium score in predicting coronary artery disease.
3. Evaluation of coronary stents and coronary artery bypass graft in patients with coronary artery disease.

RESULTS

Age distribution: The age distribution of the study population is as shown in table 1 and chart 1

TABLE 1

Age groups	21-30	31-40	41-50	51-60	61-70	71-80
No of patients	2	6	10	13	20	2
Percentage(%)	3.77	11.32	18.86	24.52	37.73	3.77

Thus, majority of the patients in the study population belong to 51-60 and 61-70 years age group and less in 71-80 years age group.

METHODS

CT scanner in our institution is a 128 slice Cardiac CT, SOMATOM DEFINITION AS+ FROM SIEMENS. This rapid image acquisition coupled with a very high spatial resolution (0.3mm isotropic resolution) allows us to reliably visualise the coronary arteries and the beating heart with high resolution

CT coronary angiography was performed in 53 patients prior to conventional coronary angiography. Of these, 7 patients had prior surgical intervention, 3 were post CABG and 4 were post stenting patients.

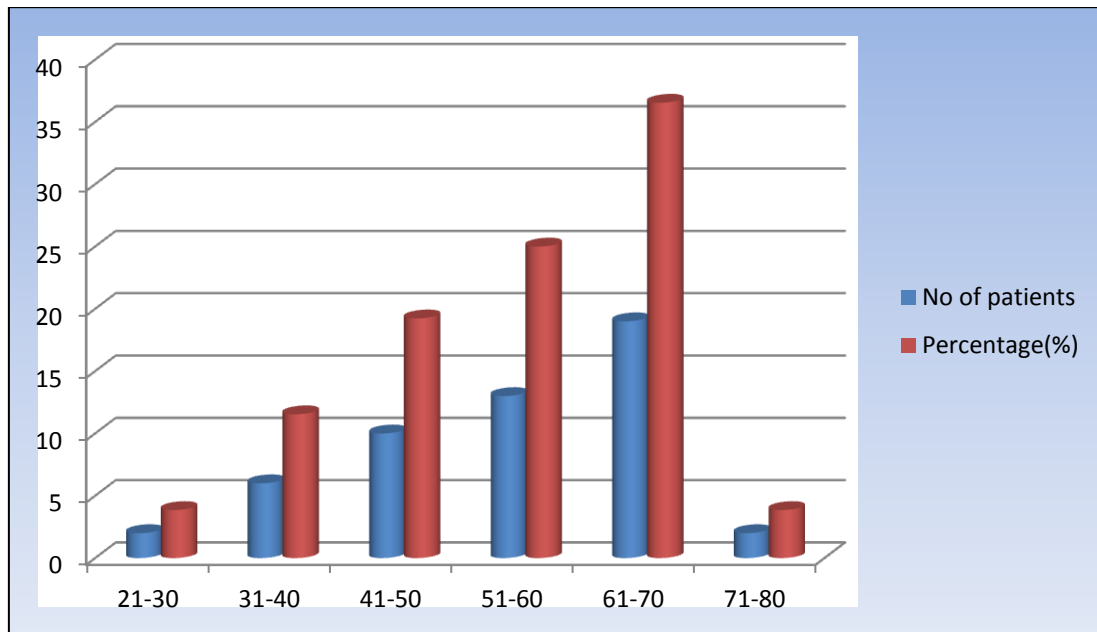
Inclusion criteria were as follows: patients suspected of coronary artery disease (CAD), patients with inconclusive stress test results, high risk like DM, HT, Type A, smoking, family history, acute chest pain without ST elevation on ECG, follow up of symptomatic patients with coronary artery bypasses and stents, exclusion of coronary artery anomalies.

Exclusion criteria for CT were as follows: previous allergic reactions to iodine contrast media, severe renal insufficiency, hemodynamic instability, atrial fibrillation, inability to follow breath-hold commands, hyperthyroidism, asthma. The study was approved by our institutional ethics committee and all participating patients gave written informed consent.

The patients were in varied age groups, ranging from 22 yrs to 71 yrs. There were 41 male and 12 female patients.

All 53 patients underwent 128 Slice MDCT Coronary Angiography, Conventional Catheter based angiography and Calcium Scoring

CHART 1- AGE DISTRIBUTION



Sex distribution

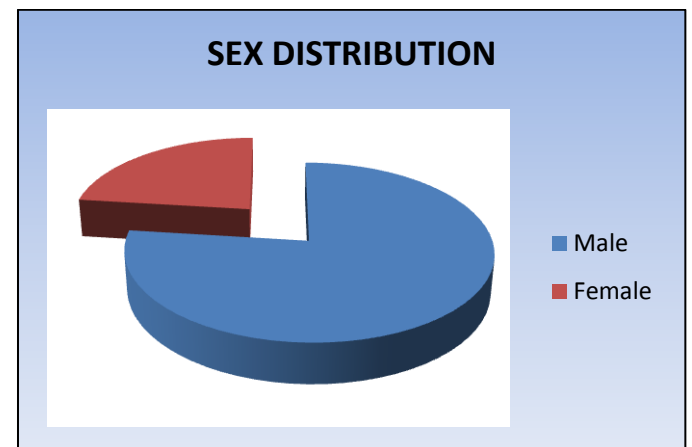
The sex distribution of the study population is as shown in table 2 and chart 2

TABLE 2

Sex	No. of patients	Percentage (%)
Male	41	77.35
Female	12	22.65

Thus, 77.35 % of patients in study population were male, showing the male predominance of coronary artery disease.

CHART 2



Distribution of patients according to involvement of number of vessels excluding patients with stents and CABG. Significant stenosis was defined as atleast one lesion causing >50 % stenosis of given coronary artery.

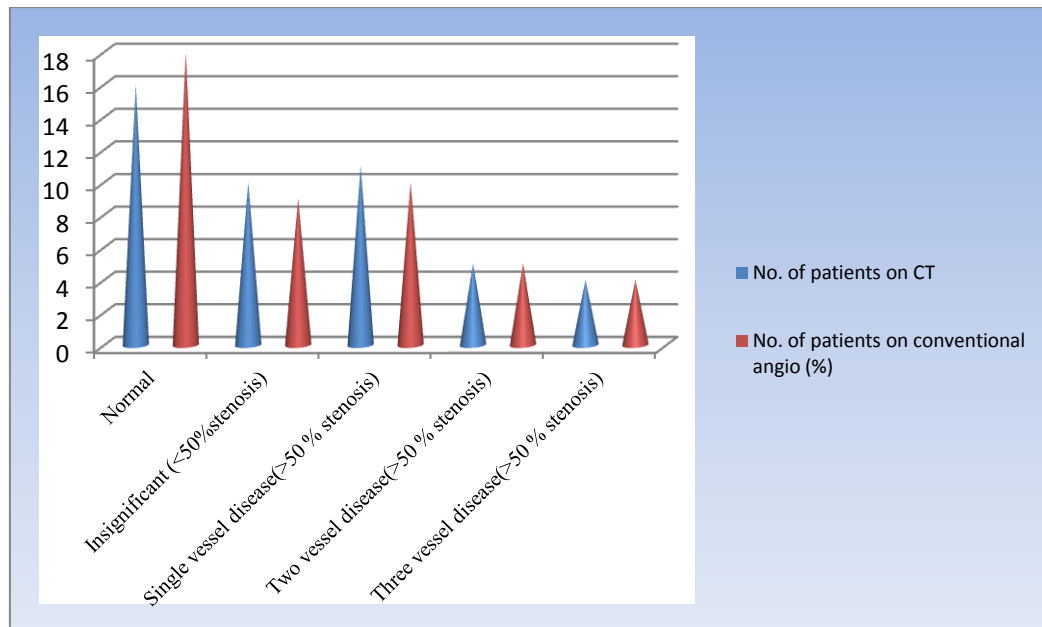
TABLE 3

Findings	Normal	Insignificant (<50%stenosis)	Single vessel disease(>50 % stenosis)	Two vessel disease(>50 % stenosis)	Three vessel disease(>50 % stenosis)
No. of patients on CT	16	10	11	5	4
No. of patients on DSA (%)	18	9	10	5	4

Chi-Square=0.218, p=0.995 (not significant) i.e. there is no significant difference between CT and DSA in diagnosing the number of vessels involved.

Most of the patients with significant stenosis belonged to the category of single vessel disease.

CHART 3



Total number of lesions detected by CT coronary angiography was 58 and by DSA were 53, which were divided into 3 grades of severity: mild, moderate and severe approximately correlating

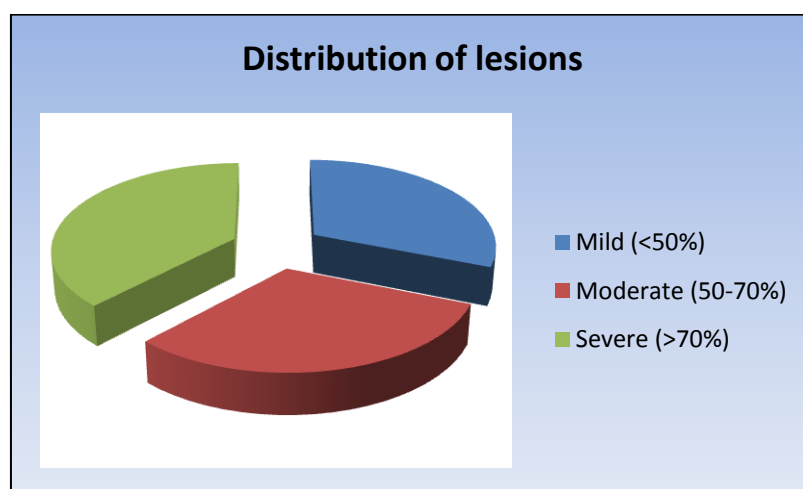
with < 50%, between 50-70% and > 70% luminal diameter narrowing. The distribution is as shown in the table 4 and chart 4

TABLE 4

Grade of severity	Mild (<50%)	Moderate (50-70%)	Severe (>70%)
No. of lesions on CTCA	18	18	22
No. of lesions on DSA	14	22	17

Chi-Square=1.318, p=0.517 (not significant) i.e. both CT and DSA show similar distribution of severity amongst cases.

CHART 4



Total number of significant lesions i.e. lesions causing >50% stenosis of coronary artery segment

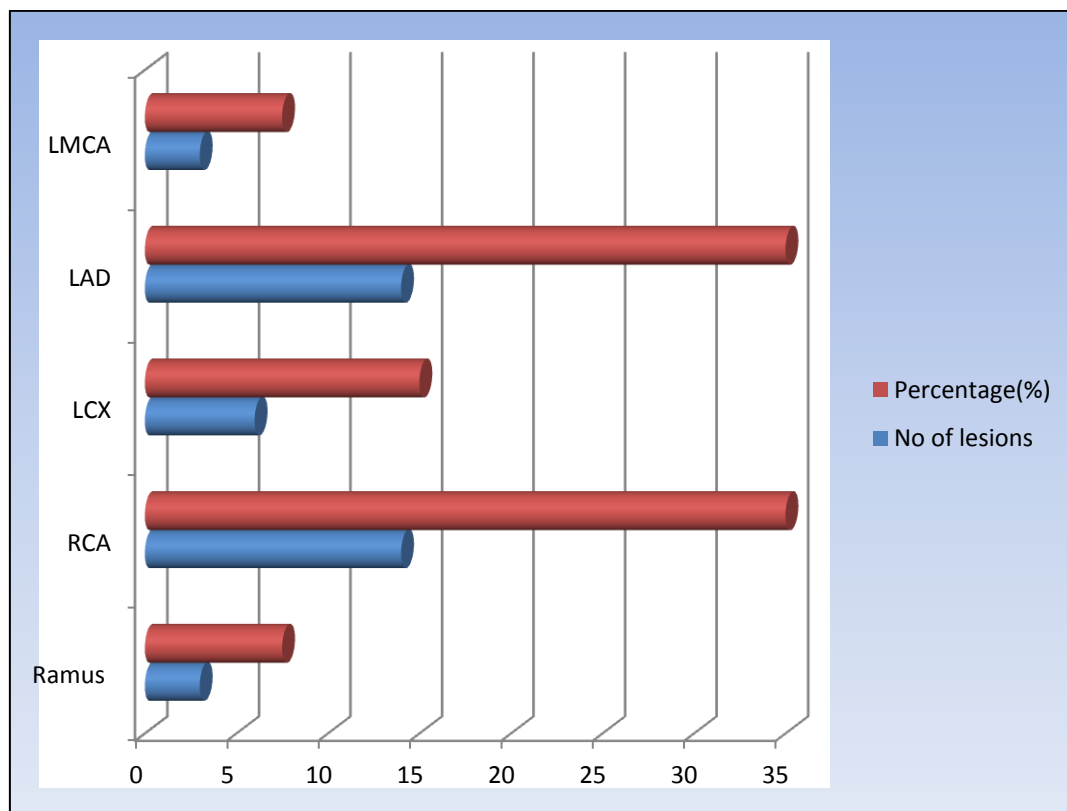
were 40 with their distribution as shown in following table 5 and chart5-

TABLE 5

Vessel involved	LMCA	LAD	LCX	RCA	Ramus
No of lesions	3	14	6	14	3
Percentage (%)	7.5	35	15	35	7.5

Thus, most commonly involved vessels were proximal, mid or distal segments of LAD and RCA.

CHART 5



SENSITIVITY AND SPECIFICITY

Table denotes the sensitivity, specificity, positive and negative predictive value of CT coronary angiography for detecting significant stenosis i.e.

>50% stenosis on per patient basis with conventional invasive coronary angiography as reference standard. The patients with post CABG and PTCA with stent are not included.

TABLE 6

Significant stenosis on DSA \ CTCA	PRESENT	ABSENT	TOTAL
	POSITIVE	21	2
NEGATIVE	1	22	23
TOTAL	22	24	46

Sensitivity = $21 / 22 \times 100 = 95.45 \%$

Specificity = $22 / 24 \times 100 = 91.66 \%$

Positive predictive value = $21 / 23 \times 100 = 91.30 \%$

Negative predictive value = $22 / 23 \times 100 = 95.65 \%$

CALCIUM SCORE

Calcium scores (Agatston) for each patient were calculated and graded according to scoring guidelines into following classes- 0, 1-10, 11-100, 101-400 and 401 or higher.

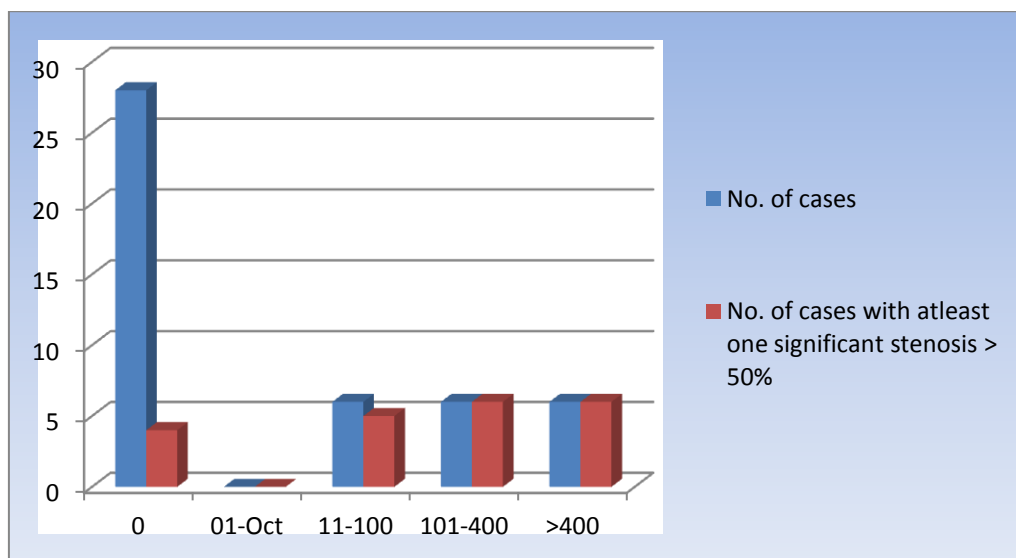
Among each category, patients with atleast one significant stenosis were calculated. The results are as shown in table 7 and chart 6-

TABLE 7

Ca score	0	1-10	11-100	101-400	>400
No. of cases	28	0	6	6	6
No. of cases with atleast one significant stenosis > 50%	4	0	5	6	6

CHART 6

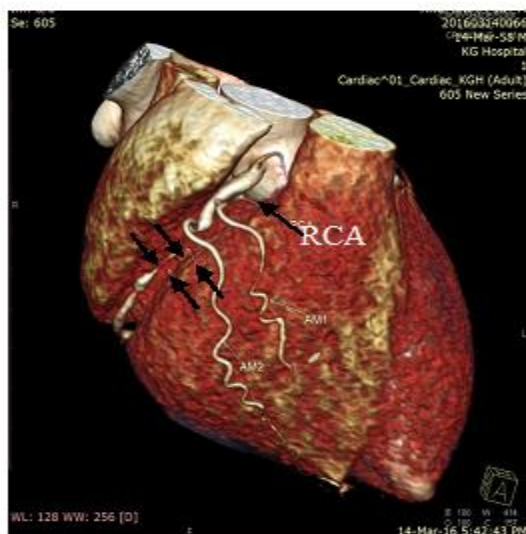
Distribution of calcium score and no. of cases with atleast one stenosis > 50 %.



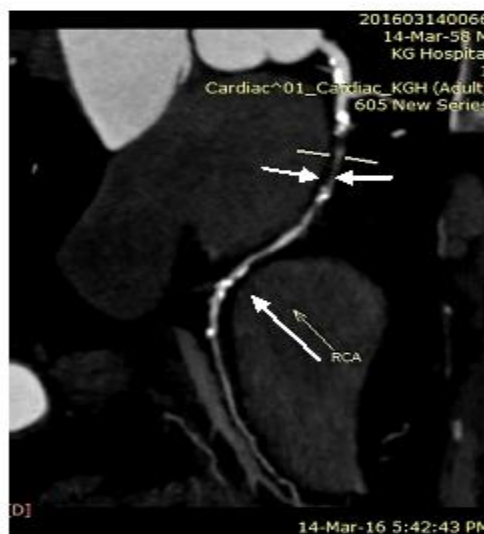ILLUSTRATIVE CASES

CASE 1

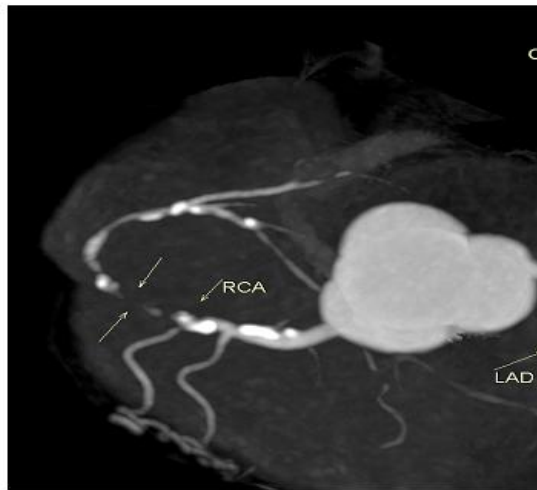
- 68 year old male with history of recurrent chest pain for 15 days.



(A)



(B)

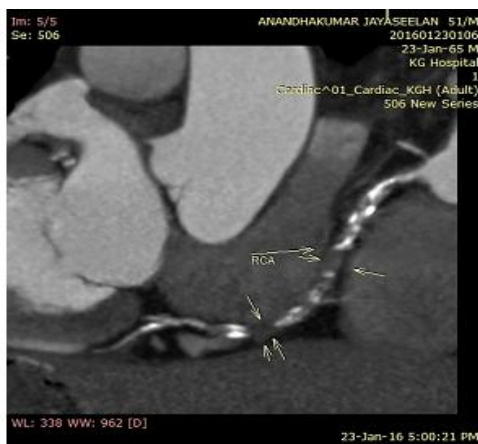

(C)

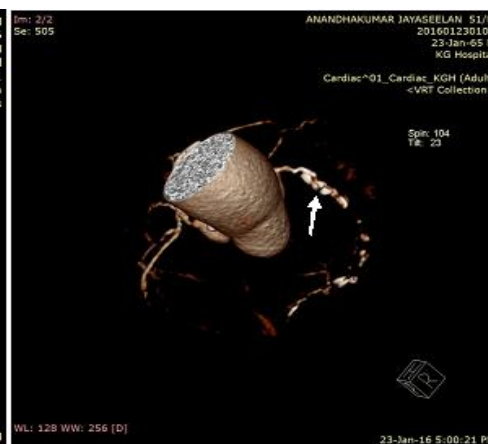- Coronary arterial circulation is right dominant.
- 80-90% stenosis (A, B, C) in mid segment of right coronary artery.

CASE 2

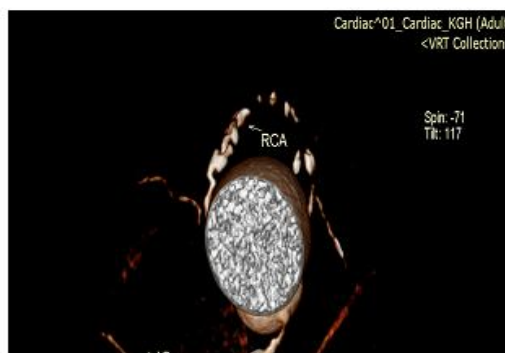
69 year old male, status post PTCA + LAD stenting presented with intermittent chest pain for past 2 months.



(A)



(B)



(C)

- Coronary Arterial circulation is Right dominant
- Severe 80-90% steno-occlusive disease in all segments of Right coronary artery with minimal sparing of ostial RCA (A, B, C).

DISCUSSION

Imaging of the heart and great vessels has previously been done with plain film, cardiac catheterization, nuclear medicine and echocardiography as the primary imaging modalities. The recent newer advances in the Computed Tomography (CT) and Magnetic Resonance Imaging (MRI) technologies, however, have dramatically changed our approach to imaging cardiac disease.

CT images, which initially took over 4 minutes to generate, can now be obtained in 50-100 ms with electron beam imaging and in 165-330 ms with helical imaging. Importantly, these advances in temporal resolution are rapid enough to essentially stop cardiac motion and thus visualization of extremely small structures such as calcium deposits within the walls of the coronary arteries is now possible.

The recent introduction of a new scanner generation with high spatial (0.3 mm^3) and high temporal (150ms) resolution generating 128 slices per rotation and covering entire volume of heart in approximately 4 seconds promises a significant improvement in image quality that may allow a more precise evaluation of coronary artery stenosis. Initial reports on this system are very promising, reporting a sensitivity and specificity for the detection of significant stenosis of 94% and 97% respectively. On comparing 128 slice MDCT with intravascular sonography, a good correlation between these techniques in assessing the degree of a given coronary artery stenosis could be shown.

Thus the aim of the present study was to evaluate the role of 128 slice MDCT in coronary artery disease in patients with or without a history of coronary artery disease.

53 patients were included in this study with or without known coronary artery disease.

There were 41 male (77.35 %) patients and 12 female (32.65 %) patients, showing the male predominance of coronary artery disease.

The patients were from a varied age group, ranging from 22 yrs to 71 yrs, with maximum

patients in 41-50 and 51-60 yrs age group and less in 71-80 yrs age group.

Of the 53 patients, 7 patients had previously undergone surgical intervention in form of coronary artery bypass grafting in 3 patients and percutaneous transluminal coronary angioplasty with stent implantation in 4 patients.

The procedure of coronary angiography was well tolerated by all the 53 patients. There were no episodes of contrast extravasation or adverse contrast reactions. Good intra-arterial contrast density was achieved in all the subjects, resulting in diagnostic images.

In 6 patients (11.32 %), there were artifacts. 2 patients had high calcium causing partial averaging rendering a small segment of the artery non-assessable. 2 patients had more than 1 stair step artifact or minimal blurring of the vessel edge but the vessel was assessable. 1 patient had one stair step artifact

All the patients with heart rate more than 65 bpm received prescan betablockers (Betaloc-Metoprolol). A study by K Nieman et al on 4 MDCT revealed reliable coronary angiography in patients with low heart rate.

In our study, with the use of β -blockers we were able to attain heart rate below 65 bpm except for 2 cases (sinus tachycardia). But with the help of image reconstruction in different phases the artifacts produced due to high heart rate could be reduced to achieve diagnostic image quality.

MDCT CORONARY ANGIOGRAPHY

The diagnostic accuracy of MDCT for the non-invasive detection of coronary artery disease has improved remarkably in recent years. These findings combined with the high reproducible image quality of the newer generation scanners, make coronary MDCT a promising technique for successful implementation in daily cardiology routines.

Therefore, the aim of this study was to determine the diagnostic accuracy of 128slice MDCT for the detection of coronary artery disease.

Distribution of patients was done according to involvement of number of vessels excluding patients with stents and CABG. Significant stenosis was defined as atleast one lesion causing >50 % stenosis of given coronary artery. On CT coronary angiography out of the 46 patients, 16 (34.78%) were normal, 10 (21.74%) had insignificant stenosis, 11 (23.91%) patients had single vessel disease, 5 (11%) patients had two vessel disease and 4 (8%) had three vessel disease. On DSA, 18 (39.13%) patients were normal, 9 (19.56%) had insignificant stenosis, 10 (21.74%) had single vessel disease, 5 (11%) had two vessel disease and 4 (8%) patients had three vessel disease. This distribution shows that there is no significant difference between CT and DSA in diagnosing the number of vessels involved. The most common category among patients with significant stenosis was single vessel disease.

The stenotic lesions were divided into 3 grades of severity: mild, moderate and severe approximately correlating with below 50%, between 50 to 70% and above 70% luminal diameter narrowing.

Total of 58 lesions were identified. Of these, 22 (37.93 %) lesions were found in proximal, mid and distal segments of the left anterior descending artery. 10 (17.24 %) lesions were detected in left circumflex artery. 16 (27.58%) lesions were detected in proximal, mid and distal segments of the right coronary artery. 7 (12 %) of the lesions were detected in pre-bifurcation or at bifurcation of left main coronary artery. 3 (5.17%) lesions

were detected in Ramus intermedius.

Of the 58 lesions, there were 18 lesions of mild grade, 18 lesions of moderate grade and 22 lesions of severe grade.

Total of 53 lesions were detected on DSA out of which 14 lesions were of mild grade, 22 lesions of moderate grade and 17 lesions of severe grade.

Chi square test was applied and p value (0.517) was calculated for this observation which is not significant i.e. both CT and DSA show similar distribution of severity amongst cases.

Total of 40 lesions were detected with stenosis greater 50% which were termed as significant lesions. Of these 14 (35%) lesions were seen in left anterior descending artery, 6 (15%) lesions in left circumflex artery, 14 (35%) lesions in right coronary artery, 3 (7.5%) lesions in left main coronary artery and 3 (7.5%) lesions in ramus intermedius.

The threshold stenosis of greater than 50% was used. Patients with stents or post CABG were excluded from this particular analysis. The sensitivity, specificity, positive and negative predictive value of MDCT was calculated with conventional coronary angiography as reference standard which was 95.45 %, 91.66 %, 91.30 % and 95.65% respectively.

Rajneesh Madhok and Abhinav Aggarwal et al compared the diagnostic accuracy of 128-Slice Dual Source CT Coronary Angiography with Invasive Coronary Angiography in the diagnosis of coronary artery disease.

Recent reports utilizing Multi detector technology (64 & 128 slice CT) have sensitivities and specificities as shown below:

TABLE 7:

Author	No. patients	Sensitivity (%)	Specificity (%)	NPVa (%)
Mollet (61)	52	99	95	99
Leber (62)	59	73	97	-
Leschka (63)	67	94	97	99
Raff (64)	70	95	86	98
Fine (65)	66	95	96	92
Ropers (66)	82	93	97	100
Garcia (67)	187	89	65	99
Rajneesh(113)	40	95.26	95.12	98.08
Present study	46*	95.45	91.66	95.65

* excluding patients with CABG and stents.

Thus, from this study it could be concluded that in clinical routine, CT coronary angiography can primarily be used for risk stratification on a per patient basis. Based on these findings a decision about whether the patient should or should not go for further diagnosis and potentially invasive therapy is inferred.

CORONARY CALCIUM STUDY

Total calcium scores of all patients were calculated with dedicated software and expressed as Agatston scores. The Agatston score is commonly used scoring method that calculates the total amount of calcium on the basis of the number, area and peak Hounsfield units of the detected calcified lesions.

The calculated Agatston score was classified into:

- 0
- 1-10
- 11-100
- 101-400
- 401 or higher

Patients with calcium score above 1000 and post surgical intervention patients (n=7) were not included in this study.

Of the 46 patients studied for the calcium score, 28 patients (60%) showed no evidence of calcium. Of these, 12 patients (26 %) had evidence of coronary artery stenosis on MDCT coronary angiography. Out of these 12 patients, 4 (33.33%) patients had significant > 50 % luminal narrowing and 8 (67 %) had insignificant stenosis i.e. < 50 % luminal narrowing due to non-calcified plaque. 16 (57.14%) patients out of 28 patients were normal. There was no patient in the study population with calcium score between 1 and 10.

There were 6 patients (13.04%) with calcium score between 11-100. Of these, 5 patients (83.33%) had evidence of significant stenosis when threshold stenosis of greater than 50% was used.

6 patients (13.04 %) had calcium score between 101-400, of which all 6 patients (100%) had evidence of atleast one stenosis of greater than 50

% on MDCT coronary angiography.

There were 6 patients (13.04%) with a calcium score of 401 or greater and all 6 (100%) had evidence of atleast one significant coronary artery stenosis (>50% stenosis).

Patients with calcium score above 1000 were not included in this study as accuracy of detecting coronary artery stenosis decreases drastically with higher calcium score.

POST SURGICAL INTERVENTION

Post coronary artery bypass grafting (CABG):

Like any other vascular diagnostic field, coronary bypass grafting was subjected to CT evaluation early after its introduction in clinical practice. In comparison with conventional coronary angiography (CAG), conventional CT scanning with contrast enhancement proved to have potential to image saphenous venous grafts (96, 97), but preliminary results on this respect were confined to simple patency assessment (occluded vs. not occluded)

In our study, there were 3 post coronary artery bypass grafting patients. Of them, 2 patients were symptomatic and 1 patient was asymptomatic, for follow up. Overall 8 grafts were well visualized. Of these, there were 3 arterial and 5 saphenous venous grafts.

All the arterial grafts were patent except in 1 patient in which one patent arterial graft was seen well upto the anastomotic site but no distal flow suggesting anastomotic block. These findings were confirmed on the conventional invasive coronary angiography.

Of the 5 saphenous venous graft, only 4 grafts were patent throughout and only 1 saphenous venous graft showed complete occlusion just after its origin. Conventional invasive coronary angiography showed similar results.

Post percutaneous transluminal coronary angioplasty (PTCA) with stent placement :

High pressure stent implantation is an established technique to maintain luminal integrity following interventional revascularisation in native coronary

arteries and bypass grafts. There were 4 patients of post-stenting status with total of 4 stents. Of these, 3 stents were patent with good flow proximal and distal to the stent. All the three stents were patent on invasive coronary angiography.

One patient had complete occlusion (100% stenosis) of the vessel just proximal to stent, with poor opacification of the stent lumen and distal vessel suggestive of collateral flow which was confirmed on conventional angiography.

DOMINANCE

Depending on which side of the coronary system supplies the posterior descending artery (PDA) and postero-lateral branch of left ventricle (PLV); the dependence is decided.

In our study, right dominance was noted in 48 patients (90.57 %), 4 patients (7.54%) had left dominant system. 1 patient (1.88 %) had co-dominance i.e. supplied by both left and right side.

Ramus Intermedius

In some heart, artery running towards the mid portion of the lateral wall of the left ventricle arises from the angle between the left anterior descending and circumflex artery. This creates an appearance of trifurcation of main trunk. In our study population, 6 (11.32 %) patients had Ramus Intermedius.

CONCLUSION

Multidetector computed tomography provides high accuracy for noninvasive detection of suspected obstructive coronary artery disease. This promising technology has potential to complement diagnostic invasive coronary angiography in routine clinical care.

128 slice MDCT is currently the most accurate, non-invasive angiographic modality for the detection of coronary artery disease. Despite the use of radiation and contrast media, MDCT coronary angiography is a relatively safe and simple procedure. All the data can be acquired within 4-5 sec, providing predictable image quality, depending on the heart rate and the

coronary calcium status of the patient. The contrast to noise ratio is high and 3D resolution of the current generation scanners is 0.3 mm^3 . This spatial resolution allows imaging of smallest branches, often neglected in the MR, EBCT and 4 and 16 rows MDCT studies.

However, in the foreseeable future, MDCT coronary angiography will not replace coronary angiography as the reference coronary imaging tool. Conventional angiography is performed without severe complications in the vast majority of patients with consistently high quality data with an excellent spatial resolution that allows quantitative assessment of the severity of the stenotic lesion. Conventional angiography can also be complemented by functional flow assessment and can immediately be followed by a percutaneous interventional procedure to treat the obstructive problem.

In patients with a modest heart rate, MDCT could, however provide a useful and reliable alternative to diagnostic catheter-based angiography for the initial detection and localization of coronary stenosis. Additionally, because of its non-invasive nature, MDCT coronary angiography can be introduced into the diagnostic work up of patients with anginal complaints at an earlier stage, when catheters based angiography is not yet indicated. Potential applications are the exclusion of an acute coronary obstruction in patients with atypical chest pain at the emergency ward; coronary artery stenosis in patients who need major (non cardiac) surgery, or obstructive disease in patients with inconclusive stress test. Multidetector CT (MDCT) can be used for the detection and quantification of coronary calcium which is a good indicator of coronary atherosclerosis and total plaque burden. MDCT may also be valuable when repeated angiographic follow-up is indicated or after percutaneous coronary intervention or coronary artery bypass surgery.

Another fundamental application of MDCT is represented in re-do CABG surgery where

extremely meticulous planning of surgical approach is required.

Source of Support or Grants: Not Applicable

REFERENCES

1. Ropers D, Vizheimer S, Wenker E, et al. Investigation of aorta coronary bypass grafts by multislice CT with ECG-gated image reconstruction. *Am J Cardiol* 2001; 88: 792-795.
2. Campcau L, Enjalberk M, Lseperance J, et al. The relation of risk factors to the development of atherosclerosis in saphenous vein bypass grafts and the progression of disease in the native circulation. *N Engl J Med* 1984; 311: 1329-32.
3. Fitzgibbon GM, Kafka HP, Leach AJ, et al. Coronary bypass graft fate and patient outcome. *J Am Coll Cardiol* 1996; 28: 616-26.
4. Bourassa MG. Fate of venous grafts: the past, the present and the future. *JACC* 1991; 5: 1081-83.
5. Helene Vernket-Kovacsik, Poscal Battistella, Roland Demaria, et al. Early post-operative assessment of CABG patency and anatomy. *AJR* 2006; 186: s395-s400.
6. Yamaguchi A, Adachi H, Inot, et al. 3D CT angiography as pre-operative evaluation of a patent internal thoracic artery graft. *J Thorac Cardiovas Surg* 2000; 120: 811-812.
7. Serruys PW, Emanuelsson H, van der Giessen W, et al. Heparin-coated Palmaz-Schatz stents in human coronary arteries: early outcome of the Benestent-II pilot study. *Circulation* 1996; 93: 412-422.
8. Erbel R, haude M, Hopp HW, et al. Coronary artery stenting compared with balloon angioplasty for restenosis after initial balloon angioplasty: Restenosis Stent (REST) Study Group. *N Engl J Med* 1998; 339: 1672-78.
9. Antonucci D, Valenti R, Santroo GM, et al. Restenosis after coronary stenting in current clinical practice. *Am Heart J* 1998; 135: 510-518.
10. DiMario C, Reimers B, Almagor Y, et al. Procedural and follow up results with a new balloon expandable stent in unselected lesions. *Heart* 1998; 79: 234-41.
11. De Gregorio J, Kobayashi Y, Albeiro R, et al. Coronary artery stenting in the elderly: short term outcome and longterm angiographic and clinical follow-up. *JACC* 1998; 32: 577-83.
12. Bittl JA. Advances in coronary angioplasty. *N Engl J Med* 1996; 335: 1290-1302.
13. Konstantin Nikolaou, Andreas Knez, et al. Accuracy of 64-MDCT in the Diagnosis of Ischemic Heart Disease *AJR* 2006; 187:111-117
14. Rajneesh Madhok and Abhinav Aggarwal, et al. Comparison of 128-Slice Dual Source CT Coronary Angiography with Invasive Coronary Angiography. *J Clin Diagn Res.* 2014 Jun; 8(6): RC08-RC11.
15. Sherif W Ayad, Eman M El Sharkawy, Salah M ElTahan, Mohamed A Sobhy, and Reem H Laymouna et al. The Role of 64/128-Slice Multidetector Computed Tomography to Assess the Progression of Coronary Atherosclerosis. *Clin Med Insights Cardiol.* 2015; 9: 47-52.