



Acute Flaccid Quadriplegia: A Rare Case of Adult Onset Bartter's Syndrome

Authors

Dr Ankur Banik, Dr Sourish Chatterjee, Dr Uttam Biswas

Dept of General Medicine, Burdwan Medical College and Hospital, Burdwan – 713104, West Bengal India

Corresponding Author

Dr Ankur Banik

Post Graduate Trainee, Department of General Medicine, Burdwan Medical College & Hospital

Address: Junior Resident Hostel, Room number 36, Burdwan Medical College & Hospital. Burdwan – 713104, West Bengal India

Email: banik.ankur@gmail.com, Phone number: 9433712611

Abstract

Bartter's syndrome is a rare autosomal recessive disorder which generally presents in paediatric age group. It is characterised by hypokalemia, hypocalcemia, hypercalciuria, metabolic alkalosis, hyper-reninemic hyperaldosteronism and a normal blood pressure. We report a case of adult onset Bartter's syndrome, in a 41 year old man who presented with acute onset quadriplegia along with weakness of neck muscles. We report this case because adult onset Bartter's syndrome is very rare and with the best of our knowledge, so far, very few case reports are available from India in which the presentation was with quadriplegia and neck weakness.

Keywords: *Bartter's syndrome, hypokalemia, acute flaccid paralysis.*

Introduction

Bartter's syndrome originally described by Bartter and his colleagues in 1962 represents a set of closely related autosomal recessive renal tubular disorders characterised by hypokalemia, hyponatremia, metabolic alkalosis, hyperaldosteronism with a normal blood pressure¹. The underlying renal abnormality results in excessive urinary loss of sodium, potassium and chloride.

Bartter's syndrome has traditionally been classified into 2 main clinical types

1. Neonatal (or Antenatal)
2. Classic^[1].

Most cases present in neonatal period or at least in childhood. Adult onset classic Bartter syndrome is rare. Very few cases of adult onset Bartter syndrome have been reported in India.

Recently we found a case of adult onset Bartter syndrome presented with hypokalemic flaccid paralysis poorly responding to potassium supplementation who showed hyponatremia, hypochloremia, metabolic alkalosis, hyperreninemia, hyper-aldosteronism with normal blood pressure.

Case Description

A 41 year old man presented to us with sudden onset weakness of all four limbs and also the neck for the last two days. The weakness was bilaterally symmetrical and neither progressive nor improving. It affected both the proximal and distal groups of muscles and it was severe enough for the patient to be totally bed ridden. There was no diurnal variation or any similar episode in the past. There was no history of any fever, vomiting, diarrhoea or any drug abuse prior to the onset of the weakness.

On examination, patient was conscious with a GCS of 15/15. His BP was 92/64 mm Hg , pulse-76/min, urine output was 3.2 L/day. Neurological examination revealed normal higher functions and cranial nerves. Motor system examination showed hypotonia of all 4 limbs and a power of 0/5 in both lower limb and 2/5 in both upper limb. DTR's were diminished in both upper limb and absent in both lower limb. Plantar reflex was bilaterally unresponsive. There was no sensory or autonomic involvement. Initially a differential diagnosis of Guillain Barre syndrome and Hypokalemic Periodic Paralysis was made.

Initial blood investigations showed Na+ 126.5 meq/L and K+ 1.78 meq/L, urea-35 mg/dl, creatinine-1.2 mg/dl, random blood glucose-120mg/dl. Patient was started with RL infusion, intravenous and oral potassium supplements. Even after such therapy neither the patient's weakness nor the blood reports improved.

Table 1 : Preliminary Investigations

	Sodium (Na+) meq/L (Normal 136-146 meq/L)	Potassium (K+) meq/L (Normal 3.5-5.0 meq/L)
Day 1	126.5	1.78
Day 2	129.2	1.84
Day 3	124.7	1.9

This prompted us to search in detail as to the etiology of hypokalemia and hyponatremia. Further investigations were carried out and they revealed the following-

Table 2 : Other Investigations

TSH	1.03 mIU/L (0.34-4.25 mIU/L)
Serum Magnesium (Mg2+)	1.3 mg/dL (1.5-2.3 mg/dL)
Serum Calcium (Ca2+)	7.9 mg/dL (8.7-10.2 mg/dL)
Serum Osmolarity	279 mOsmol/Kg (275-295 mOsmol/Kg)
Serum Chloride	93 meq/L (102-109 meq/L)
Urine Osmolarity	323 mOsm/Kg (100-800 mOsm/Kg)
Urine Potassium	211 mmol/d (25-100 mmol/d)
Urine Calcium	12.3 mmol/d (<7.5 mmol/d)
Urine Chloride	274 mmol/d (140-250 mmol/d)
Urine Sodium	289.3 mmol/d (100-260 mmol/d)
Trans Tubular Potassium Gradient (TTKG)	>4
pH	7.48 (7.35-7.45)
PO2	92mm Hg (67-104 mm Hg)
PCO2	41 mm Hg (35-45 mm Hg)
HCO3-	33 meq/L (22-30 meq/L)
Urine Calcium Creatinine ratio	0.45
Plasma renin	51 micro Iu/ml (21-41 micro IU/ml)
Serum aldosterone	47.3 ng/dL (4-31 ng/dL)
USG (whole abdomen)	WNL
EMG NCV study of all 4 limbs	WNL

ECG showed presence of U waves.

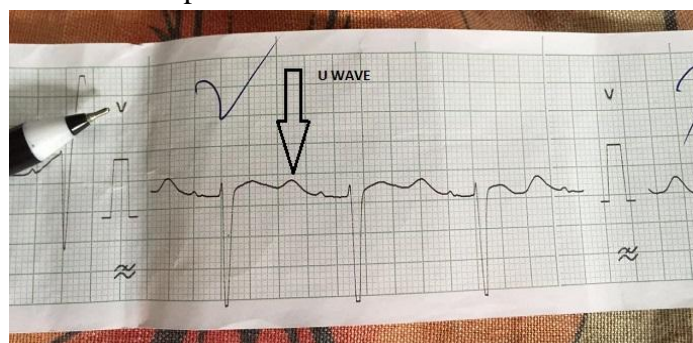


Figure 1: ECG showing U wave

On the basis of these reports the patient was treated aggressively with potassium sodium calcium and magnesium supplements. Spironolactone was added on Day 4. Patient's weakness and blood reports improved by day 6.

On the basis of the reports and the response to the treatment provided the patient was diagnosed to be a case of adult onset Bartter's syndrome. Patient was discharged with the advice of liberal salt intake, K+ and Mg2+ supplements and spironolactone. The patient continues to be followed up on OPD basis and he is doing fine with the above mentioned therapy.

Discussion

Bartter syndrome is a rare autosomal recessive disorder resulting from mutations affecting any of the five ion transport proteins in thick ascending loop of Henle^[2], giving a clinical picture of salt wasting and hypokalemic metabolic alkalosis. Metabolic abnormalities include hyponatremia, hypokalemia, hypochloremic metabolic alkalosis, hypercalciuria, mild hypomagnesemia, increased urinary prostaglandin excretion and increased plasma renin and aldosterone levels.

There is loss of the lumen-positive electrical transport potential that normally drives the paracellular reabsorption of sodium, calcium, and magnesium causing NaCl wasting, hypercalciuria, and mild hypomagnesemia in thick ascending loop of Henle (TAL). The clinical syndrome mimics the effects of chronic ingestion of a loop diuretic^[2].

Gittelman syndrome is another similar condition that mainly affects the distal convoluted tubule (DCT) and presents at a later age. The common age of presentation of Gittleman syndrome fits more closely to our case but the other characteristics which suggest a diagnosis of Gittleman syndrome are hypocalciuria, severe hypomagnesemia and predominant muscular signs with no signs of volume depletion or polyuria or polydipsia.

In both Barter's and Gittelman's syndrome Hypovolemia from impaired sodium and chloride reabsorption in either the TAL or the DCT activates the renin-angiotensin-aldosterone system (RAAS). Increased delivery of electrolytes to the distal nephron leads to biologic adaptations in the DCT and collecting duct (CD) and result in hypokalemic metabolic alkalosis^[2]. Additionally in Barter's syndrome RAAS activation causes increased level of cyclo-oxygenase 2 (COX-2) and marked overproduction of Prostaglandin E2, this exacerbates the polyuria and electrolytes abnormalities^[2].

In Our case, this 41 year old patient presented with acute flaccid quadriplegia, there was no history of any diuretics or drug abuse, diarrhoea, tuberculosis. He was polyuric and hypotensive.

Investigation showed hypokalemia, hyponatremia, hypocalcemia, hypochloremia, metabolic alkalosis. There was also elevated TTKG and Ca²⁺:Cr ratio, hypercalciuria with low normal sr. Mg²⁺ and increase level of renin and aldosterone, most likely suggests a diagnosis of Bartter's like Syndrome.

Adult onset Bartter syndrome is very rare. They are seen in cases of diuretic abuse^[2] and an association with PTB^[3], chronic sialoadenitis^[4], exposure to gentamycin^[5] and acquired idiopathic^[6] case have been reported. None of these associations were relevant to our case. so we report this case as an idiopathic Bartter's like Syndrome.

Treatment^[6] includes lifelong therapy with potassium and magnesium supplements and liberal salt intake. High doses of spironolactone or amiloride can be used. Nonsteroidal anti-inflammatory drugs (NSAIDs) reduce the polyuria and salt wasting. Indomethacin is widely used. Angiotensin I converting enzyme inhibitors have been used successfully in conjunction with potassium supplements

Conclusion

Patients with hypokalemic paralysis should be evaluated for the etiology of hypokalemia. Although adult onset Bartter syndrome is a rare clinical entity, it should be considered in patients presenting with hypokalemic paralysis with metabolic alkalosis with other corroborative investigatory findings. This is especially important because once the cause has been ascertained the patient may require lifelong therapy and may actually lead a normal life with the therapy provided.

References

1. Bartter F, Pronove P, Gill J, Jr, MacCardle R. Hyperplasia of the juxtaglomerular complex with hyperaldosteronism and hypokalemic alkalosis. A new Syndrome. Am J Med. 1962;33:811-28.

2. Longo DL, Fauci AS, Kasper DL, Hauser SL, Jameson JL, Loscalzo J. 18th edition, Vol 2. USA: The McGraw Hill Companies. Harrison's Principles of Internal Medicine 2012; 2360-2361.
3. Marilena Stoian, DehaChitac, Ecaterina Bontas, Ana Maria Dumitrescu, Victor Stocia. Bartter syndrome with pulmonary Tuberculosis a shortly outlook. Med J Clin Med 2007; 2:332-336.
4. Casatta L, Ferraccioli GF, Bartoli E. Hypokalemic alkalosis, acquired Gitelmans and Bartter syndrome in chronic sialoadenitis. Bri J Rheumatol 1997; 36:1125-1128.
5. Workeneh B, Sangsiraprabha W, Addison D, Longfield E. A novel case of persistent barters-like syndrome associated with gentamycin exposure. Saudi J Kidney Dis Transpl 2013; 24:144-146.
6. Gadwalkar SR, Murthy PR, Raghavendra, Nandini K, Deepa DV. Acquired Bartter-Like Phenotype.JAPI 2015;63:78.