



## Atypical Presentation of Severe Laryngomalacia Managed with Aryepiglottoplasty and A Novel Suture Technique

Authors

**Dr N.N. Mathur<sup>1</sup>, Rajeev Kumar Verma<sup>2</sup>, Shweta Jaitly<sup>3</sup>, Ashwani Kumar<sup>4</sup>**

<sup>1</sup>Principal Director Professor, Department of Otorhinolaryngology, VMMC and Safdarjung Hospital, New Delhi- 110029 India

Email: [drnmathur@gmail.com](mailto:drnmathur@gmail.com)

<sup>2</sup>Senior Resident, Dept of Otorhinolaryngology, VMMC and Safdarjung Hospital New Delhi- 110029 India

<sup>3</sup>Junior Resident, Dept of Otorhinolaryngology, VMMC and Safdarjung Hospital, New Delhi- 110029 India

Email: [jaitly\\_shweta@yahoo.com](mailto:jaitly_shweta@yahoo.com)

<sup>4</sup>Senior Resident, Dept of Otorhinolaryngology, VMMC and Safdarjung Hospital, New Delhi- 110029 India

Email: [drashwani.kumar007@gmail.com](mailto:drashwani.kumar007@gmail.com)

Corresponding Author

**Dr Rajeev Kumar Verma**

S/O Sh Basanti Lal Kumawat, Wd No 1, Krashi Upaz Mandi Road, Shri Madhopur Distt. Siker, Rajasthan (PIN- 332715) India

Email: [drrajeevkumar85@gmail.com](mailto:drrajeevkumar85@gmail.com), Contact no 09990455550

### Abstract

A 12 year old boy intubated for severe respiratory distress failed six extubation trials and was found to have laryngomalacia on fiberoptic laryngoscopic examination. He underwent aryepiglottoplasty and suture of epiglottis to the base of the tongue with a lumber puncture needle and the technique previously described for the lateralization of vocal cord leading to successful extubation on fourth post-operative day. The patient was observed as in patient for one week after surgery and was followed up for six months as outpatient with complete recovery.

### Introduction

Laryngomalacia is the most common congenital abnormality of the larynx, accounting for about 60 to 75 percent of congenital stridor cases<sup>[1-3]</sup>. Although its pathogenesis is not fully understood, in this condition there is collapse of supraglottic tissues during inspiration<sup>[4,5]</sup>, generating a high-frequency inspiratory stridor that is exacerbated in the supine position during feeding, agitation and crying<sup>[6-8]</sup>. This stridor usually appears in the first

two weeks of life, with an incidence peak at around 6 months and spontaneous resolution in 90 percent of the cases by the second year of life<sup>[9,10]</sup>. The severity of laryngomalacia can be mild, moderate, or severe<sup>[11]</sup>. Most cases are mild, and present with inspiratory stridor with a coordinated suck-swallow-breathe sequence; such cases do not require therapeutic intervention. Mild laryngomalacia resolves spontaneously within 1-2 years in 70 percent of patients<sup>[7]</sup>. The definition of

severe laryngomalacia is based on the following clinical criteria: apnea, cyanosis, respiratory failure, cor pulmonale, feeding difficulties, low weight and height development, and uncontrollable reflux – which are severity indicators, being criteria for surgical intervention<sup>[10,12,13,14]</sup>. Despite its benign and self-limited nature, 10 percent of laryngomalacia cases require intervention to relieve the respiratory obstruction<sup>[10,15]</sup>.

Surgical management of laryngomalacia is indicated only in severe cases, and aryepiglottoplasty is the surgical treatment of choice<sup>[16]</sup>.

### Case Report

A 12 year old male child was admitted in respiratory intensive care unit for severe respiratory distress. To start with there was history of cough and cold and difficulty in breathing. There was history of noisy breathing and recurrent upper respiratory tract infections since the age of 3 years which were insidious in onset, waxing and waning in nature, aggravated during playing and exertion and seasonal change with no specific relieving factors. These episodes of noisy breathing and recurrent upper respiratory tract infections were gradually progressive till the age of 12 years when the child was eventually brought to the hospital and was admitted for evaluation of inspiratory stridor.

On examination the child had difficulty in breathing with intercostal retractions. There was severe tachypnoea [respiratory rate 60/min] and tachycardia [heart rate 143/min] and bilateral inspiratory stridor and expiratory wheeze. The patient was planned for fiberoptic bronchoscopic evaluation however he developed acute respiratory distress and was intubated. Septic workup was done with chest x ray and arterial blood gas analysis [ph/pCo<sub>2</sub>/po<sub>2</sub>/hco<sub>3</sub> 7.304/49.6/95.1/23.9]. CECT chest showed left lower lobe consolidation with right paratracheal lymph node with caseation [?Tuberculosis]. Intravenous antibiotics were started.

There was no history of any trauma, foreign body ingestion, asthma or mechanical ventilation. Extubation trial was given after a few days and a fiberoptic bronchoscopic examination was done which showed:

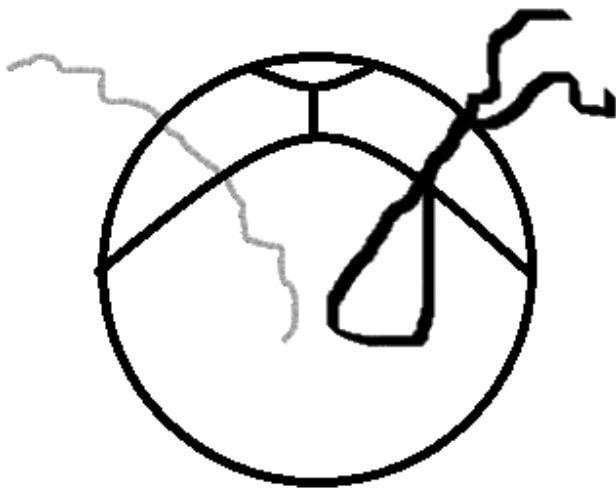
1. Elongated epiglottis with paradoxical movements during inspiratory effort
2. Short aryepiglottic folds [rt>lt]

However the child landed in respiratory distress with stridor in few hours and had to be reintubated. There were six failed attempts at extubation following which decision was made for surgical intervention in the form of aryepiglottoplasty.

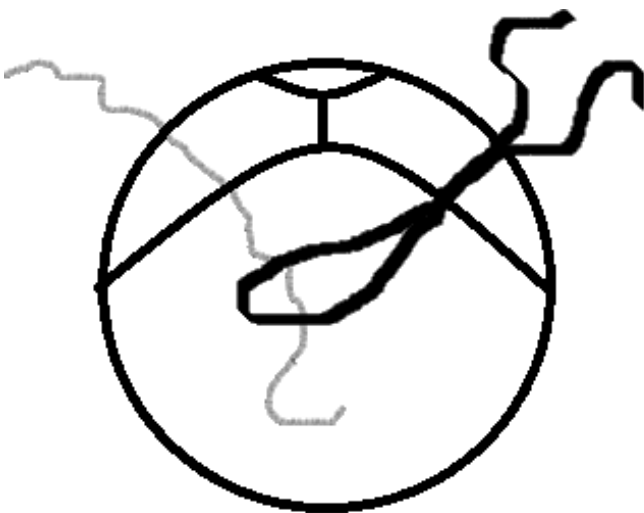
Initially awake fiberoptic laryngoscopic examination was carried out after proper consent from parents followed by examination under sedation to detect any sleep-related or sleep-exacerbated diseases. Deeper general anaesthesia was then ensured by intravenous anaesthetics and anaesthetic gases and microlaryngoscopy and bronchoscopy performed. It showed long epiglottis falling on laryngeal inlet with short aryepiglottic folds. There was no other abnormality in the air passage like vocal cord paralysis, laryngeal web or interarytenoid cleft.

The patient was taken up for aryepiglottoplasty via cold steel method. The short aryepiglottic folds were divided at a point approximately midway between the arytenoids and the aryepiglottic folds both sides. Following the dissection, the epiglottis was found to immediately spring forward leaving the laryngeal inlet more visible and open. However the epiglottis was still found falling on the laryngeal inlet. The lingual surface of epiglottis and the base of tongue were made raw using monopolar cautery. A novel suture technique was used for epiglottopexy wherein sutures were passed through the epiglottis from the surface of neck first in the midline and were eventually tied outside at the neck surface thus approximating the epiglottis with the base of tongue. This was carried out by using an 18 gauge LP needle. The LP needle was first passed and a looped 2-0

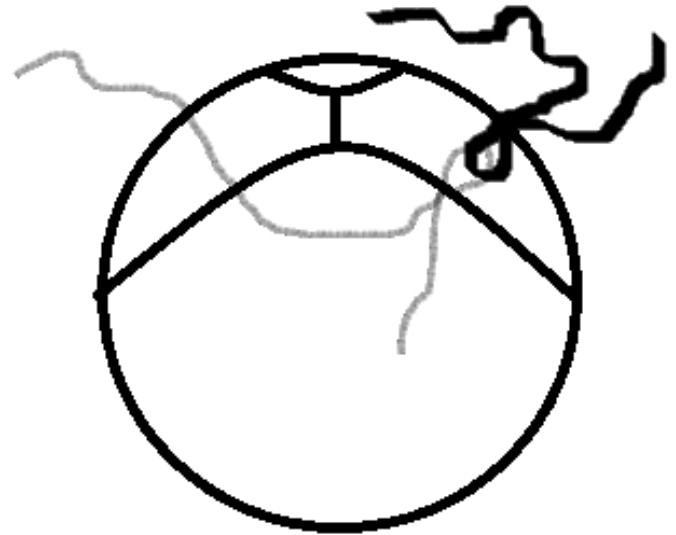proline was passed into it and pulled out from mouth. The LP needle was again passed and a single thread was passed and pulled out from mouth (fig.1). The single thread was then passed into the loop (fig.2) and the looped thread withdrawn from neck (fig.3) pulling the single thread out with it. This thread was tied on the neck pulling epiglottis anteriorly (fig.4). This is a simple technique with no intralaryngeal manipulation. This novel and simple technique has been designed and described previously by the senior author for vocal cord lateralisation as technique 2<sup>[17]</sup>.



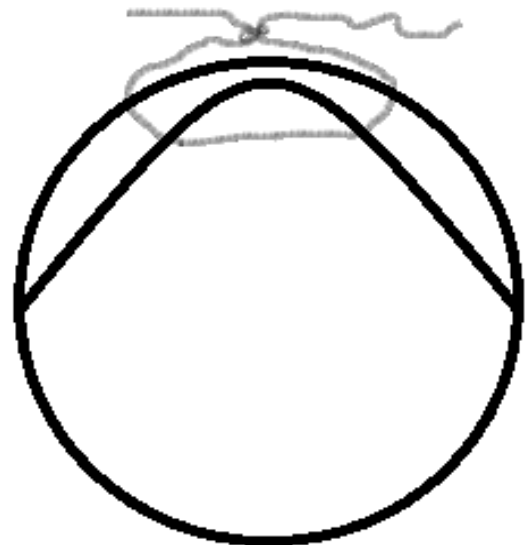
**Figure I:** Looped thread was passed from one side n single thread from another side.



**Figure II:** Single thread was passed into the loop.



**Figure III:** Looped thread was pulled out from neck along with single thread.



**Figure IV:** Single thread was tied to the neck.

The child was extubated on the fourth post operative day. He was comfortable with no respiratory distress and chest indrawing. Nasogastric tube was removed on the eighth post operative day and oral feeds were started. He tolerated the oral feeds well without aspiration. Epiglottis was positioned properly after removal of holding suture 6 months later, without obstructing airway. After discharge at three weeks, now it is more than 1.5 years follow up the child is doing fine with no further episodes of respiratory distress and stridor or aspiration.

## Discussion

Laryngomalacia has become a ubiquitous term to describe a floppy appearing larynx despite the age of the patient. However, when identified in older patients, the symptom complex is often different from that of patients with congenital disease.

Adult onset laryngomalacia is an entity which needs a high degree of suspicion. Children can present with any of the following features:

1. Persistent coughing and choking during feeding, weight loss and failure to thrive
2. Sleep disordered breathing and symptoms consistent with OSA which included respiratory pauses, gasping, restless sleep, suprasternal and subcostal retractions.
3. Symptoms of inspiratory stridor, shortness of breath and retractions with strenuous activity.

The diagnosis is based on flexible laryngoscopy to confirm laryngomalacia and exclude other causes of supraglottic obstruction. In the present case also flexible laryngoscopy was used to confirm the diagnosis of laryngomalacia.

In view of the clinical picture of endoscopic finding of short aryepiglottic fold with long epiglottis and multiple failed attempts of extubation surgery was planned in the present case.

Hey et al reported adult onset laryngomalacia in 2 patients<sup>[18]</sup>, Hyodo et al reported adult onset laryngomalacia in a 20 year old female<sup>[19]</sup> and in this study we report the same in 12 year old male patient. Richter et al also reported a series of late onset laryngomalacia where 17 patients were diagnosed as having laryngomalacia when they were older than 2 years (mean age at onset 6.6 years)<sup>[20]</sup>.

A similar case was reported wherein the patient presented with laryngomalacia at the age of 10 years with features of respiratory distress and stridor and underwent supraglottoplasty.<sup>[21]</sup>

In a study related to late onset laryngomalacia as a cause of pediatric obstructive sleep apnoea seventy-seven children were identified who had OSAS and underwent airway endoscopy to

evaluate laryngomalacia. Seven children under 3 years of age had laryngomalacia and OSAS, 19 children 3-18 years of age had laryngomalacia and OSAS, and 51 children 3-18 years of age had OSAS but not laryngomalacia. Treatments were individualized to include supraglottoplasty, adenoidectomy, tonsillectomy, adenotonsillectomy, or a combination of the above<sup>[22]</sup>.

The most consistent structural abnormality is the short aryepiglottic fold. It is believed that the short aryepiglottic folds are responsible for tethering the epiglottis posteriorly. Incision of the folds midway along its length serves to release the epiglottis and allows it to move forward. Hasslinger, in 1928, is credited with the first description of such a procedure<sup>[23]</sup>. In the present case apart from incising the aryepiglottic fold we used a novel suture technique in which sutures were passed from neck through the base tongue and epiglottis and the epiglottis was thereby approximated with the base of tongue.

For the fear of local tissue oedema consequent to both anaesthesia and the surgical procedure we kept the child intubated for three days. The result was extremely gratifying on short and long term follow-up. The major benefit has been the avoidance of the potential morbidity and mortality associated with repeated intubations.

## Conclusion

Laryngomalacia is the most common laryngeal anomaly which causes inspiratory stridor in newborns. However late onset laryngomalacia should also be considered as a differential diagnosis in older children with respiratory distress. Laryngomalacia is usually a self-limiting condition and usually resolves by two years of age however about 10 percent cases require surgical intervention which currently in the form of supraglottoplasty is considered as the standard treatment for severe laryngomalacia.

## Acknowledgement

The authors wish to acknowledge Dr Riddhi Tatwadiya for her advice on this manuscript.

**Funding**

This research did not receive any specific grant from funding agencies in the public, commercial, or not-for-profit sectors.

Each of the authors has contributed, read and approved this manuscript.

None of the authors has any conflict of interest, financial or otherwise.

This manuscript is original and it, or any part of it, has not been previously published; nor is it under consideration for publication elsewhere.

**References**

1. Valera FC, Tamashiro E, de Araujo MM, Sander HH, Kupper DS. Evaluation of the efficacy of supraglottoplasty in obstructive sleep apnea syndrome associated with severe laryngomalacia. *Arch Otolaryngol Head Neck Surg* 2006 May;132(5):489-93.
2. Lee KS, Chen BN, Yang CC, Chen YC. CO<sub>2</sub> laser supraglottoplasty for severe laryngomalacia: a study of symptomatic improvement. *Int J Pediatr Otorhinolaryngol*. 2007 Jun;71(6):889-95.
3. Bluestone CD, Healy GB, Cotton RT. Diagnosis of laryngomalacia is not enough! *Arch Otolaryngol Head Neck Surg*. 1996 Dec;122(12):1417-8.
4. Day KE, Discolo CM, Meier JD, Wolf BJ, Halstead LA, White DR. Risk factors for supraglottoplasty failure. *Otolaryngol Head Neck Surg*. 2012 Feb;146(2):298-301.
5. Denoyelle F, Mondain M, Gresillon N, Roger G, Chaudre F, Garabedian EN. Failures and complications of supraglottoplasty in children. *Arch Otolaryngol Head Neck Surg*. 2003 Oct;129(10):1077-80.
6. Werner JA, Lippert BM, Dunne AA, Ankermann T, Folz BJ, Seyberth H. Epiglottopexy for the treatment of severe laryngomalacia. *Eur Arch Otorhinolaryngol*. 2002 Oct;259(9):459-64.
7. Richter GT, Thompson DM. The surgical management of laryngomalacia. *Otolaryngol Clin North Am* 2008 Oct; 41(5): 837-864, vii.
8. Gandhi S, Oswal V, Thekedar P, Mishra P. Role of transoral CO<sub>2</sub> laser surgery for severe pediatric laryngomalacia. *Eur Arch Otorhinolaryngol*. 2011 Oct; 268(10): 1479-83.
9. Senders CW, Navarrete EG. Laser supraglottoplasty for laryngomalacia: are specific anatomical defects more influential than associated anomalies on outcome? *Int J Pediatr Otorhinolaryngol*. 2001 Mar; 57(3):235-44.
10. Zafereo ME, Taylor RJ, Pereira KD. Supraglottoplasty for laryngomalacia with obstructive sleep apnea. *Laryngoscope*. 2008 Oct;118(10):1873-7.
11. Thompson DM. Abnormal sensorimotor integrative function of the larynx in congenital laryngomalacia: a new theory to etiology. *Laryngoscope*. 2007 Jun;117(6 Pt 2 Suppl 114):1-33.
12. Fraga JC, Schopf L, Volker V, Canani S. Endoscopic supraglottoplasty in children with severe laryngomalacia with and without neurological impairment. *J Pediatr (Rio J)*. 2001 Sep-Oct;77(5):420-4.
13. Schroeder JW Jr, Bhandarkar ND, Holinger LD. Synchronous airway lesions and outcomes in infants with severe laryngomalacia requiring supraglottoplasty. *Arch Otolaryngol Head Neck Surg*. 2009 Jul;135(7):647-51.
14. Chan DK, Truong MT, Koltai PJ. Supraglottoplasty for occult laryngomalacia to improve obstructive sleep apnea syndrome. *Arch Otolaryngol Head Neck Surg*. 2012 Jan;138(1):50-4.
15. Toynton SC, Saunders MW, Bailey CM. Aryepiglottoplasty for laryngomalacia: 100 consecutive cases. *J Laryngol Otol*. 2001 Jan;115(1):35-8.

16. Martin JE, Howarth KE, Khodaei I, Karkanevatos A, Clarke RW. Aryepiglottoplasty for laryngomalacia: the Alder Hey experience. *J Laryngol Otol* 2005 Dec;119(12):958-960.
17. Mathur NN, Kumar S, Bothra, R. Simple method of vocal cord lateralization in bilateral abductor cord paralysis in pediatric patients. *Int J Pediatr Otorhinolaryngol*. 2004 Jan;68(1):15–20.
18. Hey SY, Oozeer NB, Robertson S, MacKenzie K. Adult-onset laryngomalacia: case reports and review of management. *Eur Arch Otorhinolaryngol*. 2014 Dec;271(12):3127-32.
19. Hyodo M, Nishikubo K, Ito H, A case of adult-onset arytenoid type laryngomalacia successfully treated with a resection of flaccid arytenoid mucosa. *Koutou (The Larynx Japan)* vol.24(2012) No. 2p. 128-130.
20. Richter GT, Rutter MJ, deAlarcon A, Orvidas LJ, Thompson DM. Late-onset laryngomalacia: a variant of disease. *Arch Otolaryngol Head Neck Surg*. 2008 Jan;134(1):75-80.
21. Awan S, Saleheen D, Ahmed Z. Laryngomalacia: an atypical case and review of literature. *Ear Nose Throat J*. 2004 May;83(5):334,336-8.
22. Revell SM, Clark WD. Late-onset laryngomalacia: a cause of pediatric obstructive sleep apnea. *Int J Pediatr Otorhinolaryngol*. 2011 Feb;75(2):231-8.
23. Zoumalan R, Maddalozzo J, Holinger LD. Etiology of stridor in infants. *Ann Otol Rhinol Laryngol*. 2007 May;116(5):329-34.